Dubai Derma®

Skin Health is our Concern

23rd Dubai World Dermatology and Laser Conference & Exhibition

Shaping the Future of Dermatology & Aesthetics

5 – 7 March 2024

Dubai World Trade Centre

CONFERENCE PROGRAM

Supported by

Pan Arab League of Dermatology

ARAB ACADEMY OF DERMATOLOGY & AESTHETICS

Strategic Partner

الهيئة الاتحادية للهوية والجنسية

FEDERAL AUTHORITY FOR IDENTITY & CITIZENSHIP

Organized by

إندكس للمؤتمرات والمعارض

INDEX CONFERENCES & EXHIBITIONS

His Highness Sheikh Mohamed bin Zayed Al Nahyan

President of the United Arab Emirates

His Highness Sheikh Mohammed bin Rashid Al Maktoum

Vice President and Prime Minister of the UAE and Ruler of Dubai

TABLE OF CONTENT

Message from the Conference Chairman

Prof. Ibrahim Galadari
Secretary-General of GCC League of Dermatology, Secretary-General of Arab Academy of Dermatology & Aesthetics, President of Arab Board and Chairman of the Dubai Derma Conference

It is with great pleasure that I extend a heartfelt welcome to all attendees to the 23rd Dubai World Dermatology & Laser Conference & Exhibition, set to be held from March 5th to March 7th, 2024, at the prestigious Dubai World Trade Centre (DWTC).

In the realm of dermatology, Dubai has continuously embraced cutting-edge technologies to address the evolving needs and expectations of our community while simultaneously aspiring to establish itself as a global leader in the events and entertainment industry. This commitment is exemplified through the hosting of pioneering mega-events in the region.

Dubai Derma is proudly organized by esteemed scientific institutions, notably the Arab Academy of Dermatology and Aesthetics (AADA), in collaboration with the GCC League of Dermatology and the Pan-Arab League. As a distinguished member of the International League of Dermatology Society (ILDS), AADA ensures that our scientific program is accredited by these esteemed organizations.

Dubai Derma assembles distinguished speakers from across the globe, offering insights into a diverse range of topics shaping the field of dermatology. Our comprehensive scientific program encompasses a four-day pre-conference course, conference sessions, workshops, and live demonstrations, spotlighting innovative cosmetic and dermatological procedures.

This conference serves as a dynamic platform for dermatology professionals worldwide to enrich their knowledge, explore groundbreaking advancements in dermatology and technology, and cultivate meaningful connections.

I eagerly anticipate greeting all of you at the upcoming Dubai Derma edition!

Message from the Executive Chairman

H.E. Amb. Dr. Abdulsalam AlMadanii
Executive Chairman of Dubai Derma

It is my pleasure to welcome you to the 23rd edition of the Dubai World Dermatology and Laser Conference and Exhibition – Dubai Derma 2024! The leading gathering in the Middle East, North Africa, and the Indian Subcontinent, focusing on dermatology, skincare, and laser technologies.

This event celebrates innovation and expertise, allowing you to explore the expansive 25,146 sqm exhibition area dedicated to shaping the future of aesthetics and skincare. There's much to discover, with over 400 exhibitors showcasing 1,500 international aesthetic, anti-aging, and skincare brands and laser technologies.

Dubai Derma boasts a program featuring 301 speakers, including specialists, industry experts, and skincare physicians from 112 countries, all eager to share their knowledge and the latest developments in medical technology and skincare treatment across 51 sessions and 334 lectures. Attendees can actively participate in discussions, attend insightful courses, and join enlightening lectures tailored to meet the evolving needs of patients.

Your active participation in scientific sessions and practical learning contributes to the advancement of the profession and allows you to gain valuable insights into the latest developments in skincare science and anti-aging breakthroughs. Explore a wealth of resources, including 69 case studies, 30 professional poster presentations, and insights from 16 participating scientific international affiliations. Engage in 11 industry partner sessions, 53 workshops (including 32 practical workshops), and 13 live clinical sessions designed to deepen your understanding and inform you about industry trends and advancements.

We express our sincere thanks to our partners, esteemed dermatology associations, generous sponsors, distinguished exhibitors, and prominent health authorities for their unwavering support. Your presence enhances this gathering, and we appreciate your invaluable contributions to the event.

Looking forward to welcoming you at Dubai Derma 2024, held from March 5 to 7, 2024, at the prestigious Dubai World Trade Center (DWTC).

H.E. Amb. Dr. Abdulsalam AlMadani
Executive Chairman of Dubai Derma

Speech from the AADA President

Abdul Wahab Al Fouzan MD
Senior Consultant of Dermatology & Venereology
President of Arab Academy of Dermatology and Aesthetics
President of Scientific Council of Dermatology & Venereology in the Arab Board of Medical Specialization

Prof. Ibrahim Galadari, Secretary-General of GCC League of Dermatology, Secretary-General of Arab Academy of Dermatology & Aesthetics, President of Arab Board and Chairman of the Dubai Derma Conference

His Excellency Ambassador Dr. Abdulsalam AlMadani, PAM Roving Ambassador for the GCC Region, Executive Chairman of Dubai Derma

Ladies and Gentlemen,

We gather today for the 23rd edition of the Dubai World Dermatology and Laser Conference and Exhibition - Dubai Derma 2024.

Before proceeding further, I want to express our sincere appreciation on behalf of all attendees. Our heartfelt thanks go to the Dubai Health Authority for their generous support of this conference. Their commitment to promoting human health and fostering the endeavors of medical professionals, researchers, and scientists is commendable. Their support plays a pivotal role in advancing healthcare services, contributing significantly to the enhancement and progress of the medical field.

This well-known annual medical conference, centered on dermatology, skin surgery, and laser treatments and hosted in Dubai, unites an esteemed assembly of consultant doctors and specialists. Participants come from the Gulf Cooperation Council countries and Arab nations as well as from the continents of America, Europe, and Asia.
Incorporating four lecture halls within a single conference is a notable scientific accomplishment, offering doctors at all levels, including trainees, specialists, and consultants, the opportunity to engage, attend, and gather insights from these enriching lectures.
Let us not overlook the significance of the pre-conference workshops and training sessions. These sessions are intensive courses covering various dermatology specialties such as pathology, skin plastic surgery, and laser treatments.

Upon reviewing the conference's scientific program, many papers and research contributions emerge. The focus is on the latest advancements in laser treatment, particularly within skin surgery and the management of conditions like psoriasis, acne, and bullous diseases, as well as the treatment of aging symptoms, skin tumors, cancerous skin, and skin allergies. Additionally, attention is given to treating pigmentation, hair loss, alopecia, hereditary skin diseases, and infectious skin diseases.

The conference activities encompass a substantial number of workshops addressing the applications of lasers and strategies for addressing skin changes resulting from aging. The training courses explore specialized topics related to skin allergies, acne, pigmentation, hair loss, genetic diseases, histology, skin surgeries, and psoriasis.

It is indisputable that both the workshops and training courses offer considerable benefits, meeting the scientific and practical needs of the participating doctors.

The dedication of senior authorities in Dubai to healthcare, as witnessed through the consistent organization of conferences and seminars, has transformed it into a cultural cornerstone and an esteemed platform for all. Observed

today, the Dubai World Dermatology and Laser Conference and Exhibition, in its 23rd year, is a moment of great honor for all Arab countries.

Despite the ease of disseminating medical and therapeutic information through modern electronic channels, the significance of medical conferences remains paramount. These conferences play a crucial role in bringing together doctors, fostering closeness, and facilitating the exchange of diverse perspectives on the latest developments in our field.
This conference holds immense value for medical professionals, including recent graduates, postgraduate students, specialists, and consultants. The event encompasses training and educational programs that prove beneficial in both academic and practical aspects, aiding participants in their professional journey and preparing them for periodic exams. It also allows them to earn continuing medical education points (CME).

On behalf of both myself and the Arab Academy of Dermatology and Cosmetic Medicine, I extend a warm welcome to Dubai Derma 2024. The Academy actively engages in numerous scientific initiatives, including collaboration and participation in organizing conferences such as Dubai Derma and Sharm Derma. Its scientific endeavors extend beyond borders, encompassing the development of training courses across many Arab countries. We take pride in recognizing the Arab Academy of Dermatology and Cosmetic Medicine as a distinguished entity, holding four seats in the International League of Dermatological Societies.

In conclusion, on behalf of all attendees, I congratulate Dr. Ibrahim Galadari, Chairman of the Dubai Derma Conference, and the organizing committees for their outstanding efforts and for creating a remarkable scientific program.

A Special acknowledgment is also due to His Excellency Ambassador Dr. Abdulsalam AlMadani, PAM Roving Ambassador for the GCC Region, Executive Chairman of Dubai Derma and Chairman of INDEX Holding, and his dedicated team for their excellent organization and significant contributions to this event.
Likewise, I congratulate Dr. Hassan Galadari, Associate Professor at the College of Medicine, UAE University, Head of Scientific Committee, Dubai Derma, Secretary General of the International Society of Dermatology, and the President of the Asian Dermatology Association. His influential role in shaping this conference's scientific and practical aspects is noteworthy.
Wishing you all fruitful outcomes, success and ongoing achievements.

Thank you,

Message from the Secretary General

Reyad Mash'al MD
Secretary General of PAN Arab League of Dermatological Societies

Prof. Ibrahim Galadari, Secretary-General of GCC League of Dermatology, Secretary-General of Arab Academy of Dermatology & Aesthetics, President of Arab Board and Chairman of the Dubai Derma Conference

His Excellency Ambassador Dr. Abdulsalam AlMadani, PAM Roving Ambassador for the GCC Region, Executive Chairman of Dubai Derma, and Chairman of INDEX Holding,

Dr. Abdul Wahab Al Fouzan, President of the Arab Academy of Dermatology & Aesthetics,

Dr. Hassan Galadari, Head of Scientific Committee, Dubai Derma, Chairman of the Asian Dermatology Association,

Ladies and Gentlemen,
Esteemed Guests,

The inauguration of the twenty-fourth edition of Dubai World Dermatology and Laser Conference and Exhibition (Dubai Derma 2024) is not merely a ceremonial observance of a typical conference. Today's inauguration of Dubai Derma commemorates a long and fruitful journey spanning years and decades of aspiration, perseverance, and accomplishment. Dubai Derma has become the leading medical conference in the Middle East, North Africa, and the Indian subcontinent, with the motto of shaping the future of dermatology and beauty.

The Dubai Derma Conference and Exhibition is a significant annual event for dermatologists from around the world to stay updated on the latest developments in diagnosing and treating skin diseases, as well as advancements in skincare and laser technologies. More than 350 lecturers from over 100 countries participate in this three-day conference held in three parallel venues, providing a platform for exchanging insights.

The conference has designated a hall for displaying clinical cases and awarding recognition for exceptional cases and research. The scientific and pharmaceutical exhibition is a significant event focusing on laser and skincare technology, with approximately 400 companies from 120 countries. More than 25,000 attendees are expected to attend the event this year.

Dubai Derma has also attracted the attention of several worldwide and regional associations to host special sessions in the conference's scientific agenda. We are pleased with this achievement, demonstrating Dubai Derma's prestigious scientific standing and motivating these organizations to participate in the event's scientific program each year. These associations include the International Society of Dermatologists, SIDEMAST, Iraqi Society of Dermatologists & Venerologists, Sham Derma, and many more.

The success story of this event is mainly attributed to Dr. Ibrahim Galadari, a pioneering figure in dermatology in the Gulf countries and the United Arab Emirates, who is the driving force behind this achievement.

On behalf of the Pan Arab League of Dermatology, I would like to thank the Government of Dubai, under the wise leadership of His Highness Sheikh Mohammed bin Rashid Al Maktoum, Vice President and Prime Minister of the UAE and Ruler of Dubai, for supporting health services and medical events in Dubai. Dubai has evolved into a hub of culture and science, establishing itself as a distinguished destination for everyone.

We admire Dubai, Dr. Ibrahim, and Dr. Hassan Galadari for nominating Dubai to host the twenty-seventh conference of the International League of Dermatological Societies, **ILDS 27 Congress – Dubai 2031.** We look forward to collaborating closely to accomplish this significant milestone for Dubai and the Middle East region.

Once again, allow me to extend my heartfelt congratulations to my esteemed colleagues, Dr. Ibrahim Galadari, His Excellency Ambassador Dr. Abdulsalam AlMadani, and Dr. Hassan Galadari, for their continued successes, and express gratitude for their invaluable efforts in organizing this esteemed event with its distinguished scientific program.

May all participants experience a delightful visit to Dubai, the City of Dreams and the symbol of the future.

Thank you.

Scientific **Committee**

Ibrahim Galadari, MD
Professor of Dermatology,
Chairman, Dubai Derma Conference

Hassan Galadari, MD
Head of Scientific Committee,
Dubai Derma

MEMBERS

Abdul Wahab Al Fouzan, MD
Kuwait

Abdullah Al Eisa, MD
KSA

Ahmed Al Waily, MD
Oman

Ahmed Al Dhaheri, MD
United Arab Emirates

Ahmed Al Qahtani, MD
United Arab Emirates

Ali Singel, MD
United Arab Emirates

Alia Al Mualla, MD
United Arab Emirates

Amani Abdulla Alfalasi, MD
United Arab Emirates

Ameen Alawadhi, MD
Bahrain

Andre Mattos, MD
Brazil

Assem Farag, MD
Egypt

Ayman AlNaeem, MD
United Arab Emirates

Dhaifallah Alghowairi, MD
KSA

Fahad Al Ajmi, MD
KSA

Fatima Al Breiki, MD
United Arab Emirates

Minal Patwardhan, MD
United Arab Emirates

MEMBERS

Muna Almurrawi, MD
United Arab Emirates

Nawaf Al-Mutairi, MD
Kuwait

Qassim Ahli, MD
United Arab Emirates

Riad Mashal, MD
Palestine

Salah Al Rubaie, MD
United Arab Emirates

Shaden Abdelhadi, MD
United Arab Emirates

Simil Ahari, MD
United Arab Emirates

Yusra Al Ali, MD
United Arab Emirates

Zbigniew Ruszczak, MD
United Arab Emirates

Organising **Committee**

His Excellency Amb. Dr. Abdulsalam AlMadani
Executive Chairman of Dubai Derma,
Chairman of INDEX Holding

Eng. Anas AlMadani
Vice Chairman & Group CEO
INDEX Holding

Dr. Matios Tcholakian
Senior Business Development Manager
INDEX Conferences & Exhibitions

Andrea Barretto
Senior Project Manager – Head of Cluster
INDEX Conferences & Exhibitions
(a member of INDEX Holding)

Vaneza Liaguno
Senior Project Manager
INDEX Conferences & Exhibitions
(a member of INDEX Holding)

Bhagya Wijethunga
Event Coordinator
INDEX Conferences & Exhibitions
(a member of INDEX Holding)

Accreditation

23rd Edition of Dubai World Dermatology and Laser Conference
Dubai Derma 2024

Has been awarded by the following CME Accreditation

UAEU
جامعة الإمارات العربية المتحدة
United Arab Emirates University

Faculty of Medicine and Health Sciences
United Arab Emirates University

Accreditation Number: **202312-4**

Total CME Credit Hours: 18

(Based on Attendance)

Dear Participant,

Dubai Derma will continue its endeavor to provide quality Continuing Medical Education programs through hosting high caliber lectures and partnering with prestigious scientific organisation such as Faculty of Medicine and Health Sciences, United Arab Emirates University.

Dubai Derma aims to raise the profile of the conference by providing a new automated delegate registration system, which helps in calculating the credit hours earned during your participation at the conference.

How does the system work?

- Every time you enter or exit the conference hall, you will be required to scan your badge at the gateway located at the entrance of the conference hall. Failure to scanning your badge will result in non-calculation of the credit hours.
- The System will automatically calculate the time spent during the session based on your entry and exit

How much time do I need to spend during a session?

- To earn the credit hours, you will need to attend a minimum of 80% of the conference sessions. 23rd Dubai World Dermatology & Laser Conference has been awarded by the following CME Accreditation Faculty of Medicine and Health Sciences United Arab Emirates University

Accreditation Number: **202312-4**
Total CME Credit Hours: **18**
(Based on Attendance)
Accreditation

When can I collect my Certificate of Attendance?

- Certificate of Attendance will be given on the last day of the event, Visit Dubai Derma website (dubaiderma.com) and click on the download certificate button for collection of the certificate.

When can I collect my Continuing Medical Education certificate?

- For the Continuing Medical Education Certificate, the system will calculate the total number of credit hours you earned based on your overall attendance at the conference.
- The Certificate can be viewed and printed anytime starting from 12 March 2024.

How can I collect my Continuing Education certificate?

- Visit Dubai Derma website (dubaiderma.com) and click on the Accreditation button for collection of the certificate. This service will be available from 12 March 2024 and step by step instructions can be found on the website.

How much credit hours will I earn?

- Dubai Derma Conference offers continuing medical education program, the maximum credit hours a participant can earn by attending all the sessions are 18 CME Credit Hours Awarded by Faculty of Medicine and Health Sciences, United Arab Emirates University.

Why an Automated Registration System?

- The system will give an accurate count of the credits earned without human error.
- The system will give further credibility to the conference and the Accreditation bodies.
- The system provides a fair system for recording the right number of credits earned.

Frequently Asked Questions

Q: Do I need to scan my badge every time I enter the conference hall?

A: Yes, you will be required to scan your badge when you enter and exit the hall. This will allow the system to calculate the designated hours.

Q: If I need to attend to a phone call, what do I do?

A: You will need to scan your badge when you exit and scan it again when you enter. If you need to attend to a phone call or any emergencies, please keep an eye on the time as you will need to spend a minimum of 80% of the time you spend at the session.

Q: What do I do in case I need to verify my attendance?

A: Kindly call +971 520 8888 or email us at registration@dubaiderma.com

CME Credit Hours calculated based on attendance
CME Credit Hours can be only obtained through **dubaiderma.com** from **12 March 2024**

Conference **Speakers**

Aasem Albytu MD
Head of Plastic and Reconstructive surgery

Abdul Hameed MD
Medical Director, Consultant

Abdullah Al Eisa MD
Consultant Dermatologist and Medical Director

Abeer Elkholy MD
Professor of Dermatology

Achraf Ellouadghiri MD
Founder, Consultant and an Educator

Adel Alsantali MD
Consultant Dermatologist, Head of Dermatology Department

Afsheen Bilal MD
Professor of Dermatology, Oncology and Director of the Unit

Ahmad Nazari MD
Aesthetic Trainer

Ahmed Al Waily MD
Senior Consultant Dermatologist

Ahmed Alqahtani MD
Assistant Professor

Ahmed Abdul-Aziz Ahmed MD
Consultant Dermatologist & Assistant Professor

Ahmed Sami Abouroab MD
Specialist Dermatologist

Alaa Eldin Moubasher MD
Professor of Dermatology, Venereology and Andrology

Ali Fadhil Al-Saadi
Professor and Consultant Dermatologist

Alina Abbass MD
Senior Registrar

Amal Wagih MD
Specialist of Dermatology

Amany Nassar MD
Professor and Head of the Dermatology department

Ameen Alawadhi MD
Consultant Dermatologist and Dermatopathologist, Head of Dermatology and Chairperson of Internal Medicine Department

Amera Elsayed Bayumi MD
Aesthetic Dermatology specialist

Amin Sharobim MD
Lecturer of Dermatology

Conference **Speakers**

Andre Mattos MD
Plastic Surgeon

Anna Maria Fenech Magrin MD
Clinical Senior Lecturer and Deputy Course Co-ordinator

Annunziata Dattola MD
Researcher at The Department of Dermatology University of Rome Tor Vergata, Italy

Antoine Pichery
CEO

Antonino Araco MD
Specialist in Plastic Surgery

Anupa Job MD
Assistant Professor

April Armstrong MD
Professor and Chief of Dermatology

Arturo Almeida MD
Medical Director & Global Trainer

Ashba Nasir Cheema MD
Consultant Dermatologist

Ashish Chauhan MD
Founder, Director & Consultant

Ashraf Hamza MD
Professor of Dermatology and Venereology

Ashraf Reda MD
Consultant Dermatologist

Asma Tariq MD
Senior Registrar

Assem Farag MD
Professor of Dermatology

Ayesha Abrar MD
Resident Dermatology

Ayoud TOUMI MD
Plastic Surgeon

Brigitte Dreno MD
Professor of Dermatology, Chairman of the Department of Dermato-Oncology and Director of the GMP Unit

Burcu Yamangöktürk Solak MD
Consultant Dermatologist and Dermatologist, General Secretary and Founding Member

Byongseong Cho MD
CEO and CTO

Chytra Anand MD
Chief Consultant Cosmetic Dermatologist

Conference **Speakers**

Da Yeong Nam
Senior Research Engineer

Dalia Ata MD
Dermatologist & cosmatologist

Dalia Shaaban MD
Professor of Dermatology and Venereology

Darrell S. Rigel MD
Dermatologist and Clinical Professor of Dermatology

David Pudukadan MD
Professor

David J. Goldberg MD
Director of Cosmetic Dermatology

Diah Puspitosari MD
Medical consultant, Member of the research team and Dermatologist practitioner

Diala Alshiyab MD
Associate Professor and Consultant Dermatologist

Diala Haykal MD
Cosmetic and Laser Doctor

Diana Sarkis MD
Resident Dermatologist

Dina Sidani
Founder and CEO

Dindar Sharif Qurtas MD
Dermatologist, Assistant Professor

Do-Young Rhee MD
Director

Dominique du Crest
Co-founder Skin & Digital Summit

Dooha Alhamdi MD
Assistant Professor of Dermatology

Dora Evangelidou MD
Consultant Plastic and Reconstructive Surgeon

Duaa Abdulmohsen Mohamed MD
Specialist Dermatologist

Dulini Liyanagama MD
Consultant Dermatologist

Dyala Lutfi Sayed Ahmad MD
Dermatology Resident

Eggert Stockfleth MD
Professor of Dermatology & Head of Skin Cancer Center

Conference **Speakers**

Elena Belisheva MD
Dermatologist & CEO

Elena Zappia MD
Medical Doctor

Elina Theodorakopoulou MD
Specialist in Dermatology

Ersan ÖN MD
Dermatologist, Treasurer General

Esraa Elhawary MD
Lecturer of Dermatology and Venereology

Evgeniya Shelemba MD
Dermatologist

Fadi Hamadani MD
Professor of Plastic Surgery, Division Chief, Plastic & Reconstructive Surgery

Faiez Ghanam MD
Dermatologist

Fareheen Ashfaq MD
Consultant Dermatologist

Fatema Khamdan MD
Assistant Professor, Consultant Dermatologist and Dermatopathologist

Federica Trovato MD
Dermatology Resident

Fida Anjum MD
Resident Dermatologist

Firas Al Qarqaz MD
Consultant Dermatologist

Fouad El Sayed MD
Professor and Head of Dermatology, Lebanese University

Fouz Hassan MD
Head of the Department of Dermatology and Venereology

Giovanni Pellacani MD
Chairman of Dermatology Department

Hadeel Maaddawi MD
Medical Intern

Haider Al-Sabak MD
Head of Dermatology and Laser Department

Hajar Almansoor MD
Medical Student

Hanno Pototschnig MD
Medical Doctor

Conference **Speakers**

Harb Al-Omari MD
Consultant Dermatology, Andrology & STDs

Hassan Galadari MD
Associated Professor of Dermatology

Hesham Zaher MD
Emeritus Professor of Dermatology

Hossein Yavari MD
Specialist Dermatologist

Huda H. Tahlawi MD
Dermatologist & Venereologist

Hussein Abdel Dayem MD
Consultant Dermatologist

Ibrahim El Achkar MD
ENT, Aesthetics and Plastic Surgeon

Ilaria Proietti MD
Dermatologist

Irada Huseynova MD
Plastic Surgeon

Isam Oumeish MD
Consultant Dermatology and Venereology and Laser

Izabela Zaleska MD
Specialist in Aesthetic, Medical and Therapeutic Cosmetology

Jacek C. Szepietowski MD
Chair of the Department of Dermatology, Venereology and Allergology

Jayakar Thomas MD
Emeritus Professor, Founder and National Chairman

Jesper Thulesen MD
Ophthalmologist and Oculoplastic surgeon

Jigna Patel MD
Aesthetic Clinician and Owner

Jose Luis López-Estebaranz MD
Professor of Dermatology

Julnar Hanna MD
Dermatologist

Jyotirmay Bharti MD
Consultant Dermatologist & Hair Transplant Surgeon

Kalsoom Jawaid MD
Assistant Professor

Karim Magdi Gabr MD
German Board-certified Dermatologist

Conference **Speakers**

Kehkshan Tahir MD
Associate Professor

Khaled Gharib MD
Professor of Dermatology and LASER

Khalifa Sharquie MD
Professor of Dermatology

Khalil Alhamdi MD
Professor of Dermatology and Consultant Dermatologist

Laurent BENADIBA MD
Plastic Surgeon

Leonard Nenad Josipovic MD
Aesthetic and Cosmetic Surgeon

Lina Al Soufi MD
Head of Department of Dermatology

Liudmila Soboleva MD
Dermatologist, Aesthetic Medicine Doctor

Mahdi Shamad MD
Associate Professor and Dean

Mahra Khaled Al Shehhi
Senior Medical Student

Manal Bosseila MD
Professor of Dermatology

Maria Rubatti MD
Head of Plastic Surgery Department

Maria Cristina Puyat MD
Dermatologist & Medical Director

Meelad Habib MD
Dermatologist

Michael H. Gold MD
Owner, Medical Director

Mohamad Essam Kayyali MD
Consultant of Plastic Surgery

Mohamed Khouazem MD
Specialist Dermatologist

Mohamed ElGhareeb ElGanainy MD
Assistant Professor of Dermatology

Mohammad A. Rashed MD
Dermatologist

Mohammed Al Abadie MD
Clinical Director & Consultant Dermatologist

Conference **Speakers**

Mohammed El Banhawy MD
Senior Consultant Dermatologist

Mohammed Elazab MD
Consultant Dermatologist & Chairman

Monira El Waseef MD
Fellowship trainer

Muhammad Rabie Katta MD
Vice President

Muhammad Yulianto Listiawan MD
Professor of Dermatology and Dermatovenereologist

Muhsin A. Al-Dhalimi MD
Professor of Dermatology and Head of the Department of Dermatology and Venereology

Nadia Abdelwadood MD
Consultant of Dermatology and Sexually Transmitted Infection

Nawaf Al Mutairi MD
Professor and Head of The Department

Nemat Alsaghir MD
Assistant Professor of Dermatology

Nermeen Bedair MD
Associate Professor of Dermatology

Nevine Dorgham MD
Professor of Dermatology

Nicola Zerbinati MD
Associate Professor of Dermatology and Venereology

Nisha Menon MD
Aesthetic Doctor

Nivvedhetha S. MD
Senior Resident

Noura Lebbar MD
Cosmetic Surgeon

Olga Orlova MD
Head of the Center

Omar F. Najjari MD
Paediatrician & Paed. Toxicologist

Paolo Bonan MD
Professor of Dermatology

Parimalam Kumar MD
Professor & Head of the Department of Dermatology

Patricia Froes Meyer MD
Physiotherapist

Conference **Speakers**

Philippe Hamida-Pisal MD
President of the Society of Mesotherapy of the United Kingdom

Raghda Al Maashari MD
Dermatology Consultant

Ramesh Bhat MD
Vice Dean and Professor of Dermatology

Rashmi Sarkar MD
Director -Professor,Dept of Dermatology

Reem Khater MD
Cosmetic Dermatologist, Consultant and laser Therapist

Rehab Hegazy MD
Professor of Dermatology

Reza Robati MD
Professor of Dermatology & Director

Roberto Amore MD
Professor of Dermatology

Roro Inge Ade Krisanti
Medical Doctor, Dermatovenereologist

Sabuhi ABILOV MD
Owner/Founder and Head Doctor

Safa AlSaadi MD
Specialist Dermatologist

Safwan Aladwan MD
Consultant Dermatology and Venereology

Salah Abdallat MD
Consultant and Head of Dermatology Department

Salah Al Rubaie MD
Consultant Dermatologist

Samar Khalil MD
General and Cosmetic Dermatologists

Sami Raza MD
Doctor

Samir Almahfoud MD
Consultant Dermatologist and president of the Syrian Arab Society of Dermatology

Sang Ju Lee MD
Director

Sanjanaa Srinivasa MD
Post Graduate

Sara Affara MD
Dermatologist

Conference **Speakers**

Sdrah Diab MD
Dermatology Resident

Seema Satyapal Singh MD
Specialist Dermatologist

Shaden Abdelhadi MD
Co-Chairman, International Clinical Case & Poster Presentation and Competition

Shady Mahmoud MD
Professor of Dermatology & Venereology

Shahid Javaid Akhtar MD
Head of Dermatology Department

Shanthala Shivananjappa MD
Founder & CEO

Sharmin Jahan MD
Consultant Dermatologist

Simone Amato MD
Dermatology Resident

Soha Khan MD
Consultant Dermatologist

Sonja Sattler MD
Dermatologist, Aesthetic Physician and CEO

Srie Prihianti Gondokaryono MD
Dermatovenereologist, Pediatric Dermatology Consultant and Vice President of International Affairs

Stefan Lipp MD
Executive Director and CMO

Stefania Guida MD
Assistant Professor of Dermatology

Stephane MEUNIER
CEO

Taewook Jeoung MD
General Practitioner

Tatyana Vinnik MD
Assistant Professor & Chief Physician

Thaer Douri MD
Dermatologist & Lecturer

Udaya Kumar Padubidri MD
Consultant Dermatologist and Head of

Umaima Khatoon MD
Medical Registrar

Usman Shahid MD
Resident Physician

Conference **Speakers**

Victoria Inene MD
Dermatologist & Aesthetic Medicine Doctor

Viral Desai MD
Plastic Cosmetic Surgeon

Wael Albarazi MD
Head of the Plastic, Reconstructive and Burns Department

Wahiba Suliman MD
Member of the Administrative Board

Waqas Saad MD
Consultant Dermatologist. Head of Dermatology Department

Wedad Abdelrahman MD
Consultant Dermatologist

Xinghua Gao MD
Professor, Chair of Dermatology and Deputy Director

Zainab Almossalli MD
Dermatology Counsaltant

Zbigniew Ruszczak MD
Chairman, International Clinical Case & Poster Presentation & Competition

Zekayi Kutlubay MD
Professor of Dermatology

Case Presentation and Competition for **Junior Dermatologists**

Afnan Samy MD
Resident Dermatologist

Nafkot Girum MD
Assistant professor of Dermatovenereology

Aiah Atiah Elfeky MD
Resident of Dermatology, andrology and venerology

Hadir Shakshouk MD
Assistant lecturer of Dermatology, Andrology and Venereology

Selamawit Yigletu MD
Assistant Professor of Dermatology and Venereology

Akriti Agrawal MD
Senior Resident

Zeinah AlHalees MD
Associate Consultant

Shashika Chandraratne MD
Acting Consultant Dermatologist

Nivvedhetha S. MD
Senior Resident

Case Presentation and Competition for **Resident Dermatologists**

Sara Affara MD
Dermatologist

Fida Anjum MD
Resident Dermatologist

Sajeda Alnabelsi MD
Resident

Jomol John MD
Junior Resident

Balaqis Alsaadi MD
Dermatology Resident

Jaswandi Shirodkar MD
Resident Doctor

Zamzam Al Qutaiti MD
Dermatology Resident

Reem Hasan MD
Resident

Viola Elvia Sequeira MD
Post Graduate Resident

Meera Al Marzooqi MD
Resident Dermatologist

Mariam Al Hammadi MD
Dermatology Resident

Khulood Al Marzooqi MD
Dermatology Resident

Alya Al Ali MD
Dermatology Resident

Sara Almarzooqi MD
Dermatology Resident

Mariam Alafeefi MD
Dermatology Resident

Taif Al Yammahi MD
Dermatology Resident

Sheikha Alketbi MD
Resident Dermatologist

Danya Alawadhi MD
Dermatology Resident

Ayesha Al Shawab MD
Dermatology Resident

Sanjana Mathew MD
Dermatology Resident

Case Presentation and Competition for **Resident Dermatologists**

Samreedhi Nath MD
Resident Dermatologist

Nidhin Niclavos MD
Dermatology Resident

Saeid Davoodi MD
Dermatology Resident

Shaikha Alhaj MD
Resident Dermatologist

Case Presentation - **Open Category**

Thaer Douri MD
Dermatologist & Lecturer

Elina Theodorakopoulou MD
Specialist in Dermatology

Shanthala Shivananjappa MD
Founder & CEO

Kelvin Chee Ling Tan MD
Medical Director

Fuad Temam Awel MD
MD, Dermatovenereology and Dermatopathology

Maha AlHussein
Senior Medical Student

Ameer Mushtak MD
Private Clinic

Fatma Al Hosni MD
Specialist Dermatologist

Shafia Mudassir MD
Consultant Dermatologist

Chiara Stocco MD
Plastic Surgeon

Amel Elsewh MD
Libya

Mohammed AlMalmi MD
Dermatologist Physician Specialist

Ronak Ahmed MD
Dermatology Specialist

Sanjana Mathew MD
Dermatology Resident

Ahmed Fayad MD
Specialist of Dermatology and Venereology

Apeksha Shyamalie Dissanayake Perera MD
Acting Consultant Dermatologist

Ahmed Zidan MD
Dermatology and Andrology Specialist

Chiranjaya Ekanayake MD
Dermatology

Jaswandi Shirodkar MD
Dermatology Resident Resident Doctor

Gelila Teshome MD
Medical Doctor

Case Presentation - **Open Category**

Vani Veggalam MD
Senior Consultant Dermatologist

Mihoub Bourakba MD
Specialist Dermatology

Natalia Imaeva MD
Dermatologist-Cosmetologist and Associate Professor

Qasim Abu Elrub MD
CEO, Medical Director and Dermatologist

PharmaResearch

2024
Dubai Derma

BOOTH 4E04(1F)

DOT™ DNA Optimizing Technology
for regenerative science

CONFERENCE PROGRAM

TUESDAY I 5 MARCH 2024

DAY ONE

CONFERENCE HALLS

1 | 2 | 3 | 4

DAY ONE TUESDAY

5th March 2024

CONFERENCE HALL 1

DERMATOLOGY SCIENCES & RESEARCH

09:00 - 09:30 **Opening Ceremony will take place in Conference Hall 3**

Session 1

Chairperson: Hesham Zaher MD, Mohsen Saleh Bin Rasheed MD

09:30 - 10:00 **Pain Assessment in Dermatology**
Jacek C. Szepietowski MD | Chair of the Department of Dermatology, Venereology and Allergology

10:00 - 10:30 **Thalidomide in Dermatology. Revisited**
Mohammed El Banhawy MD | Senior Consultant Dermatologist

10:30 - 11:00 **Application of Mild Local Hyperthermia for Mucocutaneous HPV Infections**
Xinghua Gao MD | Professor, Chair of Dermatology and Deputy Director

11:00 - 11:30 **Oral Agents in Melasma**
Rashmi Sarkar MD | Director -Professor,Dept of Dermatology

11:30 - 11:45 **Updates from Dermatology Journals**
Ameen Alawadhi MD | Consultant Dermatologist and Dermatopathologist, Head of Dermatology and Chairperson of Internal Medicine Department

11:45 - 12:00 **Management of Pustular Psoriasis**
Fouad El Sayed MD | Professor and Head of Dermatology, Lebanese University

12:00 - 12:15 **Estimation of Tissue Level of Human Beta-defensin 1 (Hbd-1) in Vitiligo Before and After Narrowband Ultraviolet B Phototherapy: A Case-control Study**
Hesham Zaher MD | Emeritus Professor of Dermatology

12:15 - 12:30 **Biofilms in Acne**
Ramesh Bhat MD | Vice Dean and Professor of Dermatology

12:30 - 13:00 **Problematic Pigmented Skin Lesions: Ways to Overcome**
Shady Mahmoud MD | Professor of Dermatology & Venereology

13:00 - 14:00 Q & A / Lunch Break

Session 2

Chairperson: Abdul Wahab Al Fouzan MD, Muna Al Murrawi MD, Assem Farag MD

14:00 - 14:30 **Science at The Forefront: Advancing Management of Inflammatory Acne**
Brigitte Dreno MD | Professor of Dermatology, Chairman of the Department of Dermato-Oncology and Director of the GMP Unit

DAY ONE TUESDAY
5th March 2024

CONFERENCE HALL 1
DERMATOLOGY SCIENCES & RESEARCH

14:30 - 15:00	**The Latest Breakthrough in Sun Protection** **Eggert Stockfleth MD** | Professor of Dermatology & Head of Skin Cancer Center
15:00 - 15:30	**Revolutionizing Care and Learning: New Paradigms in Psoriasis Therapies and Education** **Darrell S. Rigel MD** | Dermatologist and Clinical Professor of Dermatology **April Armstrong MD** | Professor and Chief of Dermatology
15:30 - 15:45	**Discussion**
15:45 - 16:00	**Q & A / Break**

Session 3
Chairperson: Dominique du Crest, Sonja Sattler MD

SKIN & DIGITAL SUMMIT/DIGITAL STARTUP CORNER

16:00 – 16:05	**Introduction** **Dominique du Crest** | Co-founder Skin & Digital Summit
16:05 - 16:20	**Artificial Intelligence: Where Are We & Where Are We Heading?** **Diala Haykal MD** | Cosmetic and Laser Doctor
16:20 – 16:50	**AI Assistance in Aesthetic Medicine - Introducing the Facial Attractiveness Index (FAI)** **Sonja Sattler MD** | Dermatologist, Aesthetic Physician and CEO
16:50 – 17:05	**Meet ANEEQ, the Platform that Makes it Easy for Men to Address their Health Concerns All from the Comfort and Privacy of their Homes** **Antoine Pichery** | CEO
17:05 – 17:20	**Ilik: Changing the Face of Dermatology** **Dina Sidani** | Founder and CEO
17:20 – 17:35	**Misinformation and How Doctors on Social Media Can Help** **Michael H. Gold MD** | Owner, Medical Director
17:35 – 17:50	**How to Build and Maintain Trust with Your Patients!** **Mahran Ashour** | Founder & Medical Director
17:50 -17:55	**Closing** **Dominique du Crest** | Co-founder Skin & Digital Summit

DAY ONE TUESDAY

5th March 2024

CONFERENCE HALL 2

THERAPEUTICS/NEW DRUGS/CASE PRESENTATIONS

09:00 - 09:30 **Opening Ceremony will take place in Conference Hall 3**

Session 1

Chairperson: Hussein Abdel Dayem MD, Makram Al Wais MD, Mohammed Al Abadie MD

09:30 - 09:55 **JAK Inhibitors for Alopecia Areata**
Hussein Abdel Dayem MD | Consultant Dermatologist

09:55 - 10:20 **Update on Pathophysiology and Treatment of Chronic Hairfall**
Salah Al Rubaie MD | Consultant Dermatologist

10:20 - 10:45 **Current and Future Treatment for Vitiligo**
Mohammed Al Abadie MD | Clinical Director & Consultant Dermatologist

10:45 - 11:30 **Share Me Your Experience: 40 Clinical Cases**
Khalifa Sharquie MD | Professor of Dermatology

11:30 - 12:00 **Challenging Clinical Cases: Share Me Experiences**
Khalil Alhamdi MD | Professor of Dermatology and Consultant Dermatologist

Session 2

Chairperson: Nawaf Al Mutairi MD, Reyad Mash'al MD

12:00 - 12:20 **Cutaneous Leishmaniasis in Middle East: Cur-rent Scenario**
Nawaf Al Mutairi MD | Professor and Head of The Department

12:20 - 12:40 **JAK Inhibitors: Small Molecules with Big Expectations**
Isam Oumeish MD | Consultant Dermatology and Venereology and Laser

12:40 - 13:00 **How To Maximize The Acne Scar Results With Exosomes & Energy Based Procedures: My Experience**
Shanthala Shivananjappa MD | Founder & CEO

13:00 - 14:00 Q & A / Lunch Break

Session 3

Chairperson: Khalil Alhamdi MD, Hazem Seif El Nasr MD

14:00 - 14:30 **Advances in the Treatment of Acne. Light and Laser Devices**
Jose Luis López-Estebaranz MD | Professor of Dermatology

14:30 - 14:45 **Pityriasis Rosea: Updates**
Ashraf Hamza MD | Professor of Dermatology and Venereology

DAY ONE TUESDAY

5th March 2024

CONFERENCE HALL 2

THERAPEUTICS/NEW DRUGS/CASE PRESENTATIONS

14:45 - 15:00	**Topical Vitamin D3 Derivative Versus Intralesional Vitamin D3 in the Treatment of Cutaneous Wart. A Clinical Therapeutic Comparative Study** **Khalil Alhamdi MD** | Professor of Dermatology and Consultant Dermatologist
15:00 - 15:15	**Post Acne Erythema: A New Treatment Modality** **Dooha Alhamdi MD** | Assistant Professor of Dermatology
15:15 - 15:30	**The Efficacy of Methotrexate in the Treatment of Bullous Pemphigoid** **Nemat Alsaghir MD** | Assistant Professor of Dermatology
15:30 -16:00	**Q & A / Break**

Session 4
Chairperson: Hessa Mohammed Al Bashr MD, Isam Oumeish MD

16:00 - 16:20	**Topical Metformin in Treating Acne Vulgaris: How New Routes Can Lead to Novel Destinations** **Nermeen Bedair MD** | Associate Professor of Dermatology
16:20 – 16:40	**A Modern Approach to Scar Management – Combining Physical with Chemical Processes** **Anna Maria Fenech Magrin MD** | Clinical Senior Lecturer and Deputy Course Co-ordinator
16:40 - 17:00	**The Role of Massive Comedone Extraction in the Management of Acne - Experience with 1191 Algerian Patients** **Mohamed Khouazem MD** | Specialist Dermatologist

Session 5
Chairperson: Shaden Abdelhadi MD

17:00 – 17:15	**Dermatology Interest Group** **Mahra Khaled Al Shehhi** | Senior Medical Student **Hajar Almansoor MD** | Medical Student
17:15 – 18:00	**Dermatology Teaching of My Undergraduate Medical Students - Where We Are Going?** **Zbigniew Ruszczak MD** | Chairman, International Clinical Case & Poster Presentation & Competition

DAY ONE TUESDAY

5th March 2024

CONFERENCE HALL 3

COSMETIC & SURGICAL DERMATOLOGY

09:00 - 09:30 **Opening Ceremony**

Session 1

Chairperson: Sonja Sattler MD, Mariam Al Suwaidi MD

09:30 - 10:00 **Long Term Data and Nuances Seen After 1726nm Laser Treatment of Acne**
David J. Goldberg MD | Director of Cosmetic Dermatology

10:00 - 10:30 **New Updates on Exosomes – in the US and Abroad**
Michael H. Gold MD | Owner, Medical Director

10:30 - 10:45 **Effects of Plate Cryolipolysis on The Cutaneous and Subcutaneous Tissue of the Abdominal Region**
Patricia Froes Meyer MD | Physiotherapist

10:45 - 11:15 **Stem Cells for Alopecia**
Zekayi Kutlubay MD | Professor of Dermatology

11:15 - 11:45 **Regenerative Aesthetics: Blood Fat Exosomes-What is the Key to Turning Back Time**
Maria Cristina Puyat MD | Dermatologist & Medical Director

11:45 - 12:00 **Ocular and Asymmetry Side Effects of Botulinum Toxin Injections**
Zekayi Kutlubay MD | rofessor of Dermatology

12:00 - 12:20 **Treatment of Severe Acne Scars. Prospective and Randomized Study of Highly Purified Polynucleotide Versus Placebo**
Antonino Araco MD | Specialist in Plastic Surgery

12:20 - 12:40 **New Concepts in HA Crosslinking for Dermal Fillers**
Stephane MEUNIER | CEO

12:40 - 13:00 **Non BDDE Cross Linking in HA Filler: New and Long-Term Safer Approaches for Our Patients**
Sonja Sattler MD | Dermatologist, Aesthetic Physician and CEO

13:00 - 14:00 Q & A / Lunch Break

Session 2

Chairperson: David J. Goldberg MD, Chytra Anand MD

14:00 - 14:20 **Novel Laser and Non-Laser Approaches to the Treatment of Melasma**
David J. Goldberg MD | Director of Cosmetic Dermatology

DAY ONE TUESDAY

5th March 2024

CONFERENCE HALL 3

COSMETIC & SURGICAL DERMATOLOGY

14:20 - 14:40 **Microneedling RF in 2024 – What Have We Learned**
Michael H. Gold MD | Owner, Medical Director

14:40 - 15:00 **Step Wise Approach for Facial Glamorisation**
Chytra Anand MD | Chief Consultant Cosmetic Dermatologist

15:00 - 15:20 **Fractional, Bipolar Radiofrequency in Facial Rejuvenation and Skin Resurfacing. A New Paradigm in Safety and Results**
Fadi Hamadani MD | Professor of Plastic Surgery, Division Chief, Plastic & Reconstructive Surgery

15:20 - 15:40 **Recent Insights into HIFU for Facial Contouring: Strategies and Innovations**
Do-Young Rhee MD | Director

15:40 - 16:00 Q & A / Break

Session 3
Chairperson: Michael H. Gold MD, Khalil AlArrayed MD

16:00 - 17:00 **Exosome: Panel Discussion**
Byongseong Cho MD | CEO and CTO
Shanthala Shivananjappa MD | Founder & CEO
Ilaria Proietti MD | Dermatologist
Abdullah Al Eisa MD | Consultant Dermatologist and Medical Director
David J. Goldberg MD | Director of Cosmetic Dermatology

17:00 - 17:15 **Evaluation of Intralesional Injection of Botulinum Toxin Type A or Hyaluronidase Enzyme Versus Intralesional Triamcinolone Acetonide in Treatment of Keloid**
Khaled Gharib MD | Professor of Dermatology and LASER

17:15 - 17:30 **Overview of Complications with Hyaluronic Acid (Ha)-Fillers**
Jesper Thulesen MD | Ophthalmologist and Oculoplastic surgeon

17:30 - 17:45 **Complications and Sad Effects after Cosmetic Injections**
Laurent Benadiba MD | Plastic Surgeon

17:45 - 18:00 **Role of Hyaluronidase in The Treatment of Complications of Hyaluronic Dermal Filler**
Mohamad Essam Kayyali MD | Consultant of Plastic Surgery

18:00 - 18:15 **Tear Trough Correction Using High G Prime Hyaluronic Acid Filler: My Innovative Bolus Technique**
Afsheen Bilal MD | CEO, Consultant Dermatologist

DAY ONE TUESDAY

5th March 2024

CONFERENCE HALL 4

ASSOCIATION PROGRAM

09:00 - 09:30 **Opening Ceremony will take place in Conference Hall 3**

Session 1: SHARM DERMA Session
Chairperson: Assem Farag MD

09:30 - 09:50 **Alopecia Areata: My New Data**
Assem Farag MD | Professor of Dermatology

09:50 - 10:10 **Tips & Tricks in Scar Management**
Shady Mahmoud MD | Professor of Dermatology & Venereology

10:10 - 10:30 **Psoriasis: Clinical Tips**
Amin Sharobim MD | Lecturer of Dermatology

10:30 - 10:50 **JAK Inhibitors: Updated**
Assem Farag MD | Professor of Dermatology

10:50 – 11:10 **Tips in Midface and Tear Trough Injection**
Nevine Dorgham MD | Professor of Dermatology

11:10 - 11:30 **Tips in Upper Face and Temple Injection**
Amin Sharobim MD | Lecturer of Dermatology

11:30 – 11:50 **Updated Tips in Botulinum Toxin Injection**
Rehab Hegazy MD | Professor of Dermatology

11:50 - 12:10 **Tips & Tricks in Laser Practicing in Dermatology & Aesthetics**
Shady Mahmoud MD | Professor of Dermatology & Venereology

12:10 - 12:30 **Tips in Melasma & Face Pigmentation**
Nevine Dorgham MD | Professor of Dermatology

12:30 - 12:50 **Off Label Uses of Drugs in Dermatology**
Rehab Hegazy MD | Professor of Dermatology

12:50 - 14:00 **Q & A / Lunch Break**

DAY ONE TUESDAY

5th March 2024

CONFERENCE HALL 4

ASSOCIATION PROGRAM

Session 2: International Society of Dermatologists (ISD) Session

Chairperson: Abdullah Alakeel MD, Hassan Galadari MD

14:00 - 14:15	**MicroBotox: Rising Trend or a Fading Fad?** **Hassan Galadari MD** | Associated Professor of Dermatology
14:15 - 14:30	**Hidradenitis suppurativa: An Update** **Jacek C. Szepietowski MD** | Chair of the Department of Dermatology, Venereology and Allergology
14:30 - 14:45	**Post-inflammatory Hyperpigmentation, The Other Side of the Inflammation** **Giovanni Pellacani MD** | Chairman of Dermatology Department
14:45 - 15:00	**Spot Light on Translational Studies in China** **Xinghua Gao MD** | Professor, Chair of Dermatology and Deputy Director
15:00 - 15:15	**Acquired Dermal Macular Hyperpigmentation** **Rashmi Sarkar MD** | Director -Professor,Dept of Dermatology
15:15 - 15:30	**What's the Deal with Exosomes?** **Samar Khalil MD** | General and Cosmetic Dermatologists
15:30 - 15:45	**Q & A / Break**

Session 3: SIDEMAST Session

Chairperson: Giovanni Pellacani MD, Ketty Peris MD

15:45 - 16:05	**Inflammatory Skin Disease and Imaging** **Giovanni Pellacani MD** | Chairman of Dermatology Department
16:05 - 16:20	**Effectiveness and Safety of a 675 nm Laser Device in the Treatment of Facial Aging and Melasma** **Elena Zappia MD** | Medical Doctor
16:20 - 16:40	**Medical Approach to Skin Pigmentation** **Stefania Guida MD** | Assistant Professor of Dermatology
16:40 - 17:00	**Spesolimab in the Treatment of Generalized Pustular Psoriasis** **Annunziata Dattola MD** | Researcher at Department of Dermatology University of La Sapienza, Rome

DAY ONE TUESDAY

5th March 2024

CONFERENCE HALL 4

ASSOCIATION PROGRAM

17:00 - 17:15 **Extreme Makeover-injectable Edition: Beyond Beautification**
Ilaria Proietti MD | Dermatologist

17:15 - 17:30 **A New Technology in Non-invasive Face Contouring and Rejuvenation**
Elena Zappia MD | Medical Doctor

17:30 - 17:45 **Which Injectable for Different Skin Conditions? Evaluation by 2D,3D Photographs, RMC, Ultrasound, and Oct**
Federica Trovato MD | Dermatology Resident

ABG LAB®

FUTURE FORWARD
SKINCARE

ABG Lab is dedicated to providing highly-regarded aesthetic products specifically designed to target various clinical niches.

Our solutions are built on well-established aesthetic platforms, allowing patients to achieve vibrant, youthful skin without requiring invasive procedures.

STAND NO. 8B20

www.abglab.com

CONFERENCE PROGRAM

Wednesday I 6 MARCH 2024

DAY TWO

CONFERENCE HALLS

1 | 2 | 3 | 4

DAY TWO WEDNESDAY

6th March 2024

CONFERENCE HALL 1

DERMATOLOGY SCIENCES & RESEARCH

Session 4

Chairperson: Fouad El Sayed MD, Firas Al Qarqaz MD, Ali Singel MD

08:30 - 09:00	**Psychosocial Burden of Acne** **Jacek C. Szepietowski MD** | Chair of the Department of Dermatology, Venereology and Allergology
09:00 – 09:30	**Update in the Management of Lichen Planus** **Fouad El Sayed MD** | Professor and Head of Dermatology
09:30 - 09:45	**Concepts and Differences of Platelet-Rich Plasma (PRP), Platelet-Poor Plasma (PPP), and Platelet-Rich Fibrin (PRF)** **Burcu Yamangöktürk Solak MD** | Dermatologist, General Secretary and Founding Member
09:45 - 10:00	**Autologous Plasma Gel; Facts and Pearls for Practice** **Ersan ÖN MD** | Dermatologist, Treasurer General
10:00 - 10:15	**Psoriasis and Metabolic Syndrome** **Abdullah Al Eisa MD** | Consultant Dermatologist and Medical Director
10:15 - 10:30	**Exosomes and Hair Loss** **Abdullah Al Eisa MD** | Consultant Dermatologist and Medical Director
10:30 - 11:00	**Q & A / Break**

Session 5: Pigmentation & Vitiligo

Chairperson: : Manal Bosseila MD, Fouz Hassan MD

11:00 - 11:15	**The Many Faces of Bcc: Dermoscopic Identification** **Manal Bosseila MD** | Professor of Dermatology
11:15 - 11:30	**Selecting the Appropriate Biologic in Psoriasis** **Dalia Shaaban MD** | Professor of Dermatology and Venereology
11:30 - 11:45	**The Efficacy and Safety of Micro-needling Combined with Tacrolimus versus Tacrolimus Monotherapy for Vitiligo Treatment: A Systematic Review and Meta-analysis** **Hadeel Maaddawi MD** | Medical Intern
11:45 - 12:00	**Experience in Treating Vitiligo Patients at King Abdullah University Hospital (KAUH), Jordan** **Diala Alshiyab MD** | Associate Professor and Consultant Dermatologist

DAY TWO WEDNESDAY

6th March 2024

CONFERENCE HALL 1

DERMATOLOGY SCIENCES & RESEARCH

12:00 - 12:15 **Childhood Psoriasis**
Jayakar Thomas MD | Emeritus Professor, Founder and National Chairman

12:15 - 12:30 **Implications of Dilated Nail Bed Capillaries in Normal Looking Nails of Children with Mild Psoriasis – Pilot Study**
Parimalam Kumar MD | Professor & Head of the Department of Dermatology

12:30 - 12:45 **Efficacy and Safety of Oral Apremilast in Patients of Mild to Moderate Chronic Plaque Psoriasis**
Ashba Nasir Cheema MD | Consultant Dermatologist

12:45 - 13:00 **Melanoma in Non-European Ethnic Population and Utilization of Radiological and Molecular Imaging in The Management of Melanoma in Aotearoa New Zealand**
Umaima Khatoon MD | Medical Registrar

13:00 - 14:00 Q & A / Lunch Break

Session 6: Hair

Chairperson: Mohamed Elazzab MD, Alia Al Mualla MD, Bakri Al Agraa MD

14:00 - 14:15 **Borderline Leprosy is One of the Greatest Imitators in Dermatology**
Mohammed Elazab MD | Consultant Dermatologist & Chairman

14:15 - 14:30 **Topical Pentoxifylline; Metformin Versus Betamethasone in the Treatment of Alopecia Areata: A Clinical and Dermoscopic Study**
Alaa Eldin Moubasher MD | Professor of Dermatology, Venereology and Andrology

14:30 - 14:45 **The Evidence Behind Topical Hair Loss Remedies on Social Media.**
Reem Khater MD | Cosmetic Dermatologist, Consultant and laser Therapist

14:45 - 15:00 **Antiandrogens and Hair: Update**
Adel Alsantali MD | Consultant Dermatologist, Head of Dermatology Department

15:00 - 15:15 **What's New and Hot in Alopecia Areata Management?**
Adel Alsantali MD | Consultant Dermatologist, Head of Dermatology Department

15:15 - 15:30 **Comparison of Efficacy and Safety of Biogenetically engineered Exosomes versus Platelet Rich Plasma in Patients of Androgenetic Alopecia: A Randomized Control Trial**
Alina Abbass MD | Senior Registrar

15:30 - 15:45 **Dermoscopy Guided Biopsy**
Amal Wagih MD | Specialist of Dermatology

DAY TWO WEDNESDAY

6th March 2024

CONFERENCE HALL 1

DERMATOLOGY SCIENCES & RESEARCH

15:45 - 16:00	**Q & A / Break**

Session 7

Chairperson: Amani Abdulla Alfalasi MD, Badreya Alshehhi MD, Samir Almahfoud MD

16:00 - 16:15	**A Descriptive Study of Patterns of Genital Dermatoses in Patients Attending A Tertiary Care Centre in South India and Assessment of Quality of Life, Depression and Anxiety in Them** **Anupa Job MD** | Assistant Professor
16:15 - 16:30	**A Case of Bullous Pemphigoid in an Immunosuppressed Renal Transplant Child- a Paradoxical Phenomenon?** **Wedad Abdelrahman MD** | Consultant Dermatologist
16:30 - 16:45	**The Frequency of Different Causes of Facial Melanosis in A Series of 2020 Cases** **Waqas Saad MD** | Consultant Dermatologist. Head of Dermatology Department
16:45 - 17:00	**Holistic Needs Assessment and Skin Cancer in The Uk: What Can We Learn? A National Survey** **Sami Raza MD** | Doctor
17:00 - 17:15	**What's New and Hot in Alopecia Areata Management?** **Olga Orlova MD** | Head of the Center
17:15 - 17:30	**Efficacy of Combined Treatment with Adipose Tissue Stem Cell Exosomes (Asce) and Microneedling for Facial Skin Aging: A 12-week Prospective, Randomized, Split-face Study** **Taewook Jeoung MD** | General Practitioner
17:30 - 17:45	**Role of Direct Immunofluorescence on Tzanck Smear and Plucked Hair in the Diagnosis of Pemphigus Vulgaris** **Kehkshan Tahir MD** | Associate Professor

DAY TWO WEDNESDAY

6th March 2024

CONFERENCE HALL 2

THERAPEUTICS/NEW DRUGS/CASE PRESENTATIONS

INTERNATIONAL CLINICAL CASE PRESENTATION AND COMPETITION

Session 6 : Junior Dermatologists Competition

Jury Members:
Zbigniew Ruszczak MD | Chairman, International Clinical Case & Poster Presentation & Competition
Shaden Abdelhadi MD | Co-Chairman, International Clinical Case & Poster Presentation and Competition
Mohammed El Banhawy MD | Senior Consultant Dermatologist

09:00 - 09:10 **Case Presentation**
Afnan Samy MD | Resident Dermatologist

09:10 - 09:20 **A Rare Case of Cutaneous Metastasis from Poorly Differentiated Thyroid Carcinoma**
Nafkot Girum MD | Assistant professor of Dermatovenereology

09:20 - 09:30 **What is Wrong with this Child Scalp?**
Aiah Atiah Elfeky MD | Resident of Dermatology, andrology and venerology

09:30 - 09:40 **Bloom Syndrome with Growth Hormone Deficiency: A Rare Association of A Rare Syndrome**
Hadir Shakshouk MD | Assistant lecturer of Dermatology, Andrology and Venereology

09:40 - 09:50 **Pagetâs Disease of the Breast Mimicking Chronic Eczema**
Selamawit Yigletu MD | Assistant Professor of Dermatology and Venereology

09:50 - 10:00 **Pancreatitis, panniculitis and polyarthritis- A Rare Presentation**
Akriti Agrawal MD | Senior Resident

10:00 - 10:10 **Diving Deep into Yao Syndrome: Causes, Symptoms, and Treatment**
Zeinah AlHalees MD | Associate Consultant

10:10 - 10:20 **Atypical Presentations of Cutaneous Leishmaniasis**
Shashika Chandraratne MD | Acting Consultant Dermatologist

10:20 - 10:30 **Angiolymphoid Hyperplasia with Eosinophilia : Is it Vascular or Reactive?**
Nivvedhetha S. MD | Senior Resident

10:30 - 10:40 **An Unexpected Cause of Recurrent Sustained Viral Skin Infection**
Hadir Shakshouk MD | Assistant lecturer of Dermatology, Andrology and Venereology

10:40 -11:00 Q & A / Break

DAY TWO WEDNESDAY

6th March 2024

CONFERENCE HALL 2

THERAPEUTICS/NEW DRUGS/CASE PRESENTATIONS

Session 7: Resident Dermatologists Competition - Part 1

Jury Members:

Zbigniew Ruszczak MD | Chairman, International Clinical Case & Poster Presentation & Competition

Shaden Abdelhadi MD | Co-Chairman, International Clinical Case & Poster Presentation and Competition

Mohammed El Banhawy MD | Senior Consultant Dermatologist

11:00 - 11:10	**Is Basaloid Follicular Hamartoma a New Additional Criterion to Nevoid Basal Cell Carcinoma Syndrome?** **Sara Affara MD** | Dermatologist
11:10 - 11:20	**Self Mutilating Behavior in A 2-Year-Old Girl Unveiling the Diagnosis of A Rare Entity** **Fida Anjum MD** | Resident Dermatologist
11:20 - 11:30	**Non-surgical Treatment of Verrucous Hyperplasia on Amputation Stump** **Sajeda Alnabelsi MD** | Resident
11:30 - 11:40	**Eccrine Angiomatous Hamartoma: Unveiling An Uncommon Dermatological Entity - A Case Report** **Jomol John MD** | Junior resident
11:40 - 11:50	**Childhood Granulomatous Perioral Dermatitis** **Balaqis Alsaadi MD** | Dermatology resident
11:50 - 12:00	**1 in a Million: A Boy with Silvery Hair** **Jaswandi Shirodkar MD** | Resident Doctor
12:00 - 12:10	**Brucellosis-induced Leukocytoclastic Vasculitis** **Zamzam Al Qutaiti MD** | Dermatology resident
12:10 - 12:20	**Treatment of Hypotrichosis Simplex of the Scalp with Topical Gentamicin** **Reem Hasan MD** | Resident
12:20 - 12:30	**Lumps, Bumps and Joints so Stiff: Hyaline Fibromatosis Syndrome** **Viola Elvia Sequeira MD** | JPost Graduate Resident
12:30 - 13:00	**Q & A**
13:00 - 14:00	**Lunch Break**

DAY TWO WEDNESDAY

6th March 2024

CONFERENCE HALL 2

THERAPEUTICS/NEW DRUGS/CASE PRESENTATIONS

Session 8: Resident Dermatologists Competition - Part 2

Jury Members:
Zbigniew Ruszczak MD | Chairman, International Clinical Case & Poster Presentation & Competition
Shaden Abdelhadi MD | Co-Chairman, International Clinical Case & Poster Presentation and Competition
Mohammed El Banhawy MD | Senior Consultant Dermatologist

14:00 - 14:10 **Seven years in Distress**
Meera Al Marzooqi MD | Dermatology Resident

14:10 - 14:20 **Acute Genital Ulcer**
Mariam Al Hammadi MD | Dermatology Resident

14:20 - 14:30 **Crawling Shadows: Unraveling Challenges in the Management of Delusional Infestation**
Khulood Al Marzooqi MD | Dermatology Resident

14:30 - 14:40 **More than Eczema??**
Alya Al Ali MD | Dermatology Resident

14:40 - 14:50 **Look Beyond the Scales**
Sara Almarzooqi MD | Dermatology Resident

14:50 - 15:00 **A Series of Unfortunate Events: Life with a Genetic Disease**
Mariam Alafeefi MD | Dermatology Resident

15:00 - 15:10 **The Puzzling Rash? Bring out your Detective Skills**
Taif Al Yammahi MD |**Dermatology Resident**

Session 9: Resident Dermatologists Copmetition - Part 3

Jury Members:
Zbigniew Ruszczak MD | Chairman, International Clinical Case & Poster Presentation & Competition
Shaden Abdelhadi MD | Co-Chairman, International Clinical Case & Poster Presentation and Competition
Mohammed El Banhawy MD | Senior Consultant Dermatologist

15:10 - 15:20 **Painful Rash**
Sheikha Alketbi MD | Resident Dermatologist

15:20 - 15:30 **When Two Histological Patterns Collide**
Danya Alawadhi MD | Dermatology Resident

15:30 - 15:40 **Harmony in Chaos**
Ayesha Al Shawab MD | Resident

DAY TWO WEDNESDAY

6th March 2024

CONFERENCE HALL 2

THERAPEUTICS/NEW DRUGS/CASE PRESENTATIONS

15:40 - 16:00	**Q & A / Break**

Session 10: Resident Dermatologists Competition - Part 4

Jury Members:
Zbigniew Ruszczak MD | Chairman, International Clinical Case & Poster Presentation & Competition
Shaden Abdelhadi MD | Co-Chairman, International Clinical Case & Poster Presentation and Competition
Mohammed El Banhawy MD | Senior Consultant Dermatologist

16:00 - 16:10	**A Not so Nosy Nodule - A Rare Case of Nodular Amyloidosis Disguising as Sarcoidosis** **Sanjana Mathew MD** | Resident Dermatologist
16:10 - 16:20	**Pemphigus Vegetans With Deep Scalp Ulcer: An Uncommon Presentation** **Samreedhi Nath MD** | Resident Dermatologist
16:20 - 16:30	**Cases Series on Lichen Planus Pemphigoides** **Nidhin Niclavos MD** | Resident Dermatologist
16:30 - 16:40	**Encephalocraniocutaneous Lipomatosis** **Saeid Davoodi MD** | Resident Dermatologist
16:40 - 16:50	**Angiolymphoid Hyperplasia with Eosinophilia, Rare Tumor and Rare Association** **Aya Allamki MD** | Dermatology Resident
16:50 - 17:00	**An Unusual Presentation of the Merkel Cell Carcinoma of the Right Cheek: A Case Report** **Shaikha Alhaj MD** | Resident Dermatologist
16:50 - 17:00	**Disseminated Tuberculosis With Cutaneous Involvement In An Immunocompetent Patient** **Reham Alshehri** | Medical Intern
17:00 – 17:45	**Expert Education Lecture** **Zbigniew Ruszczak MD** | Chairman, International Clinical Case & Poster Presentation & Competition
17:45 - 18:00	**Q/A**

DAY TWO WEDNESDAY

6th March 2024

CONFERENCE HALL 3

COSMETIC & SURGICAL DERMATOLOGY

Session 4

Chairperson: Andre Mattos MD, Mohamed Adib Batal MD

08:30 - 09:00	**Update on the Changing World of Non-Invasive Body Contouring** **David J. Goldberg MD** | Director of Cosmetic Dermatology
09:00 - 09:30	**New Toxins in the US – What is Making its Way Through the Clinical Trial Domain in 2024** **Michael H. Gold MD** | Owner, Medical Director
09:30 - 10:00	**Comparative Study Between Plate Cryolipolysis and Vacuum in Dermal and Hypodermal Tissue** **Patricia Froes Meyer MD** | Physiotherapist
10:00 - 10:30	**Hemostatic Net - A Safer Facelift** **Andre Mattos MD** | Plastic Surgeon
10:30 - 10:45	**Botox Treatment for Hair Loss and Baldness** **Khaled Othman MD** | Consultant Dermatology, Andrology, Aesthetic Medicine & Laser
10:45 - 11:00	**Q & A / Break**

Session 5

Chairperson: Minal Patwardhan MD, Hadaf Aljunaiyeh MD, Simin Ahari MD

11:00 - 11:20	**Management of photoaging through the infiltration of hybrid fillers based on hyaluronic acid and calcium Hydroxvapatite at different concentrations** **Ilaria Proietti MD** | Dermatologist
11:20 - 11:40	**Role of Nutraceuticals in Regenerative Dermatology** **Seema Satyapal Singh MD** | Specialist Dermatologist
11:40 - 12:00	**Use of Progenitor Cells in Hair Restoration** **Shweta Singh MD** | Specialist Dermatologist
12:00 - 12:20	**Adverse Effects of Botulinum Toxin in Cosmetic Uses** **Fouz Hassan MD** | Head of the Department of Dermatology and Venereology
12:20 - 12:40	**Solid State Laser for Macular and Linear Vascular Lesions** **Nicola Zerbinati MD** | Associate Professor of Dermatology and Venereology

DAY TWO WEDNESDAY

6th March 2024

CONFERENCE HALL 3

COSMETIC & SURGICAL DERMATOLOGY

12:40 - 13:00	**Simultaneous Ablative and Non-ablative Fractional Skin Resurfacing with Differential Densities: How to Maximize Results with Minimal Downtime** **Nicola Zerbinati MD** | Associate Professor of Dermatology and Venereology
13:00 - 14:00	**Q & A / Break**

Session 6: IMCAS Session: Prejuvenation, Just an Illusion?
Chairperson: Hugues Cartier MD, Hassan Galadari MD

14:00 - 14:15	**Mini Battle: Prejuvenation, The Ageless Paradox** **Hugues Cartier MD** | Dermatologist **Hassan Galadari MD** | Associated Professor of Dermatology
14:15 - 14:30	**Aging Backwards: The Prejuvenation Prescription** **Diala Haykal MD** | Cosmetic and Laser Doctor
14:30 - 14:45	**Skin Prejuvenation Strategies: Stimulation rather than Inflammation** **Arnaud Lambert MD** | Physician and Medical Director
14:45 - 15:00	**The Aesthetic Generation - The Fake Generation** **Dominique du Crest** | Co-founder Skin & Digital Summit

Session 7
Chairperson: Reza Robati MD, Mohamed Bazza MD

15:00 - 15:15	**Botulinum Toxin Applications in the Lower Face and Neck** **Reza Robati MD** | Professor of Dermatology & Director
15:15 – 15:30	**Correction Of Nasolabial Folds Wrinkle Using Intraoral Non-ablative Er:Yag Laser** **Khaled Gharib MD** | Professor of Dermatology and LASER
15:30 - 15:45	**Revolutionizing Auricular Keloid Treatment: The Power of Combined CO2 and Dye Laser Therapy** **Simone Amato MD** | Dermatology Resident
15:45 – 16:00	**Q & A / Break**

DAY TWO WEDNESDAY

6th March 2024

CONFERENCE HALL 3

COSMETIC & SURGICAL DERMATOLOGY

Session 8

Chairperson: Ahmed Alqahtani MD, Azer Rashid MD

16:00 - 16:15	**The Exosomes Story: Who is Questioning?** **Ahmed Alqahtani MD** | Assistant Professor
16:15 - 16:30	**Tissue Fibroplasia as A Modern Mechanism Used in Mesotherapy** **Izabela Zaleska MD** | Specialist in Aesthetic, Medical and Therapeutic Cosmetology
16:30 - 16:45	**Microneedling Delivery of Botulinum Toxin Versus Its Intradermal Injection in The Treatment of Facial Hyperhidrosis** **Amany Nassar MD** | Professor and Head of the Dermatology department
16:45 - 17:00	**Collagen Zero a New Paradigm in Therapy of Collagen Deficiency in Skin** **Stefan Lipp MD** | Executive Director and CMO
17:00 - 17:15	**Dark Circles Under the Eyes Treatment** **Victoria Inene MD** | Dermatologist & Aesthetic Medicine Doctor
17:15 - 17:30	**Eyebrow Transplant, Is It Worth Doing?** **Hossein Yavari MD** | Specialist Dermatologist
17:30 - 17:45	**The Lipid Shield of The Skin How to Protect the Skin Protection** **Stefan Lipp MD** | Executive Director and CMO
17:45 - 18:00	**Face Lift And Rejuvenation by Monofilament and Cogged Polydioxanone Threads** **Amany Nassar MD** | Professor and Head of the Dermatology department
18:00 - 18:15	**Evaluation of Outcome of 808nm Diode in Hirsutism** **Sharmin Jahan MD** | Consultant Dermatologist

DAY TWO WEDNESDAY

6th March 2024

CONFERENCE HALL 4

ASSOCIATION PROGRAM

Session 4: Rafidianderma Forum for Dermatology and Aesthetics (RFDA) Session

Chairperson: Khalifa Sharquie MD

08:30 - 08:45 **Procedural and Laser Treatment of Acne Scar**
Muhsin A. Al-Dhalimi MD | Professor of Dermatology and Head of the Department of Dermatology

08:45 - 09:00 **Sarcoidosis As Un Upsuring Mimicking Granulomatous Disease**
Khalifa Sharquie MD | Professor of Dermatology

09:00 - 09:15 **Micro-needling in Melasma: A New Modern Advance Therapeutic Option**
Ahmed Abdul-Aziz Ahmed MD | Consultant Dermatologist & Assistant Professor

09:15 - 09:30 **Treatment of Pemphigus Vulgaris with the Rituximab**
Ali Fadhil Al-Saadi | Professor and Consultant Dermatologist

09:30 - 09:45 **Treatment of Plane Warts with Long Pulse ND – Yag Laser 532 nm**
Haider Al-Sabak MD | Head of Dermatology and Laser Department

09:45 - 10:00 **Efficacy of Low Energy Fractional Co2 Laser in the Treatment of Alopecia Areata**
Dindar Sharif Qurtas MD | Dermatologist, Assistant Professor

Session 5: Face Aesthetic Dermatologist Society (FADS) Session

Chairperson: TA Rana MD

10:00 - 10:20 **Composite and Enriched Facial Fat Grafting**
Viral Desai MD | Plastic Cosmetic Surgeon

10:20 - 10:40 **New Age Thread Lift**
Jyotirmay Bharti MD | Consultant Dermatologist & Hair Transplant Surgeon

10:40 - 11:00 Q & A / Break

Session 6: Pakistan Association of Dermatologists (PAD) Session

Chairperson: Zafer Ullah Khan MD, Saadia Tabassum MD, Shahid Javaid Akhtar MD

11:00 - 11:15 **Presentation and Mimickers of Melasma**
Shahid Javaid Akhtar MD | Head of Dermatology Department

11:15 - 11:30 **Treatment Strategies for Melasma**
Asma Tariq MD | Senior Registrar

DAY TWO WEDNESDAY

6th March 2024

CONFERENCE HALL 4

ASSOCIATION PROGRAM

11:30 - 11:45 **Tranexamic Acid for Melasma**
Abdul Hameed MD | Medical Director, Consultant

11:45 - 12:00 **Multimodality Treatment of Stubborn Melasma**
Kalsoom Jawaid MD | Assistant Professor

Session 7: Indonesian Society of Dermatology and Venereology (INSDV) Session

Chairperson: Muhammad Yulianto Listiawan MD

12:00 - 12:15 **Picolaser 755 nm with Diffractive Lens Array for Wrinkles in Skin of Color**
Muhammad Yulianto Listiawan MD | Professor of Dermatology and Dermatovenereologist

12:15 - 12:30 **Correlation of Ultraviolet B Intensity and High Vitamin D Food Intake with the Level of 25(OH)D Serum in Healthy Indonesian Children**
Srie Prihianti Gondokaryono MD | Dermatovenereologist, Pediatric Dermatology Consultant and Vice President of International Affairs

12:30 - 12:45 **Induction of Skin Carcinogenesis with Narrowband UVB (311 nm) Using Wistar Rat Animal Model**
Roro Inge Ade Krisanti | Medical Doctor, Dermatovenereologist

12:45 - 13:00 **Management of Post Inflammatory Hyperpigmentation**
Diah Puspitosari MD | Medical consultant, Member of the research team and Dermatologist practitioner

13:00 - 14:00 Q & A / Lunch Break

Session 8: Jordanian Society for Dermatology and Venereology (JSDV) Session

Chairperson: Firas Al Qarqaz MD

14:00 - 14:15 **Hidradenitis Suppurativa: Dilemma of Pathogenesis and Therapeutic Options**
Salah Abdallat MD | Consultant and Head of Dermatology Department

14:15 - 14:30 **Acne Vulgaris: More Work still Needed**
Firas Al Qarqaz MD | Consultant Dermatologist

14:30 - 14:45 **Biologic Treatment of Psoriasis at Individual Level**
Salah Abdallat MD | Consultant and Head of Dermatology Department

14:45 - 15:00 **Apremilast, A Small Molecule with Big Potential**
Firas Al Qarqaz MD | Consultant Dermatologist

DAY TWO WEDNESDAY

6th March 2024

CONFERENCE HALL 4

ASSOCIATION PROGRAM

Session 9: Oman Dermatology Society Session

Chairperson: Ahmed Al Waily MD

15:00 - 15:15	**Difficult to Treat Psoriasis** **Ahmed Al Waily MD** | Senior Consultant Dermatologist
15:15 - 15:30	**Dermatodietitics : Unveiling the Impact of Nutrition on Dermatological Health and Diseases** **Amera Elsayed Bayumi MD** | Aesthetic Dermatology specialist
15:30 - 15:45	**Q & A / Break**

Session 10: Emirates Dermatology Society (EDS) Session

Chairperson: Raghda Al Maashari MD, Jawaher Alnaqbi MD

15:45 - 16:05	**Filler Migration, A Trending Issue After Years of InjectingHyaluronic Acid** **Safa AlSaadi MD** | Specialist Dermatologist
16:25 - 16:45	**Lupus: "The wolf"** **Raghda Al Maashari MD** | Dermatology Consultant
16:45 - 17:05	**Clinical Features and Management of Inducible Urticaria** **Udaya Kumar Padubidri MD** | Consultant Dermatologist

VISIT US PAVILION BOOTH #PB01

CosmeRNA

The world's first RNAi Driven Cosmetic for Androgenetic Alopecia

SCIENTIFIC REPORTS

Clinically Proven Efficacy

ORIGINAL EXCELLENT dermatest

Proven Skin Safety

User Convenience (Once Every 2 Weeks)

Safe for Both Men and Women

Precision Targeting of Androgen Receptor (AR) mRNA in Human Hair Follicles

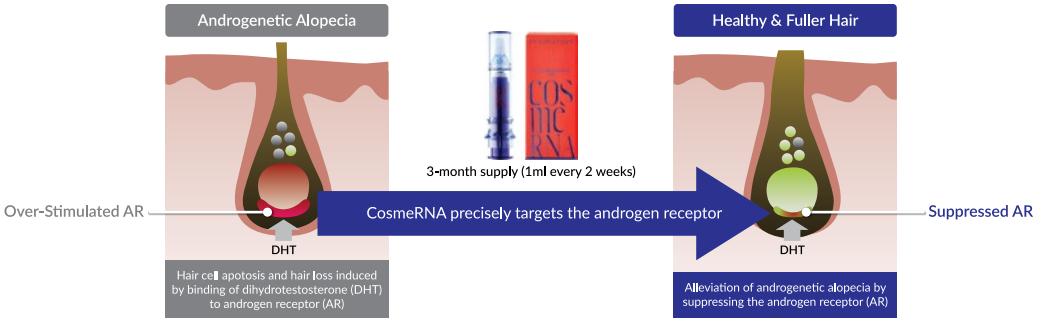

Clinically Proven Results Published in SCIENTIFIC REPORTS by Nature Journal

Increase of Hair Strands by

7.5 / 1 cm²

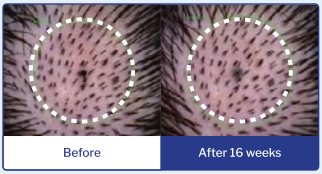

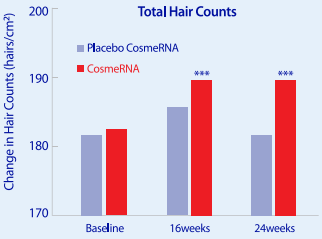

For evaluation of total hair counts, the hair was clipped approximately 2 mm after a red spot tattoo in the evaluation area (1 cm2) of the hair loss region (forehead hairline or vertex). The total hair counts were assessed using a Folliscope® 2.8 phototrichogram system (magnification 14 times, LeadM) at baseline and at 16 weeks and 24 weeks after treatment. The total hair count (number/cm2) was calculated as the number of hairs within an area.

7.5 / 1cm 2 in 4 months

	Placebo (n=22)	Cosmerna 5 mg/mL (n=21)
♂	9	10
♀	13	11

Method: 1mL of application on the scalp once per week, with 5 minutes of massaging for better absorption

Clinically Tested. Proven Results.

REF) Weekly treatment with SAMiRNA targeting the androgen receptor ameliorates androgenetic alopecia. Sci Rep. 2022 Jan 31;12(1):1607. CosmeRNA

Bioneer CORP. | E-mail: support@cosmerna.com | www.cosmerna.com

CONFERENCE PROGRAM

Thursday I 7 MARCH 2024

DAY THREE

CONFERENCE HALLS

1 | 2 | 3 |4

DAY THREE THURSDAY

7th March 2024

CONFERENCE HALL 1

DERMATOLOGY SCIENCES & RESEARCH

Session 8

Chairperson: Mahdi Shamad MD, Dhaifallah Alghowairi MD

08:30 - 08:45	**Dermatophytosis Severity Score- A Novel Method to Assess Severity of Superficial Fungal Infections & It's Clinical Implications** **Ramesh Bhat MD** | Vice Dean and Professor of Dermatology
08:45 - 09:00	**Parasitic Infestations of the Skin: Clinical Presentations and Photos** **Mahdi Shamad MD** | Associate Professor and Dean
09:00 - 09:15	**Paraneoplastic Dermatosis** **Monira El Waseef MD** | Fellowship trainer
09:15 - 09:30	**Clinical Manifestation of Some Oral Diseases** **Nadia Abdelwadood MD** | Consultant of Dermatology and Sexually Transmitted Infection
09:30 - 09:45	**Skin Manifestations Following Eating Some Types of Spoiled Fish** **Omar F. Najjari MD** | Paediatrician & Paed. Toxicologist
09:45 - 10:00	**Muir-torre Syndrome and Sebaceous Hyperplasia** **Huda H. Tahlawi MD** | Dermatologist & Venereologist
10:00 - 10:15	**Cutaneous Changes Associated with Menopause** **Harb Al-Omari MD** | Consultant Dermatology, Andrology & STDs
10:15 - 10:30	**Methotrexate Gel Either Alone or Combined with Narrow Band Ultraviolet B or Excimer Light for the Treatment of Vitiligo** **Khaled Gharib MD** | Professor of Dermatology and LASER
10:30 - 11:00	**Q & A / Break**

Session 9

Chairperson: Ahmed Al Waily MD, Fatima Al Shamsi MD

11:00 - 11:15	**Skin Thickness and Internal Organ Involvement in Patients of Scleroderma** **Fareheen Ashfaq MD** | Consultant Dermatologist
11:15 - 11:30	**PRP Emerging Role in Acne Scars** **Soha Khan MD** | Consultant Dermatologist
11:30 - 11:45	**Role of Cryotherapy in Symptomatic Relief of Patients with Inflammatory Dermatoses** **Nivvedhetha S. MD** | Senior Resident

DAY THREE THURSDAY

7th March 2024

CONFERENCE HALL 1

DERMATOLOGY SCIENCES & RESEARCH

11:45 - 12:00	**New Concept of Comprehensive Antiaging Therapy** **Safwan Aladwan MD** | Consultant Dermatology and Venereology
12:00 - 12:15	**Oral Facial Digital Syndrome – A Case Report in An Indian Child** **Sanjanaa Srinivasa MD** | Post Graduate
12:15 - 12:30	**Dermoscopic Characteristics of Clinical Variants of Porokeratosis** **Fida Anjum MD** | Resident Dermatologist
12:30 - 12:45	**Infantile Pustular Psoriasis: A Red Flag to Underlying Autoinflammatory Syndromes** **Abeer Elkholy MD** | Professor of Dermatology
12:45 - 13:00	**Recalcitrant Dermatophytosis: Focused and Firm Therapy with Novel Topical Formulation** **Usman Shahid MD** | Resident Physician
13:00 - 14:00	**Q & A / Lunch Break**

Session 10
Chairperson: Fatma Almadani MD, Hala AlJaber MD

14:00 - 14:15	**Efficacy and Safety of Sertaconazole in Patients with Cutaneous Dermatophytosis** **Ayesha Abrar MD** | Resident Dermatology
14:15 - 14:30	**Exosomes Derived from Adipose Tissue-derived Mesenchymal Stem Cells (Asce) for the Treatment of Dupilumab-related Facial Redness in Patients with Atopic Dermatitis: A Report of Two Cases** **Byongseong Cho MD** | CEO and CTO
14:30 - 14:45	**A Study of Skin Aging and Skin Regeneration in an Ex Vivo Human Skin Model** **Da Yeong Nam** | Senior Research Engineer
14:45 - 15:00	**Drug Patch Testing in Severe Cutaneous Adverse Drug Reactions** **Dulini Liyanagama MD** | Consultant Dermatologist
15:00 - 15:15	**Systemic Retinoids in Wart Treatment** **Esraa Elhawary MD** | Lecturer of Dermatology and Venereology
15:15 - 15:30	**Hyperpigmentation: Treatment Strategy in Asian Skin** **Tatyana Vinnik MD** | Assistant Professor & Chief Physician
15:30 - 16:00	**Q & A / Break**

DAY THREE THURSDAY

7th March 2024

CONFERENCE HALL 1

DERMATOLOGY SCIENCES & RESEARCH

Session 11

Chairperson: Wedad Abdelrahman MD, Hani Sakla MD

16:00 - 16:15	**Interleukin 9 in Oral Lichen Planus: An Immunohistochemical study before and after Treatment by Intralesional Steroid Injection** **Mohamed ElGhareeb ElGanainy MD** | Assistant Professor of Dermatology
16:15 - 16:30	**The value of Real time PCR and High-Resolution Ultrasound in Diagnosis of Suspected Pure Neural Leprosy** **Mohammad A. Rashed MD** | Dermatologist
16:30 - 16:45	**Advancements in Nail Disease Management: A Multidisciplinary Approach** **Faiez Ghanam MD** | Dermatologist
16:45 - 17:00	**Henoch-Schönlein Purpura and Systemic Association in Children** **Viola Elvia Sequeira MD** | Post Graduate Resident
17:00 - 17:15	**Blistering Rash in a Child** **Wedad Abdelrahman MD** | Consultant Dermatologist
17:15 - 17:30	**Skin, The Longevity Concept and Supplementation; Where Are We and Integrating into Holistic Practice** **Jigna Patel MD** | Aesthetic Clinician and Owner

DAY THREE THURSDAY

7th March 2024

CONFERENCE HALL 2

THERAPEUTICS/NEW DRUGS /CASE PRESENTATIONS

Session 11: Case Presentation Open Category 1

Chairpersons:
Zbigniew Ruszczak MD | Chairman, International Clinical Case & Poster Presentation & Competition
Shaden Abdelhadi MD | Co-Chairman, International Clinical Case & Poster Presentation and Competition
Mohammed El Banhawy MD | Senior Consultant Dermatologist

09:00 - 09:10 **Butterfly Sign: Another Butterfly in Dermatology**
Thaer Douri MD | Dermatologist

09:10 - 09:20 **Birt-hogg-dube Syndrome: A Rare Genodermatosis Treated with Exosomes**
Elina Theodorakopoulou MD | Specialist in Dermatology

09:20 - 09:30 **Scar Prevention with Exosomes after a Facial Dog Bite Lip Injury: Case Study**
Shanthala Shivananjappa MD | Founder & CEO

09:30 - 09:40 **My Clinical Practices and Experiences of Using AMT (Autologous Micrografting Technology) in Hair Restoration for both Male Pattern Hair Loss (MPHL) AGA and Female Pattern Hair Loss (FPHL)**
Kelvin Chee Ling Tan MD | Medical Director

09:40 - 09:50 **A Case of Bacillary Angiomatosis Successfully Treated With Doxycycline And Erythromycin - Ethiopia**
Fuad Temam Awel MD | MD, dermatovenereology and dermatopathology

09:50 - 10:00 **Ulcerative Colitis Flare Post Isotretinoin: A Case Report**
Maha AlHussein | Senior Medical Student

10:00 - 10:10 **Eight Cases with Distinctive Clinical Presentations**
Ameer Mushtak MD | private clinic

10:10 - 10:20 **Cowden Syndrome Patient with Unusual Gene Mutation and Lymphatic Malformation**
Fatma Al Hosni MD | Specialist Dermatologist

10:20 - 10:30 **Epidermolysis Bullosa Dystrophica**
Shafia Mudassir MD | Consultant Dermatologist

10:30 - 11:00 Q & A / Break

DAY THREE THURSDAY

7th March 2024

CONFERENCE HALL 2

THERAPEUTICS/NEW DRUGS /CASE PRESENTATIONS

Session 12: Case Presentation Open Category 2

Chairpersons:
Zbigniew Ruszczak MD | Chairman, International Clinical Case & Poster Presentation & Competition
Shaden Abdelhadi MD | Co-Chairman, International Clinical Case & Poster Presentation and Competition
Mohammed El Banhawy MD | Senior Consultant Dermatologist

11:00 - 11:10 **Protocols of Injection of New Collagen for Skin Biostimulation**
Chiara Stocco MD | Plastic Surgeon

11:10 - 11:20 **The Use of Skin Microneedling for Melasma in Skin of Color**
Gelila Teshome MD | Medical Doctor

11:20 - 11:30 **Jellyfish Dermatitis Case Reported**
Mohammed AlMalmi MD | Dermatologist Physician Specialist

11:30 - 11:40 **Case Report, Juvenile Hyaline Fibromatosis**
Ronak Ahmed MD | Dermatology Specialist

11:40 - 11:50 **Cicatricial Alopecia in Paediatric Population**
Sanjana Mathew MD | Resident

11:50 - 12:00 **Palmoplantar Keratoderma: a Diagnostic Challenge**
Ahmed Fayad MD | Specialist of Dermatology and Venereology

12:00 - 12:10 **Immunoglobulin Therapy in Staphylococcal Scalded Skin Syndrome**
Apeksha Shyamalie Dissanayake Perera MD | Acting Consultant Dermatologist

12:10 - 12:20 **Unexpected Diagnosis of Facial Erythematous Papules**
Ahmed Zidan MD | Dermatology and Andrology Specialist

12:20 - 12:30 **Unveiling the Misdiagnosis: A 22-Year Journey from Chronic Plaque Psoriasis to Pityriasis Rubra Pilaris - A Compelling Case Report**
Chiranjaya Ekanayake MD | Registrar In Dermatology

12:30 - 12:40 **CHILLS and WHEALS**
Jaswandi Shirodkar MD | Resident Doctor

12:40 - 12:50 **Successful Use of Colchicine in The Treatment of Dissecting Cellulitis of The Scalp - A Case Report**
Amel Elsewh MD | Consultant dermatologist

12:50 - 13:00 **Q & A**

DAY THREE THURSDAY

7th March 2024

CONFERENCE HALL 2

THERAPEUTICS/NEW DRUGS /CASE PRESENTATIONS

13:00 - 14:00	**Lunch Break**

Session 13: Case Presentation Open Category 3

Chairpersons:
Zbigniew Ruszczak MD | Chairman, International Clinical Case & Poster Presentation & Competition
Shaden Abdelhadi MD | Co-Chairman, International Clinical Case & Poster Presentation and Competition
Mohammed El Banhawy MD | Senior Consultant Dermatologist

14:00 - 14:10	**Intralesional Triamcinolone Acetonide in Hidradenitis Suppurativa** **Vani Veggalam MD** | Senior Consultant Dermatologist
14:10 - 14:20	**Male Breast Cancer: Three Cases with Different Clinical Features** **Mihoub Bourakba MD** | Specialist Dermatology
14:20 - 14:30	**A Complicated Case of Nasal Filler Injection** **Natalia Imaeva MD** | Dermatologist-Cosmetologist and Associate Professor
14:30 - 14:40	**Is Erbium-YAG Laser Efficient to Treat Morbus Darier?** **Qasim Abu Elrub MD** | CEO, Medical Director and Dermatologist
14:40 - 15:30	**International Clinical Poster Presentation and Competition - Poster Viewing Session Meet the Authors & Discuss with the Jurors**
15:30 - 15:40	**Q & A / Break**

Session 14: JURY MEETINGS & AWARD CEREMONY

15:40 - 16:10	**Jury Meeting - Digital Poster Award Discussion**
16:10 - 16:40	**Jury Meeting - Clinical Case Presentation Award Discussion**
16:40 - 16:55	**Administrative Brake**
16:55 - 17:35	**Award Ceremony and Closing Remarks**

DAY THREE THURSDAY

7th March 2024

CONFERENCE HALL 3

COSMETIC & SURGICAL DERMATOLOGY

Session 9

Chairperson: Khaled Gharib MD, Sameer Al Ali MD

08:30 - 08:45	**The Use of Fractional Plasma for Periorbital Rejuvenation and Associated Combined Therapy** **Stefan Lipp MD** | Executive Director and CMO
08:45 - 09:00	**A New Combination of Wavelengths for the Treatment of Scars** **Paolo Bonan MD** | Professor of Dermatology
09:00 - 09:15	**Uses of Dermoscopy in Laser Medicine** **Karim Magdi Gabr MD** | German Board-certified Dermatologist
09:15 - 09:30	**Photobooster for Vascular Disease** **Sang Ju Lee MD** | Director
09:30 - 09:45	**EBDs For Face Contouring** **David Pudukadan MD** | Professor
09:45 - 10:00	**Picosecond Laser: Beyond Tattoo Removal** **Achraf Ellouadghiri MD** | Founder, Consultant and an Educator
10:00 - 10:15	**At The Edge of Meso-toxin And Biorevitalisation: Combination of Botulinic Neuroprotein with Ha and Amino Acids in One Syringe:** **Evgeniya Shelemba MD** | Dermatologist
10:15 - 10:30	**Skin Priming, A New Regenerative Concept, to Enhance Calcium Hydroxyapatite Skin Response Via Adding a Poly-revitalizing Complex: A Clinical, Ultrasound and Imaging Study** **Elina Theodorakopoulou MD** | Specialist in Dermatology
10:30 - 10:45	**Mesotherapy Cocktails: Ready Made Versus Mixing in Clinic** **Philippe Hamida-Pisal MD** | President of the Society of Mesotherapy of the United Kingdom
10:45 - 11:00	**Q & A / Break**

Session 10

Chairperson: Yusra Al Ali MD, Mohammed Reda Mostafa MD

11:00 - 11:15	**Dermal Boosters: How To Choose?** **Ahmed Alqahtani MD** | Assistant Professor

DAY THREE THURSDAY

7th March 2024

CONFERENCE HALL 3

COSMETIC & SURGICAL DERMATOLOGY

11:15 – 11:30	**Hyaluronic Acid in Aesthetic Neurology: Opportunities and Prospects** **Liudmila Soboleva MD** | Dermatologist, Aesthetic Medicine Doctor
11:30 – 11:45	**Slim Face-what Is Better for Correction** **Elena Belisheva MD** | Dermatologist & CEO
11:45 - 12:00	**PRP for Treatment of Androgenetic Alopecia: Which Clinical Effects Can We Expect and How Satisfied Are Male/Female Patients and Clinicians?** **Hanno Pototschnig MD** | Medical Doctor
12:00 - 12:15	**Side Effects and Complications of Fat Dissolving Injections: A Comprehensive Review and How to Prevent Them** **Arturo Almeida MD** | Medical Director & Global Trainer
12:15 - 12:30	**Management of Delayed Skin Necrosis Following Hyaluronic Acid Filler Injection Using Pulsed Hyaluronidase** **Ashish Chauhan MD** | Founder, Director & Consultant
12:30 - 12:45	**A New Term in Aesthetic Medicine "The Dancing Chin"** **Ibrahim El Achkar MD** | ENT, Aesthetics and Plastic Surgeon
12:45 - 14:00	**Q & A / Lunch Break**

Session 11

Chairperson: Omar Al Shaikh MD , Kamal Shakhra MD

14:00 - 14:15	**Nano Fat Injection for Periorbital Dark Pigmentation** **Aasem Albytu MD** | Head of Plastic and Reconstructive surgery
14:15 - 14:30	**Modern Concept of Rejuvenation Through Biomodulation** **Roberto Amore MD** | Professor of Dermatology
14:30 - 14:45	**MidMedial-Deep Volumisation Technique - Anatomical and Practical Apporoach to the MidFacial Harmonisation** **Sabuhi ABILOV MD** | Owner/Founder and Head Doctor
14:45 - 15:00	**How to Remove Your Permanent Filler** **Ayoud TOUMI MD** | Plastic Surgeon
15:00 - 15:15	**Post-surgery Scars Success is Based on Strong Collaboration Between the Plastic Surgeon and The Dermatologist. Tips and Tricks to Achieve a Seamless Scar** **Dora Evangelidou MD** | Consultant Plastic and Reconstructive Surgeon

DAY THREE THURSDAY

7th March 2024

CONFERENCE HALL 3

COSMETIC & SURGICAL DERMATOLOGY

15:15 - 15:30	**The New Face of Masculinity: Cosmetic Medicine for Men** **Duaa Abdulmohsen Mohamed MD** | Specialist Dermatologist
15:30 - 15:45	**Enhancing Facial Aesthetics: Combining VASER Liposuction and Renuvion for Double Chin Contouring** **Maria Rubatti MD** | Head of Plastic Surgery Department
15:45 - 16:00	**Q & A / Break**

Session 12
Chairperson: Harb Al Omari MD, Nemat Alsaghir MD

16:00 - 16:15	**The Role of Platelet Rich Plasma in Face Contouring & Jaw-line Definition** **Noura Lebbar MD** | Cosmetic Surgeon
16:15 - 16:30	**Laser Assisted Drug Delivery** **Ahmed Sami Abouroab MD** | Specialist Dermatologist
16:30 - 16:45	**Eye Thread Lifter** **Dalia Ata MD** | Dermatologist & cosmatologist
16:45 - 17:00	**Correction Of the Marionette Lines in The Face with The Combined Usage of Thread Methods and Fat Grafting** **Irada Huseynova MD** | Plastic Surgeon
17:00 - 17:15	**Perfecting the Patient Journey** **Nisha Menon MD** | Aesthetic Doctor
17:15 - 17:30	**Adipose Stem Cell Exosome (ASCE): Next Generation Regenerative Therapeutics for Atopic Dermatitis** **Byongseong Cho MD** | CEO and CTO
17:30 - 17:45	**A Systematic Investigation of The Importance of PH Regulation in Skin Through Varied Interventional Procedures** **Ahmad Nazari MD** | Aesthetic Trainer
17:45 – 18:00	**Five-point Liquid Rhinoplasty: Results from A Retrospective Analysis of a Novel Standardized Technique and Considerations on Safety** **Leonard Nenad Josipovic MD** | Aesthetic and Cosmetic Surgeon

DAY THREE THURSDAY

7th March 2024

CONFERENCE HALL 4

ASSOCIATION PROGRAM

Session 11: Bahrain Dermatology Association Session

Chairperson: Zainab Almossali MD

08:30 - 08:45 **Patch testing in Cutaneous Adverse Drug Reactions: Methodology, Interpretation, and Clinical Relevance in a Nutshell**
Zainab Almossalli MD | Dermatology Consultant

08:45 - 09:00 **Lessons learnt from Case Reports**
Fatema Khamdan MD | Assistant Professor, Consultant Dermatologist and Dermatopathologist

09:00 - 09:15 **Food and Aeroallergens Testing: What Dermatologist Need/Don't Need to Know!**
Zainab Almossalli MD | Dermatology Consultant

09:15 - 09:30 **Treatment Options for Pregnant Women Living with Severe Skin Conditions Case Based Discussion**
Fatema Khamdan MD | Assistant Professor, Consultant Dermatologist and Dermatopathologist

Session 12: Syrian Arab Society of Dermatology Session

Chairperson: Samir Almahfoud MD, Fouz Hassan MD

09:30 - 09:50 **PUsing Botox as an Adjunct in the Treatment for Migraine**
Samir Almahfoud MD | Consultant Dermatologist and president of the Syrian Arab Society of Dermatology
Diana Sarkis MD | Resident Dermatologist

09:50 - 10:10 **Complication of Permanent Fillers, Classification and Management**
Wael Albarazi MD | Head of the Plastic, Reconstructive and Burns Department

10:10 - 10:25 **Cotton with Alcohol as a Diagnostic and Therapeutic Tool: 12 Cases of Neglecta Dermatitis and Terra Firma form TFFD with this Easy Cheap Tool**
Thaer Douri MD | Dermatologist and a Lecturer at the Faculty of Medicine

10:25 - 10:45 **LASER: Summaries and Updates**
Wahiba Suliman MD | Member of the Administrative Board

10:45 - 11:00 Q & A / Break

11:00 - 11:15 **Critical Cases of Leishmaniasis**
Muhammad Rabie Katta MD | Vice President
Julnar Hanna MD | Dermatologist

DAY THREE THURSDAY

7th March 2024

CONFERENCE HALL 4

ASSOCIATION PROGRAM

11:15 - 11:30 **Up-to-date in Prurigo Nodularis**
Lina Al Soufi MD | Head of Department of Dermatology

11:30 - 11:45 **Clinical Cases**
Fouz Hassan MD | Head of the Department of Dermatology and Venereology

11:45 - 12:00 **Clinical Cases**
Sdrah Diab MD | Dermatology Resident

12:00 - 12:15 **Case Studies in Practice: Insights from Tishreen University Hospital**
Dyala Lutfi Sayed Ahmad MD | Dermatology Resident

Session 13: Sudanese Association of Dermatologist (SAD) Session

Chairperson: Bakri Al Agraa MD

12:15 - 12:40 **Clinical Picture of Vitiligo in Children**
Mahdi Shamad MD | Associate Professor and Dean

amiea med

EXCEED
YOUR EXPECTATIONS

Outstanding quality in medical skin treatment

BEST

Visit us at the
Dubai Derma.
05.–07. March 2024

ABSTRACTS

Tuesday| 5 MARCH 2024

DAY ONE

CONFERENCE HALLS

1 | 2 | 3 |4

DAY ONE TUESDAY

5th March 2024

CONFERENCE HALL 1

DERMATOLOGY SCIENCES & RESEARCH

Session 1

Chairperson: Hesham Zaher MD, Mohsen Saleh Bin Rasheed MD

09:30 - 10:00

Pain Assessment in Dermatology

Jacek C. Szepietowski MD | Chair of the Department of Dermatology, Venereology and Allergology

Itch is the most frequently observed subjective symptom in dermatology. However, recent data suggest that cutaneous pain is not an uncommon phenomenon in various dermatoses, especially those of inflammatory background. Pain can be classified as nociceptive pain, neuropathic pain and mixt pain. Another classification divides pain into somatic pain, visceral pain and neuropathic pain. Pain in dermatoses fulfills criteria for nociceptive and somatic pain. Pain assessment is a challenge for clinicians and patients. The purpose of pain intensity assessment is important in selection of adequate methodology. The method should be well-developed and validated. Various dimensions of pain assessment should be taken into consideration, including assessment according to symptom duration, according to distribution (localized or generalized) and according to intensity. For daily clinical practice one may recommend the simple instruments, which usage is not time consuming, and the results are reliable. Usually the worst pain (W-Pain) is assessed, as we are human beings and we better remember the extremes. It is important to consider the reliable recall period to limit the eventual bias of the obtained results. Numeral Rating Scale (NRS) is the most frequently used instrument. One can also suggest to employ questionnaires, like McGill Pain Questionnaire or Chronic Pain Assessment Questionnaire. As neuropathic component can occur in such skin conditions like atopic dermatitis or hidradenitis suppurativa Douleur Neuropathique–4 questions (DN4) questionnaire can also be a useful tool.Emotional functioning scales, including Beck Depression Inventory or Hospital Anxiety and Depression Scale (HADS) may be of help in the holitic assessment of cutaneous pain.

10:00 - 10:30

Thalidomide in Dermatology. Revisited

Mohammed El Banhawy MD | Senior Consultant Dermatologist

Thalidomide has proven to be an effective medication in treating several severe dermatologic disorders. The presentation will focus on the pharmacokinetics, mechanism of action, side effects, monitoring, and the dermatologic indications of thalidomide.

10:30 - 11:00

Application of Mild Local Hyperthermia for Mucocutaneous HPV Infections

Xinghua Gao MD | Professor, Chair of Dermatology and Deputy Director

Hyperthermia can be deliberately induced using drugs or medical devices, either locally or systematically. Skin is an easy organ to receive manipulated local hyperthermia. It has been tested that the pain limit temperature of skin is about 45 °C. It appears that skin cells of different origin have different degree of tolerance to hyperthermia. Fever-range temperature at 39-41C can modulate the activities of antigen presenting cells, T cells and NK cells; heat shock temperature at 41-45C can elevate the immunogenicity of cells. Most of the current options for

DAY ONE TUESDAY
5th March 2024

CONFERENCE HALL 1
DERMATOLOGY SCIENCES & RESEARCH

mucocutaneous warts are ablative. By using a controlled local hyperthermia technique at 44C for 30 min on warty lesions in a defined protocol, we noticed around 50% cutaneous warts were cleared 3 months after the treatment. In cases of multiple warts, treatment on a single lesion usually leads to clearance of untreated ones. The technique is appealing in cases of multiple, extensive warts associated with pregnancy, diabetes mellitus, or of cosmetic concerns. Side effects are minor. A preliminary study showed that local hyperthermia is also promising for cervical high risk HPV infection.

11:00 - 11:30

Oral Agents in Melasma
Rashmi Sarkar MD | Director -Professor,Dept of Dermatology

Melasma is a common facial pigmentary disorder that is difficult to treat. It is more commonly seen in women and in dark-skinned races.It is a common pigmentary disorder among Asians, Africans and Hispanics. The accurate etiopathogenesis is not known. Recently, melasma is no longer regarded as a purely pigmentary disorder but rather a phenotype of photoaging disorder. The vascular etiology is also an important target for melasma. Systemic agents are required for treatment of melasma as topical treatment has to be given repeatedly for management of melasma and it is also a recalcitrant disorder. Topical agents also have side effects. Hence, tranexamic acid, melatonin,glutathione and pycnegenol and other agents can be possibly game changers in melasma.

11:30 - 11:45

Updates from Dermatology Journals
Ameen Alawadhi MD | Consultant Dermatologist and Dermatopathologist, Head of Dermatology and Chairperson of Internal Medicine Department

The talk will be a review of the most important and interesting articles that came out in major dermatology journals over the past 12 months.

Will review recently advances and Therapeutics and guidelines on major skin disorders.

11:45 - 12:00

Management of Pustular Psoriasis
Fouad El Sayed MD | Professor and Head of Dermatology, Lebanese University

Pustular psoriasis (PPsO) defines a heterogeneous group of skin inflammatory diseases, which have in common the presence of aseptic pustules. Clinical presentation of pustular PsO includes a variety of subtypes as palmoplantar pustular PsO, acrodermatitis continua, generalized pustular PsO, pustular PsO of pregnancy, paradoxical pustular PsO. Genetically distinct from psoriasis vulgaris, they have been shown to be related to mutations in any of 3 genes of the skin immune system, respectively called IL36RN, CARD14 and AP1S3. These recent advances have initiated the design of biological drugs specifically targeting key actors of inflammation in pustular psoriasis, with interleukin-36 inhibitors as the most advanced example of therapeutic development.

DAY ONE TUESDAY

5th March 2024

CONFERENCE HALL 1

DERMATOLOGY SCIENCES & RESEARCH

12:00 - 12:15

Estimation of Tissue Level of Human Beta-defensin 1 (Hbd-1) in Vitiligo Before and After Narrowband Ultraviolet B Phototherapy: A Case-control Study

Hesham Zaher MD | Emeritus Professor of Dermatology

Introduction: Vitiligo is an autoimmune cutaneous disease with multifactorial polygenic and complex pathogenesis and its precise etiology warrants more studies for the scrutiny of its exact pathogenesis. Human beta-defensin 1 (HBD-1) is one of the antimicrobial peptides (AMPs) which is thought to play a role together with its gene polymorphism in vitiligo pathogenesis.

Objectives: The goal of this study was to assess the tissue level of HBD-1 in vitiligo patients in comparison to its level in healthy controls to verify its role in the pathogenesis of vitiligo.

Materials and Method: This case-control study included 25 non-segmental vitiligo patients as well as 25 sex- and age-matched healthy controls. Patients were subjected to a full assessment of their vitiligo through different scores including vitiligo area scoring index (VASI), vitiligo disease activity (VIDA), vitiligo extent score (VES), and body surface area (BSA). Narrowband ultraviolet B (NBUVB) was applied three times/week for 12 weeks. Skin biopsies were taken from vitiligo patients (before and after phototherapy) and healthy controls to determine the expression of HBD-1 by ELISA.

Results: A statistically significant difference was shown between tissue levels of HBD-1 in vitiligo patients and controls ($P<0.001$) with lower levels of HBD-1 in vitiligo patients (either before or after treatment). Also, a statistically significant increase of HBD-1 was found after treatment by NBUVB.

Conclusions: HBD-1 is an antimicrobial peptide that is downregulated in vitiligo as a result of impaired keratinocyte function in vitiligo. Thus, shedding the light upon the further understanding of vitiligo pathogenesis and hence suggesting new therapeutic options. Also, a novel mechanism of action of NBUVB is proposed in vitiligo treatment through upregulation of lesional HBD-1 level.

12:15 - 12:30

Biofilms in Acne

Ramesh Bhat MD | Vice Dean and Professor of Dermatology

Acne vulgaris is a common problem encountered in our day-to-day practice. It's important to note that various antibiotics used in the management of acne are resistant against cutibacterium acnes. Biofilms is one of the mechanisms which is responsible for this issue. There are several components of Biofims with each of them of having different roles in the evolution, progression of biofilms. There are several methods to study the mechanism by which biofilms are formed. We have studied antibiogram of C. acnes and assessed its relation with formation of Biofims.

DAY ONE TUESDAY

5th March 2024

CONFERENCE HALL 1

DERMATOLOGY SCIENCES & RESEARCH

12:30 - 13:00

Problematic Pigmented Skin Lesions: Ways to Overcome

Shady Mahmoud MD | Professor of Dermatology & Venereology

Melasma is a highly prevalent and cosmetically disfiguring pigmented skin disease. The post-treatment results are often unsatisfactory. Many clinical trials have tried to prove the effectiveness of the different treatment modalities, but the results have been indeterminate.

Strict sun protection, concomitant use of bleaching agents, and maintenance treatments are necessary. Commonly used lasers include the low-fluence 1064-nm Q-switched NdYAG laser, nonablative fractionated lasers, and intense pulsed light. A variety of other treatments that may also help to improve results are now being more widely adopted, including oral tranexamic acid, newcomer wavelengths, pulsed dye laser, new depigmenting topical cream, and laser-assisted drug delivery. Special care should be taken during laser treatment of melasma to avoid any aggravation or post inflammatory hyperpigmentation that could occur due to improper treatment, preparation, and post operative care.

13:00 - 14:00 **Q & A / Lunch Break**

Session 2

Chairperson: Abdul Wahab Al Fouzan MD, Muna Al Murrawi MD, Assem Farag MD

14:00 - 14:30

Science at The Forefront: Advancing Management of Inflammatory Acne

Brigitte Dreno MD | Professor of Dermatology, Chairman of the Department of Dermato-Oncology and Director of the GMP Unit

Acne affects more than 640 million people worldwide, including about 85% of adolescents. This inflammatory dermatosis affects the entire population, from teenagers to adults, which reinforces the need to investigate it. Furthermore, acne has serious consequences, including a psychological impact, low self-esteem, social isolation, and depression. Over the last years, the understanding of acne pathophysiology has improved. The aim of this talk is to make a review of the most recent scientific data about the mechanisms of development of inflammatory acne lesions and the newly therapeutic approaches.

The role of Cutibacterium acnes (C. acnes) and the microbiome in the pathophysiology of acne has recently undergone a paradigm shift: rather than C. acnes hyperproliferation, it is the loss of balance between the different C. acnes phylotypes, together with a dysbiosis of the skin microbiome, which results in inflammatory acne development. The loss of diversity of C. acnes phylotypes acts as a trigger for innate immune system activation, leading to cutaneous inflammation. A predominance of C. acnes phylotype IA1 has been observed, with a more virulent profile in acne than in normal skin. The role of sebaceous gland appears more and more crucial both in the development of dysbiosis and the activation of virulent genes of C acnes and among them CAMP, IL1Y and IL17A. In addition, recently it has been shown that C. acnes interacts with the keratinocytes of the follicle and the other bacteria by secreting a biofilm and Extra Vesicles (EVs) which modulate both the inflammation and development of bacterial resistance.

Other bacteria, mainly Staphylococcus epidermis (S. epidermis), are also implicated in acne and interact with C. acnes playing a critical role for the regulation of skin homeostasis.

DAY ONE TUESDAY
5th March 2024

CONFERENCE HALL 1
DERMATOLOGY SCIENCES & RESEARCH

The new understanding of acne pathophysiology has prompted a change in direction for acne treatment. In the future, the development of individualized acne therapies will allow targeting of the pathogenic strains, leaving the commensal strains intact. Thus, biofilm and the cytokine IL17A are recent targets. Therapeutic innovations have been recently developed, including pre/probiotics, postbiotics.

14:30 - 15:00

The Latest Breakthrough in Sun Protection
Eggert Stockfleth MD | Professor of Dermatology & Head of Skin Cancer Center

Excessive sun exposure leads to skin changes, especially due to UV radiation.

The UV risk is associated with the formation of DNA damage, especially pyrimidine dimers or cyclobutane pyrimidine dimers (CPDs).

There is also damage to the extracellular matrix and the cells, such as the induction of oxidative stress, changes in antioxidant protection such as catalase and the breakdown of collagen/elastic fibres through the induction of matrix metalloproteinases (MMPs).

Acute effects include erythema, pigmentation, apoptosis and gene mutation, while chronic exposure is associated with photoageing, immunosuppression, photodermatosis and skin cancer.

The harmful effects of solar radiation are also caused by visible light, especially blue light and infrared light.

These rays have been shown to induce oxidative stress in macromolecules and aggravate photodermatoses.

It has therefore been proven that the skin needs balanced protection across the entire spectrum of sunlight.

Today, sun protection is an important public health issue in order to prevent sun damage.

Sun filters are used to absorb and/or reflect UVB and UVA rays.

They are available on the market with different sun protection factors (SPF), and around 30 sun filters are authorised in Europe, including mineral substances such as titanium dioxide and organic sunscreens such as Tinosorb® S.

Today, it is clear that we need to find innovative and effective sun filters that protect the skin from UV radiation, but also beyond that in the visible and infrared spectral range, without any biological risks for customers and ecosystems.

The aim of our work was therefore to develop a new generation of sun filters with broad-spectrum light protection, which we called TriAsorB.

15:00 - 15:30

Revolutionizing Care and Learning: New Paradigms in Psoriasis Therapies and Education
Darrell S. Rigel MD | Dermatologist and Clinical Professor of Dermatology
April Armstrong MD | Professor and Chief of Dermatology

In this presentation, Professors Darrell Rigel and April Armstrong will introduce a new paradigm in dermatological learning, where complex topics are taught in an intuitive, systematic fashion to facilitate efficient learning.

DAY ONE TUESDAY
5th March 2024

CONFERENCE HALL 1
DERMATOLOGY SCIENCES & RESEARCH

Professor Armstrong will then navigate recent advancements in treating plaque psoriasis, providing a critical examination of topical, oral, and biologic therapies. The discussion starts with an introduction to novel topical agents, spotlighting how they complement existing topical therapy landscape. The presenters will then provide an analysis of contemporary oral therapies, offering insights into their potential impact on treatment outcomes. The discourse then guides the audience through the current status and future trajectories of biologics, emphasizing their evolving role in the management of plaque psoriasis. Additionally, we will delve into the promising domain of IL36R inhibitors, concentrating specifically on their application in generalized pustular psoriasis (GPP). Through a critical evaluation of these diverse therapeutic modalities, the presentation will provide attendees with an essential understanding of current and forthcoming strategies for effectively treating plaque psoriasis.

15:30 - 15:45

Discussion

15:45 - 16:00 **Q & A / Break**

Session 3
Chairperson: Dominique du Crest, Sonja Sattler MD

SKIN & DIGITAL SUMMIT/DIGITAL STARTUP CORNER

16:05 - 16:20

Artificial Intelligence: Where Are We & Where Are We Heading?
Diala Haykal MD | Cosmetic and Laser Doctor

Artificial Intelligence (AI) is poised to revolutionize the healthcare industry, offering unprecedented opportunities to improve patient care, streamline processes, and advance medical research. Over the past decade, AI has made significant strides in healthcare, from assisting in diagnosis and treatment to optimizing resource allocation and predicting patient outcomes. As the capabilities of AI continue to evolve, it raises critical questions about the current state of AI in healthcare and where we are headed in the future.

AI has emerged as a transformative force in healthcare, promising to enhance diagnosis, treatment, and patient outcomes while optimizing operational efficiency and driving innovation. This abstract examines the current landscape of AI in healthcare, highlighting its applications, challenges, and implications. It also explores future trends and potential directions for AI in healthcare, offering insights into how this technology will continue to shape the future of medicine.

DAY ONE TUESDAY

5th March 2024

CONFERENCE HALL 1

DERMATOLOGY SCIENCES & RESEARCH

16:20 – 16:50

AI Assistance in Aesthetic Medicine - Introducing the Facial Attractiveness Index (FAI)

Sonja Sattler MD | Dermatologist, Aesthetic Physician and CEO

Background: According to the WHO, health is defined as a state of complete health and not merely the absence of disease or infirmity. Aesthetic medicine has been shown to address all of the three aspects of complete health – physical, mental and social well-being – with both surgical and non-surgical procedures. However, the assessment of individual patient's need is based on the individual experience of the health care provider (HCP). Furthermore, it will sometimes be influenced by available or preferred treatment options.

Objective: To standardize the assessment of the aesthetic patient in an objective and transparent manner.

Methods: An assessment tool was created by analyzing >200 original and derived facial variables in >15 facial regions via AI technique. The characteristic features found were validated using digital images and live assessments as well. The variables were summarized into common landmarks of clinical facial signs leading finally to a facial aesthetic index (FAI) and a facial youth index.

Results: This detailed facial analysis of multiple landmarks e.g. frontal, periorbital, and perioral wrinkles, nasolabial and melomental folds, cheek volume, skin color, regional asymmetry, etc., lead to a trustworthy FAI and facial youth index. In addition, the device supports the physician with data regards primary treatment options, prevention of overcorrection and monitoring of treatment outcomes.

Discussion: Current methods for assessing facial appearance, attractiveness and youthfulness are mainly done by subjective evaluation. The Ai based device was developed to assess objectively the total facial impression and single landmarks. This novel AI-based algorithms are age adjusted, gender and ethnicity specific; they will help to standardize the patient assessment as well as to find the best individualized treatment options.

16:50 – 17:05

Meet ANEEQ, the Platform that Makes it Easy for Men to Address their Health Concerns All from the Comfort and Privacy of their Homes

Antoine Pichery | CEO

As less than 10% of men aged between 20-40 are comfortable talking to their doctor about concerns such as hair loss, we are starting hard conversations and breaking open taboos. We are creating a seamless and educative platform making men's health discreet and effortless. We are building a one-stop-shop for men's health providing convenient & discreet solutions. Our platform offers access to prescription and non-prescription treatments for issues like hair loss, erectile dysfunction & skincare.

Join us for an insightful exploration into the dynamic intersection of technology, innovation, and men's dermatology as we delve into the transformative solutions offered by ANEEQ. The presentation, led by ANEEQ CEO, will unravel the pioneering strategies reshaping the landscape of men's health and dermatological wellness.

Discover how ANEEQ is revolutionizing the traditional approach to skincare and hair loss, going beyond surface-level concerns to address the broader spectrum of men's health. From cutting-edge technologies to personalized solutions, we will uncover the tools and methodologies employed by ANEEQ to empower confidence and redefine the skincare journey for men.

DAY ONE TUESDAY

5th March 2024

CONFERENCE HALL 1

DERMATOLOGY SCIENCES & RESEARCH

17:05 – 17:20

Ilik: Changing the Face of Dermatology

Dina Sidani | Founder and CEO

ilk is an asynchronous dermatology platform that offers personalized skincare treatments using powerful prescription-grade ingredients. Our dermatologists analyze a patient's skin via an online questionnaire and prescribe a custom treatment that is delivered to the patient's doorstep. We're on a mission to make the most effective skincare accessible to all.

This presentation will introduce ilik Health, a revolutionary platform that is reshaping the face of dermatology by placing the patient at its core. By focusing on common, chronic, and low-risk conditions, ilik aims to democratize access to effective skincare and dermatology services. Our proprietary technology streamlines administrative tasks, freeing dermatologists to concentrate on creating the best treatment plans. In this session, we will explore how ilik's innovative model enhances patient care, increases accessibility, and simplifies the work of dermatologists, ushering in a new era of patient-centric dermatology. Join us to discover how you can be part of this exciting transformation.

17:20 – 17:35

Misinformation and How Doctors on Social Media Can Help

Michael H. Gold MD | Owner, Medical Director

With the advent of social media and Artificial Intelligence (AI), becoming part of the "normal" world we live in now, it is important for dermatologists to understand the benefits of these platforms and the potential drawbacks that exist because of them. This presentation will show how both social media and AI can be used to help educate our patients and to disseminate information that is useful from a teaching point of view, but also highlight the problems associated with these platforms. Misinformation and disparaging information can be harmful and put patients at risk. We will delve into these systems and discuss ways that can make them work best for us and keep us at the forefront of the medical dermatological and aesthetic spectrum.

17:35 – 17:50

How to Build and Maintain Trust with Your Patients!

Mahran Ashour | Founder & Medical Director

The concept of trust is important in healthcare because health and healthcare in general involve an element of uncertainty and risk for the vulnerable patient who is reliant on the competence and intentions of the healthcare professional The Oxford English Dictionary defines trust as the "firm belief in the reliability, truth, or ability of someone or something

Healthcare professionals begin to gain patients' trust by being knowledgeable in their specific field of practice and, as a result, patients have confidence and feel secure in the advice provided.

High levels of trust have been associated with many benefits, including a perception of better care, greater acceptance to recommended treatment and adherence to that treatment, lower anxiety in relation to any treatment taken, and reportedly facilitates access to health services. Conclusion: After understanding & applying the steps in how to gain and maintain your patients trust, you will be able to build a strong database and great reputation for you and your practice.

DAY ONE TUESDAY

5th March 2024

CONFERENCE HALL 2

THERAPEUTICS/NEW DRUGS/CASE PRESENTATIONS

Session 1

Chairperson: Hussein Abdel Dayem MD, Makram Al Wais, Mohammed Al Abadie MD

09:30 - 09:55

JAK Inhibitors for Alopecia Areata

Hussein Abdel Dayem MD | Consultant Dermatologist

Alopecia areata (AA) is an immune mediated condition, clinically manifesting as non-cicatricial patches of alopecia. It is often a self-limiting condition; however, regrowth of hair can take a long period of time, resulting in significant psychological comorbidity. With the recent advances in pathomechanisms of AA, the therapeutic approach to the condition has become more specific, and targeted therapy with small molecules is probably the ideal intervention. Many therapies exist for AA, but none of the systemic agents were approved, until recently, when baricitinib (Janus kinase (JAK1 and JAK2 inhibitor) gained FDA approval for the treatment of adult patients with severe AA. The response achieved with JAKibs is not sustained after treatment discontinuation, with many studies showing a high recurrence rate with tofacitinib and ruxolitinib post treatment. Also, recent studies have hypothesized that JAK2, with its ubiquitous expression, can cause adverse effects, unlike JAK1, which is associated with multiple major cytokine receptor families and JAK3, which is exclusively associated with the Yc cytokine receptor. Thus, JAK3ibs may be associated with a better side effect profile and, in conjunction with their specificity, may replace other JAKibs as the treatment of choice for AA.

09:55 - 10:20

Update on Pathophysiology and Treatment of Chronic Hair fall

Salah Al Rubaie MD | Consultant Dermatologist

Hairfall is a common concern in dermatology clinics worldwide, affecting the QOL of both men and women.

Chronic hairfall may be due to many differnet causes and it is difficult to identify the causes for each patient. Hairfall can be due to many causes such as genetic factors, hormonal, stress, depression, childbirth and chemotherapy and hairstyles.

Treatment depends on the Type of alopecia or hairfall. The recent advances in understanding of the pathophysiology and development of new medications has improved the treatment of hair loss conditions.

Among the various treatments of Chronic hairfall are Minoxidil, Finasteride, Dutesteride and combination of oral Finasteride and topical Minoxidil and also Mesotherapy, PRP, Stemcell injections and Exosomes.

10:20 - 10:45

Current and Future Treatment for Vitiligo

Mohammed Al Abadie MD | Clinical Director & Consultant Dermatologist

Vitiligo is an idiopathic, acquired disorder characterised by well circumscribed milky white cutaneous macules and patches. It can affect up to 2% of a population. It is a multifactorial disorder which relates to genetics (up to 30%) and non-genetic factors The functional melanocytes disappear from the affected areas by an unidentified mechanism. There are many theories which may explain the pathogenesis. This to include Autoimmune, Neural, Oxidative Stress, Convergence, Genetics and others.There is no cure for vitiligo but there are many treatments which include topical therapy including

DAY ONE TUESDAY
5th March 2024

CONFERENCE HALL 2
THERAPEUTICS/NEW DRUGS/CASE PRESENTATIONS

steroid and calcineurin inhibitors as mono or combined therapy, Ultraviolet light both UVB and PUVA, surgical and others. Recent research concentrated on inhibiting and blocking immunological channels by biological and JAK inhibitors e.g. Ruxolitinib cream 1.5% (licensed) and Baricitinib (under research). On the other hand, Excimer laser 408nm, became an established effectives treatment for vitiligo. More recently the novel combination of Excimer laser and surgical needling technique showed superior results. (BinShakean and Al Abadie, J Clinical and Experimental Dermatol 2017; 42: 363-6)

10:45 - 11:30

Share Me Your Experience: 40 Clinical Cases
Khalifa Sharquie MD | Professor of Dermatology

In busy clinic, dermatologist see diverse cases, in most of them clinical diagnosis could be established and treatment might be given with or without further follow up.

Objective: To see cases where clinical diagnoses could not be well determined which might need specific investigations and follow up. But often these patients are not ready to do any investigations or refuse to come again for follow up for different reasons or patients with difficult diagnosis. In these cases dermatologists should be very clever to put provisional diagnosis and to give therapy. Share me your experience is the main aim of this presentation through interactive discussion

Patients and Results: Around forty unusual clinical slides will be presented that consist diverse cases of dermatology including patients that need surgery or cosmetology where rapid diagnosis and management are essentially needed. Interactive discussion is part of this presentation.

Conclusion: The dermatologist should be clever enough to deal with most cases without further investigations and follow up

11:30 - 12:00

Challenging Clinical Cases: Share Me Experiences
Khalil Alhamdi MD | Professor of Dermatology and Consultant Dermatologist

In daily clinical practice and an increasing number of problematic cases may be seen which is either a topical in presentation, site evolved, or age. In this study an interesting case will be presented.

DAY ONE TUESDAY

5th March 2024

CONFERENCE HALL 2

THERAPEUTICS/NEW DRUGS/CASE PRESENTATIONS

Session 2

Chairperson: Nawaf Al Mutairi MD, Reyad Mash'al MD

12:00 - 12:20

Cutaneous Leishmaniasis in Middle East: Cur-rent Scenario

Nawaf Al Mutairi MD | Professor and Head of The Department

A The leishmaniases are now endemic in 88 countries on five continents—Africa, Asia, Europe, North America and South America—with a total of 350 million people at risk. Seventy-two are developing countries and 13 are among the least developed. It is estimated that worldwide 12 million people are af-fected by leishmaniasis; this figure includes cases with overt disease and those with no apparent symptoms. Of the 1.5-2 million new cases of leishmaniasis estimated to occur annually, only 600 000 are officially declared.

Abstract Summary: Of the 500 000 new cases of visceral leishmaniasis which occur annually, 90% are in five countries: Bangladesh, Brazil, India, Nepal and Sudan. The number of annual deaths is about 80.000 worldwide. Ninety per-cent of all cases of mucocutaneous leishmaniasis occur in Bolivia, Brazil and Peru. Ninety percent of all cases of cutaneous leishmaniasis occur in Afghanistan, Brazil, Iran, Peru, Saudi Arabia and Syria, with 1-1.5 million new cases reported annually worldwide. The geographical distribution of leishmaniasis is limited by the distribution of the sand-fly, its susceptibility to cold climates and its and its tendency to take blood from humans or animals. However, with rapid globalization and easy means of transport available to-day, there has been huge increase in the transcontinental travel among the world pop-ulation. Hence, the cases are now being increasingly reported from areas or countries, in which the disease was non-existent in the past. Thus, there is a need to make the medical community aware of this disease across the world, so as to detect and treat the cases at the earliest. I would discuss the current situation of this infection in Middle East as well as give an update on the recent advances in the pathogenesis, diagnosis and treatment of this condition.

12:20 - 12:40

JAK Inhibitors: Small Molecules with Big Expectations

Isam Oumeish MD | Consultant Dermatology and Venereology and Laser

In busy clinic, dermatologist see diverse cases, in most of them clinical diagnosis could be established and treatment might be given with or without further follow up.

Objective: To see cases where clinical diagnoses could not be well determined which might need specific investigations and follow up. But often these patients are not ready to do any investigations or refuse to come again for follow up for different reasons or patients with difficult diagnosis. In these cases, dermatologists should be very clever to put provisional diagnosis and to give therapy. Share me your experience is the main aim of this presentation through interactive discussion

Patients and Results: Around forty unusual clinical slides will be presented that consist diverse cases of dermatology including patients that need surgery or cosmetology where rapid diagnosis and management are essentially needed. Interactive discussion is part of this presentation.

Conclusion: The dermatologist should be clever enough to deal with most cases without further investigations and follow up

DAY ONE TUESDAY

5th March 2024

CONFERENCE HALL 2

THERAPEUTICS/NEW DRUGS/CASE PRESENTATIONS

12:40 - 13:00

How to Maximize the Acne Scar Results with Exosomes & Energy Based Procedures: My Experience

Shanthala Shivananjappa MD | Founder & CEO

This abstract discusses the use of exosomes in combination with energy-based treatments, including subcision, for the treatment of difficult or severe acne scars. Acne scarring can be challenging to treat, particularly in patients with darker skin tones or underlying medical conditions that can impair skin healing. Exosomes, which are small vesicles released by cells, have shown promise in promoting wound healing and tissue regeneration. When used in combination with energy-based treatments such as subcision, laser therapy, and RF microneedling, exosomes can enhance the efficacy of these treatments and improve outcomes for patients with hard-to-treat acne scars. This abstract highlights the potential benefits of exosome therapy for the treatment of difficult or severe acne scarring and emphasizes the need for further research to fully explore the potential of this innovative approach.

Acne scars are a common skin condition that can cause significant emotional distress for patients. Traditional treatments, such as laser therapy, subcision, and RF microneedling, have shown varying levels of success in treating acne scars. However, emerging research on exosomes, small extracellular vesicles, suggests that they may have potential as an adjuvant therapy for these treatments. Difficult acne scarring can refer to scars that are challenging to treat and require more advanced or aggressive treatments. The type and severity of scarring, the patient's skin type and tone, and underlying medical conditions can all impact the difficulty of treating acne scars. Scars that are deep, irregular in shape, or associated with skin laxity or volume loss may require more advanced treatments. Patients with darker skin types or underlying medical conditions may also experience more challenges with acne scar treatment. It is important to work closely with a qualified dermatologist or cosmetic surgeon to develop a personalized treatment plan that addresses the unique needs and goals of each patient.

Exosomes have been shown to play a crucial role in tissue repair and regeneration by promoting angiogenesis, reducing inflammation, and enhancing collagen production. When used as an adjuvant therapy with laser, subcision, and RF microneedling, exosomes can help improve the outcomes of these treatments. Laser therapy is an effective treatment for acne scars, but it can cause adverse effects such as post-inflammatory hyperpigmentation and erythema. The use of exosomes as an adjuvant therapy can help reduce these side effects and promote faster healing. Subcision and RF microneedling are also effective treatments for acne scars, and when combined with exosomes, they can help promote collagen production and enhance the regenerative potential of the skin. In summary, exosomes have the potential to be an adjuvant therapy for laser, subcision, and RF microneedling for acne scars. This review provides an overview of the current state of exosome therapy for acne scars and their potential as an adjuvant therapy for traditional treatments. By utilizing these innovative treatments, patients with acne scars may experience significant improvement in the appearance and texture of their scars, leading to an improvement in their quality of life.

13:00 - 14:00 **Q & A / Lunch Break**

DAY ONE TUESDAY

5th March 2024

CONFERENCE HALL 2

THERAPEUTICS/NEW DRUGS/CASE PRESENTATIONS

Session 3

Chairperson: Khalil Alhamdi MD, Hazem Seif El Nasr MD

14:00 - 14:30

Advances in the Treatment of Acne. Light and Laser Devices

Jose Luis López-Estebaranz MD | Professor of Dermatology

Acne vulgaris is a prevalent condition mostly affecting adolescents and young adults. For some patients, acne continues to be a problem beyond adolescence, persisting well into adulthood. Studies on the psychosocial impact of acne have documented dissatisfaction with appearance, embarrassment, self-consciousness, and lack of self-confidence. The best approach to avoid scarring is the early treatment of inflammatory lesions. Different topical and systemic drugs are available for the therapy of acne. Isotretinoin is the most efficacy drug in severe acne but can cause some adverse effects. New topical and systemic drugs are emerging as well as new modalities of treatment including light and laser devices.

Acne vulgaris is a disease of the pilosebaceous unit and the most common inflammatory dermatosis worldwide. Limitations of conventional topical and systemic treatments include long treatment course, adverse effects, antibiotic resistance, and patient compliance. Therefore, laser and light-based interventions present as alternative options over the past decade and have been used in combination with conventional pharmacological therapies and other physical modalities. Among these light devices, photodynamic therapy, fractional radiofrequency and lasers that target pilosebaceous unit have shown to achieve good outcomes with a safe profile. An overview of these new technologies will be presented.

14:30 - 14:45

Pityriasis Rosea: Updates

Ashraf Hamza MD | Professor of Dermatology and Venereology

Pityriasis rosea is an acute, self-limited exanthem eruption, characterized by scaly discrete lesions of the trunk and limbs, usually sparing face, scalp, palms, and soles

Human herpes virus is the most likely etiological agent causing PR.

Pityriasis circinata et marginata of Vidal is a variant of PR characterized by large patches and chronic course.16% of PR cases develop variable mucosal lesions that is self-limited with the cutaneous eruption Pregnant women with PR may suffer from abortion or premature delivery, so such women should be kept on strict follow up

Drug induced PR like eruption is diagnosed by absence of Helard patch, severe itching and violet red color. Erythromycin is ineffective in PR and comparable to placebo treatment. Thus, there is no rationale of using these antibiotics. Acyclovir has been shown to be effective against HHV 6, on the other hand, it is not very effective against HHV 7, thus, acyclovir therapy should be given even if patients present later than one week

DAY ONE TUESDAY

5th March 2024

CONFERENCE HALL 2

THERAPEUTICS/NEW DRUGS/CASE PRESENTATIONS

14:45 - 15:00

Topical Vitamin D3 Derivative Versus Intralesional Vitamin D3 in the Treatment of Cutaneous Wart. A Clinical Therapeutic Comparative Study

Khalil Alhamdi MD | Professor of Dermatology and Consultant Dermatologist

Cutaneous warts are a common skin problem. There are a variety of treatment options with different success rates. In this study we used and compared topical and intralesional vitamin D3 cutaneous warts are a common skin problem. There are a variety of treatment options with different success rates. In this study we used and compared topical and intralesional vitamin D3. The study should that both treatments are safe and effective but topical vitamin D3 induced complete pure in 95% of cases versus 59% for intralesional mothed.

15:00 - 15:15

Post Acne Erythema: A New Treatment Modality

Dooha Alhamdi MD | Assistant Professor of Dermatology

Acne vulgaris is a common chronic inflammatory disease of the pilosebaceous unit. It can affect all ethicists and races. 80% of adolescents and young adults may get acne during their adolescence. Post acne erythema (PAE) is common sequela of acne, which may resolve spontaneously or persist for several months to years.

A prospective clinical therapeutic trial where a total 120patients with post acne erythema who completed the study were treated with topical ivermectin cream 1%, which was applied twice a day for 8 weeks. The patients were followed monthly for 3 successive months. The study showed that 62.5% of treated patient has revealed excellent response to treatment, 25% of patients showed very good response, 12.5% revealed good response to treatment. In conclusion: ivermectin proved to be safe effective treatment for this distressing problem.

15:15 - 15:30

The Efficacy of Methotrexate in the Treatment of Bullous Pemphigoid

Nemat **Alsaghir MD** | Assistant Professor of Dermatology

Bullous Pemphigoid is an autoimmune blistering disease, it usually affects elderly people, adding morbidity and mortality to there already existing diseases, because it may cause death due to infection or metabolic disterbance, moreover the accepted treatment for bullous pemphigoid is systemic steroids which have a great impact on the patient for its many side effects which could be fatal such as: hyperglicemia, high blood pressure and bone fractures.

Objectives: So there is a need to find new options, other than systemic steroids, which can achieve good response with less morbidity and side effects, we have investigated in our study the advantage of methotrexate in the treatment of bullous pemphigoid..

Methods: This presentation is to explain our comparison study between 2 groups of bullous pemphigoid patients: 44 patients were randomly divided into 2 groups, group 1: 22 bullous pemphigoid patients were treated with ultra potent topical steroids (clobetazole dipropionate) in addition to prednisolone 0.5 mg/kg alone, and group 2: 22 bullous pemphigoid patients were treated with ultra potent topical steroids (clobetazole dipropionate) in addition to weekly doses of methotrexate, starting with 5mg and increased gradually according to the patients

DAY ONE TUESDAY
5th March 2024

CONFERENCE HALL 2
THERAPEUTICS/NEW DRUGS/CASE PRESENTATIONS

response, patients were monitored during the following 2 years. cumulative dose of steroids and recurrence and side effects were studied.

Results: good response was achieved in 20 patients in group 1, and in 18 patients in group 2.

Average Time to achieve good response was 26 days in group 1, and 20 days in group 2.

Conclusion: methotrexate achieved good results with less side effects and shorter time. Finally explaining our experience in dermatology department in Damascus university will be presented.

15:30 – 16:00 Q & A / Break

Session 4
Chairperson: Hessa Mohammed Al Bashr MD, Isam Oumeish MD

16:00 - 16:20

Topical Metformin in Treating Acne Vulgaris: How New Routes Can Lead to Novel Destinations
Nermeen Bedair MD | Associate Professor of Dermatology

One of the recent suggested hypotheses for acne pathogenesis is that it comprises a cutaneous metabolic syndrome and is largely affected by western diet through hyperactivation of insulin, insulin-like growth factor 1 (IGF-1), mechanistic target of rapamycin complex 1 mTORC1 and forkhead box transcription factor O12. Moreover, accumulating evidence suggests that the skin microbiome as well as gut microbiome alterations may play a role in acne pathogenesis Metformin is a biguanide and considered one of the most prescribed antidiabetic medications worldwide, known to be convenient for being well tolerated, relatively safe and of low cost. However, the molecular targets of metformin and its exact mechanism of action are still to be elucidated. It induces phosphorylation of Thr172 thus activates AMP-activated protein kinase (AMPK), causing inhibition of mechanistic target of rapamycin complex 1 (mTORC1) signaling pathway. Metformin also regulates the expression of Sirtuin1 (Sirt1), a member of the class III (NAD+- dependent) histone deacetylases (HDACs). Other interesting effects of metformin are that it shifts composition of gut microbiota11 and that it disrupts cellular energy supply by mitochondrial complex1 inhibition.

Background Acne vulgaris (AV), a widely common disorder, that negatively affects the quality of life. Metformin is a relatively safe, cheap, and well tolerated drug that is widely used in the treatment of Diabetes. Systemic metformin has demonstrated promising results in treating acne, while topically it was studied for melasma and recalcitrant central centrifugal cicatricial alopecia. Objectives: to study the efficacy of topical metformin 30% in treating acne compared to placebo. Methods: Twenty-seven female AV patients were asked to blindly apply metformin and placebo gels to either side of the face for 12 weeks. AV lesion count was performed at baseline, at each visit and 4 weeks after stoppage of treatment. Results: At the end of the treatment period, the treated side showed significant improvement of comedones, papules and nodules but not pustules. Although, lesions count increased 1 month after stopping treatment, comedones and papules numbers were still significantly less on the metformin side compared to placebo. No side effects were reported. Limitations: The limited number of patients studied and the limited follow up period. The metformin effect was not studied on cellular and molecular levels Conclusions: Topical metformin nanoemulsion gel can be a promising safe and effective treatment of AV.

Acne pathogenesis is a complex with multifactorial element and needs combined treatment Metformin is one of the most prescribed medications worldwide with variable mechanisms of action and several potential actions Topical metformin probably has a different mechanisms of action than systemic metformin with wire range of

DAY ONE TUESDAY
5th March 2024

CONFERENCE HALL 2
THERAPEUTICS/NEW DRUGS/CASE PRESENTATIONS

indications Systemic metformin is used to treat acne that is mostly associated with polycystic ovarian syndrome (PCOS) but evidence showed it can treat acne without PCOS Topical metformin can be promising in treating acne for both inflammatory or non-inflammatory lesions

16:20 – 16:40

A Modern Approach to Scar Management – Combining Physical with Chemical Processes

Anna Maria Fenech Magrin MD | Clinical Senior Lecturer and Deputy Course Coordinator

The management of scars, whether related to trauma, surgery or following acne, has always been a challenging topic. Each year, 100 million patients acquire scars in the developed world. Most scars do not give any problems, but others can cause disfiguring, are aesthetically unpleasant and also cause symptoms. Clinical symptoms of scars include pruritus, pain and tenderness. Psychological symptoms can also occur, including depression and anxiety. These can lead to disruption of daily activities due to low self-esteem and therefore low quality of life. Over the years, many different approaches have been used and with novel and modern modalities of treatment, the options have broadened and one can employ a combined protocol depending on the degree of severity of scarring.

Background: Each year, 100 million patients acquire scars in the developed world. Fifty-five million are acquired after elective operations and 25 million after operations due to trauma. Most scars do not give any problems, but others can cause disfiguring, are aesthetically unpleasant, cause symptoms and can negatively influence the psychological wellbeing of the individual. Aim: To evaluate the best evidence based approach in treating patients with facial atrophic scars in an office-based environment. Method: Three health-related databases were systematically searched from January 2006 to July 2023. Papers reporting the efficacy and safety of the management of facial atrophic scars in an office-based environment were included. Data on patient demographics, study design, treatment modalities, time points, efficacy and safety were extracted. The Quality Assessment Tool for Quantitative Studies was used to critically appraise the quality of the included studies. Results: A total of 2420 records were identified. After removal of duplicates, 1290 records were screened by title and abstract. Out of these, 1193 records were excluded as they did not meet the proposed inclusion criteria. The full text of 97 papers qualified for full paper review. Out of these, 45 studies were eligible for data extraction. All the forty-five studies that qualified for data extraction were included. Out of the 45 included studies seven studies explored different laser treatment modalities, 13 studies explore the use of different combination of treatments, 2 studies focused on microneedling, one study explored the use of different chemical peels, five studies assessed the used of fillers, four studies explored subcision while four studies were classified under "others" as they compared a number of treatment modalities. Conclusion: It was also identified that combination treatments are showing promising results in the treatment of facial atrophic scars and therefore should be explored further. More randomized controlled trials and studies with larger sample sizes are required.However, the treatment modalities used depend on the types of scars, patient preference and circumstance.

DAY ONE TUESDAY

5th March 2024

CONFERENCE HALL 2

THERAPEUTICS/NEW DRUGS/CASE PRESENTATIONS

16:40 - 17:00

The Role of Massive Comedone Extraction in the Management of Acne - Experience with 1191 Algerian Patients

Mohamed Khouazem MD | Specialist Dermatologist

I introduced in my experience massive and systematic comedone extraction and nodules drainage (combined to Isotretinoin) for all the patients having a closed comedonal component or a mild to severe inflammatory acne, the results show a 92% decrease of leions count (compared to 30% with Isotretinoin only in the literature) after 6 weeks.

Introduction & Objectives: Systemic Isotretinoin is the cornerstone of severe acne treatment, used alone has many disadvantages (inflammatory flares, inefficiency against closed comedones, long improvement time and debatable healing rates after reaching the cumulative doses). Closed comedones surgical extraction is the key procedure to shortcut these inconveniences. The most severe cases of acne (nodulo-cystic and closed comedonian) are usually out of reach of conventional treatments such as topical and oral retinoids, they even worsen by getting more inflamed when medically treated because of the skin layer preventing the material from being drained outside, they are therefore considered as therapeutic dead-ends. The purpose of this study is to give clear evidence that surgically removing acne cystic and closed comedonian material will unlock the situation and drastically improve the quality of life by offering an immediate remission and better chances of definitive healing. Materials & Methods: From February 2017 to September 2022, 1191 patients with severe or unresponsive to conventional treatments acne received a protocol based on performing a surgical extraction/drainage of all comedonian and inflammatory lesions immediately before launching a 0.5 mg/Kg/day Isotretinoin course. Assessments based on lesions count were made on a regular basis until reaching 120-150 mg/Kg cumulative doses. Comedones surgical removal and inflammatory lesions drainage were renewed when required throughout the course. Results: Average acne improvement was 88% at one month, 96% at two months, 98% at 3 months and 99% at four months. 99% of the 433 patients who reached the cumulative doses were in complete remission. Isotretinoin-induced inflammatory flares were inexistent on the surgically cleansed areas and present only on the non-cleansed ones in patients requiring more than a single surgical session. The procedure didn't leave visible scars even when massive mini-incisions were performed on patients under full dose Isotretinoin courses (the average was 100 incisions per session). Conclusion: This is the first documented large-scale study of comedones surgical extraction associated with Isotretinoin, the procedure's advantages are the immediate and persistent acne clearance even for very severe acne, the avoidance of Isotretinoin-induced inflammation and the drastically increased complete remission rates after reaching cumulative doses. Previous literature records about Isotretinoin alone showed acceptable rates but after devastating scar-producing flares during the first treatment weeks, a side effect dramatically avoided by massively extracting comedones. The incisions - even massive and during a full dose Isotretinoin course - don't leave any visible scars, which seriously questions the recommendation to avoid all physical treatments amid such courses. This technique turns nodulo-cystic and closed comedonian acne from dead-end conditions into perfectly curable ones. However, further RCTs are needed to compare the procedure with the use of Isotretinoin alone.

DAY ONE TUESDAY

5th March 2024

CONFERENCE HALL 2

THERAPEUTICS/NEW DRUGS/CASE PRESENTATIONS

Session 5

Chairperson: Shaden Abdelhadi MD

17:00 – 17:15

Dermatology Interest Group

Mahra Khaled Al Shehhi | Senior Medical Student
Hajar Almansoor MD | Medical Student

The Dermatology Interest Group is a student- led initiative in United Arab Emirates University, College of Medicine and Health Sciences (Under the Supervision of Dr. Hassan Galadari) Since 2021. The Group Founders are Mahra Khaled Al Shehhi & Hajar Al Mansoori (Final year medical students). The session is a brief introduction where Emirati medical students interested in Dermatology share their local initiative which aims to raise awareness about dermatology in the region and globally.

The presentation will share with audience details of this initiative including: Aims\objectives, Events held such as the world skin health conference, Psoriasis Escape room and variety of session conducted with well-known dermatologist \ Collaborations\ Certificated received \ Future agenda and open platform for audience suggestions

17:15 – 18:00

Dermatology Teaching of My Undergraduate Medical Students - Where We Are Going?

Zbigniew Ruszczak MD | Chairman, International Clinical Case & Poster Presentation & Competition

DAY ONE TUESDAY

5th March 2024

CONFERENCE HALL 3

COSMETIC & SURGICAL DERMATOLOGY

Session 1

Chairperson: Sonja Sattler MD, Mariam Al Suwaidi MD

09:30 - 10:00

Long Term Data and Nuances Seen After 1726nm Laser Treatment of Acne

David J. Goldberg MD | Director of Cosmetic Dermatology

Introduction: A variety of energy-based devices have been used to treat acne. Many can induce some improvement in acne. However, once treatment is stopped acne flares are the norm. This is because none of these technologies impact directly on the sebaceous gland. 1726nm is directly absorbed by sebum and has no impact on melanin. This means this laser can be used in the treatment of acne in all skin types.

Abstract Summary: This talk will focus on our long-term data following use of a 1726nm (AviClear, Cutera) laser for the treatment of acne. Mechanism of action will be discussed, study parameters as well as the initial 3-month post-treatment data and now 6-month, 12 month and 2-year data will de be discussed.

10:00 - 10:30

New Updates on Exosomes – in the US and Abroad

Michael H. Gold MD | Owner, Medical Director

The use of exosomes has increased significantly over the past several years in aesthetic medicine. There is a myriad of potential uses for these extracellular vesicles that promote intracellular communication. The purpose of this presentation is to provide evidence-based medicine on their uses in aesthetic medicine.

Methods: Literature review looking at the current publications in the exosome space was used.

Results: At present, the current literature landscape for the use of exosomes in medical dermatology and aesthetics is small. The published data supports that wound healing is enhanced with the use of exosomes and that within aesthetics, procedures can heal faster than traditional therapy as well as accelerating hair growth in many individuals.

Conclusions: Exosomes have incredible potentials in dermatology and in aesthetic medicine. We must demand that appropriate clinical trials are performed to verify the current hype surrounding these products and determine how best to use them to benefit our patients.

10:30 - 10:45

Effects of Plate Cryolipolysis on The Cutaneous and Subcutaneous Tissue of the Abdominal Region

Patricia Froes Meyer MD | Physiotherapist

Introduction: Cryolipolysis reduces the thickness of adipose tissue without causing damage to the skin or neighboring tissues. The plate system offers the possibility of no complications arising from the use of suction, such as the presence of bruises after application, in addition to the treatment of areas that could not be clamped in the vacuum system. Objectives: To evaluate the effects of plate cryolipolysis on the cutaneous and subcutaneous tissues of the abdominal region. Materials and Method: The sample include a female participant

DAY ONE TUESDAY
5th March 2024

CONFERENCE HALL 3
COSMETIC & SURGICAL DERMATOLOGY

who underwent abdominoplasty surgery. The participant was evaluated using assessment protocols, perimetry, plycometry, photography, ultrasound and bioimpedance before the surgery. In the skin sample collected, immunohistochemical markers such as the inflammatory process (COX-2), Caspase, fibroblasts (FGF2 e FGFR1), mitochondrial fission factor and PPARGama were analyzed. The application of cryolipolysis was carried out in the supine position, with the help of elastic bands to maintain contact between the plates and the skin and a protective blanket. The application time will be approximately 62 minutes and only one session was carried out, at a temperature of -10ºC. The application methodology was 30 minutes of cryolipolysis, followed by 2 minutes of reperfusion, ending with another 30 minutes of cryolipolysis, with the right infraumbilical side treated and the left side maintained as control. After 60 days, the participant was reevaluated following the previous methodology and abdominoplasty surgery was performed.

Results: The markers caspase, cyclooxygenase (COX-2), FGF2, FGFR1, DRP1 showed significant results in relation to the control side ($p < 0.0001$, $p = 0.004$, $p < 0.0069$, $p < 0.0022$, $p < 0.0003$ respectively). Type I collagen was higher and significant in relation to the control ((0.0082) and PPARGama was negative.

Conclusion: All results demonstrate the effectiveness of plate cryolipolysis and the PPARGama result may demonstrate a lower risk of adipocyte hyperplasia due to its influences adipogenesis..

10:45 - 11:15

Stem Cells for Alopecia
Zekayi Kutlubay MD | Professor of Dermatology

Hair loss is a quite common condition observed in both men and women. Pattern hair loss also known as androgenetic alopecia (AGA) is the most common form of hair loss that is thought to affect up to 80% of men and 40% of women by age of 70. In AGA, the follicle miniaturization is accompanied by a decrease of anagen, with an increase in the percentage of telogen hair follicles containing microscopic hairs in bald scalp. In balding scalp, the number of hair follicle stem cells (HFSCs) remains intact, whereas the number of more actively proliferating progenitor cells markedly decreases. Androgenetic alopecia is a condition that results in hair loss in both men and women. Stem cell-based therapies have recently received lots of attention as potential novel treatments that focus on reactivating hair follicle stem cells and in this way enhance hair follicle growth, regeneration and development. Since AGA is characterized by defects in and loss of hair progenitor cells, while hair follicle stem cells (HFSCs) remain viable, transplantation of stem cells has become a well-accepted treatment option. The use of stem cells in androgenic alopecia seems to be a promising alternative to the standard treatment.

11:15 – 11:45

Regenerative Aesthetics: Blood Fat Exosomes-What is the Key to Turning Back Time
Maria Cristina Puyat MD | Dermatologist & Medical Director

The advances seen with stem cell technology are among the world's ultimate scientific breakthroughs. Novel strategies allowing treatment of many pathological conditions also pave the way for the development of new innovative regenerative therapies including soft tissue regeneration and wound healing. The future direction of stem cells is a revolutionary approach to improve aesthetic enhancements such as skin rejuvenation, autologous fat transfer, and targeting indications that involve a functional restoration of defective tissues.

DAY ONE TUESDAY

5th March 2024

CONFERENCE HALL 3

COSMETIC & SURGICAL DERMATOLOGY

Regenerative aesthetics is an emerging branch of regenerative medicine that aimed with the therapies to restore and rejuvenate the youthful structure and function using the body's own systems. In modern aesthetic practice, the most prominent among current regenerative treatments are platelet-rich plasma (PRP), stem cells, growth factors, and most recently, exosomes. Aging is inevitable; however, it is possible to restore, rejuvenate and repair its process.

11:45 - 12:00

Ocular and asymmetry side effects of Botulinum toxin injections

Zekayi Kutlubay MD | Professor of Dermatology

12:00 - 12:20

Treatment of Severe Acne Scars. Prospective and Randomized Study of Highly Purified Polynucleotide Versus Placebo

Antonino Araco MD | Specialist in Plastic Surgery

Managing acne scars is a challenge and therapies are divided into nonsurgical and surgical. Highly Purified Technology Polynucleotides, PN-HPT™ are a compound which contains a mixture of DNA polymers of different lengths. Numerous studies have shown that PN-HPT™ also serves as an energy source, thus influencing cellular growth and cells vitality.

Methods: We Included women aged 30–50 years old with grade 3–4 moderate-to-severe atrophic scars according to the Goodman classification; nonsmokers; had not had active acne during the past 5 years; Ten patients (PN-HPT™ group) were treated with 4.0 ml of PN-HPT™, and ten patients (control) were treated with 4.0 ml of normal saline. All medical treatments were performed in a double blinded manner; neither the injection doctor nor the patient knew if the PN-HPT™ or the placebo was being administered. Results: twenty women fit the inclusion criteria were enrolled in this study. Only patients in PN-HPT™ group improved significantly at 1 and 3 months after treatment compared to baseline. Conclusions: Our prospective and randomized study showed that PN-HPT™ in monotherapy was safe and effective treatment for atrophic scar acne when compared with placebo. Prospective and randomized studies will be necessary to investigate the clinical effectiveness in a larger cohort of patients and for a longer follow up.

12:20 - 12:40

New Concepts in HA Crosslinking for Dermal Fillers

Stephane MEUNIER | CEO

Hyaluronic acid biopolymer (HA) is a major component of the extracellular matrix (ECM) and is presents in various biological tissues. Crosslinked HA forms viscoelastic gels, used in diverse biomedical application, and especially as dermal fillers for aesthetic use.

Crosslinked dermal fillers manufacturing often require toxic additives and harsh conditions to activate HA for

DAY ONE TUESDAY
5th March 2024

CONFERENCE HALL 3
COSMETIC & SURGICAL DERMATOLOGY

crosslinking, concomitantly, breaking the long polymer chains, thus requiring high HA concentration in the final products.

In this presentation will be a new method for HA crosslinking under mild conditions, aimed to develop a new generation of dermal fillers. The method is based on a 'click' crosslinking of HA, a technology similar to the awarded 2022 Chemistry Nobel Prize. Owing to this method, the HA polymers preserve their native high molecular weight, at an ultralow degree of substitution and HA content, with high elasticity and high biocompatibility.

12:40 - 13:00

Non BDDE Cross Linking in HA Filler: New and Long-Term Safer Approaches for Our Patients
Sonja Sattler MD | Dermatologist, Aesthetic Physician and CEO

13:00 - 14:00 **Q & A / Lunch Break**

Session 2
Chairperson: David J. Goldberg MD

14:00 - 14:20

Novel Laser and Non-Laser Approaches to the Treatment of Melasma
David J. Goldberg MD | Director of Cosmetic Dermatology

A wide variety of lasers and energy-based devices have been used to improve skin quality. In general, the 1064nm wavelength is safest on ethnic skin. Historically, most 1064nm lasers have utilized millisecond, nanosecond, and picosecond technology.

This talk will focus on a new novel microsecond 1064nm laser and its approaches to improving multiple skin issues in ethnic skin. This 1064nm laser is also unique in its safety profile.

14:20 - 14:40

Microneedling RF in 2024 – What Have We Learned
Michael H. Gold MD | Owner, Medical Director

Botulinum toxin A transformed the aesthetic and cosmetic arena into heights that no one saw coming when the first toxin was approved many years ago.Newer toxins have emerged into the clinical scene and this presentation will differentiate these newer toxins and show the clinical evidence that has entered into the public domain with respect to these toxins. In addition, several newer toxins are in clinical trials at this time, and preliminary, public domain data will also be presented. It is an exciting time still for toxins for cosmetic use and we will focus on how some of these newer toxins may make a difference for our patients

DAY ONE TUESDAY

5th March 2024

CONFERENCE HALL 3

COSMETIC & SURGICAL DERMATOLOGY

14:40 - 15:00

Step Wise Approach for Facial Glamorisation

Chytra Anand MD | Chief Consultant Cosmetic Dermatologist

Step Wise Approach for Facial Glamorisation," a lecture designed for professional injectors seeking mastery in facial aesthetics through the use of fillers and toxins. This insightful session will delve into strategic planning and assessment methodologies that prioritize patient-specific outcomes. By integrating artistic principles with medical precision, participants will learn to enhance natural beauty, ensuring optimum results that embody glamour. Join us as we explore the transformative power of cosmetic dermatology, providing you with the knowledge to craft not just a treatment, but an experience that celebrates individuality through tailored facial glamourisation.

In the pursuit of facial glamourisation, injectors must navigate complex decisions to achieve optimal aesthetic results. This presentation delineates a step-wise approach, emphasizing anatomical markers for structural reconstruction, discerning indications for lifting versus volumization, and precise injection locales for ideal outcomes. We will dissect the subtleties of facial topography, focusing on the pivotal points for product deposition that respect the intricate interplay of facial dynamics. By equipping practitioners with a clear algorithm—balancing the rheological properties of injectables with patient-specific anatomical considerations—we aim to standardize the enhancement process, fostering reproducible excellence in facial aesthetic procedures for dermatologists and plastic surgeons alike.

15:00 - 15:20

Fractional, Bipolar Radiofrequency in Facial Rejuvenation and Skin Resurfacing. A New Paradigm in Safety and Results

Fadi Hamadani MD | Professor of Plastic Surgery, Division Chief, Plastic & Reconstructive Surgery

This conference presentation will address the challenges associated with rejuvenating moderately to severely aged skin and examine the efficacy of fractional bipolar radiofrequency with 24 fixed pins at 500 µm. This method yields significant skin rejuvenation without the extended downtime linked to more aggressive treatments like deep peels or ablative laser therapies. Additionally, the presentation will discuss the use of complementary fractional bipolar tips with programmable depth (1-4mm) for targeting fat, skin coagulation, and remodeling. It will showcase how these can be seamlessly integrated with regenerative treatments such as biostimulants, threads, and nanofat for comprehensive facial rejuvenation. The talk will also touch upon the utilization of ultrasound to map different depths of targeted soft tissues, guiding the selection of the appropriate mode and depth in the device. Overall, the presentation aims to offer insights, clinical strategies, and practical tips for achieving safe and reproducible results through bipolar, fractional radiofrequency.

15:20 - 15:40

Recent Insights into HIFU for Facial Contouring: Strategies and Innovations

Do-Young Rhee MD | Director

High-intensity focused ultrasound (HIFU) is widely used for non-surgical facial lifting and tightening, particularly demonstrating significant improvements in facial contours, especially for individuals with excess fat in areas like the jowl or submental fat compared to those with leaner faces. While high-energy treatments were common, recent

DAY ONE TUESDAY
5th March 2024

CONFERENCE HALL 3
COSMETIC & SURGICAL DERMATOLOGY

recommendations advise using lower energy with an adequate number of shots. Indeed, a recent animal study has reported a decrease in fat thickness through mechanisms involving apoptosis and autophagy when applying low-energy HIFU. Another intriguing animal study has suggested that extremely low-energy applied to fat layers may clinically increase fat volume which evidenced by the rise in fat layer thickness, adipocyte count, and adipocyte size. This implies the potential use of HIFU not only for volume reduction but also in volumization procedures.The application of HIFU energy involves two modes: sequential discrete mode and continuous scanning mode. The traditional sequential discrete mode generates thermal coagulation points (TCPs) at regular intervals and depths, while continuous scanning reduces spaces between TCPs, forming a linear thermal coagulation zone. In contrast to the fractional heating achieved in sequential discrete mode, the linear continuous scanning method evenly distributes heat across tissues through bulk heating. This approach brings notable benefits, including quicker treatment time, decreased discomfort, and minimized side effects.

This lecture aims to discuss facial contouring strategies using the traditional 'Dot' cartridge adopting sequential discrete mode and the novel 'Linear' cartridge adopting continuous scanning mode. The strategy and its rationale will be explored with a review of recent studies

15:40 - 16:00 **Q & A / Break**

Session 3
Chairperson: Michael H. Gold MD, Khalil AlArrayed MD

16:00 - 17:00

Exosome: Panel Discussion
Byongseong Cho MD | CEO and CTO
Shanthala Shivananjappa MD | Founder & CEO
Ilaria Proietti MD | Dermatologist
Abdullah Al Eisa MD | Consultant Dermatologist and Medical Director
David J. Goldberg MD | Director of Cosmetic Dermatology

17:00 - 17:15

Evaluation of Intralesional Injection of Botulinum Toxin Type A or Hyaluronidase Enzyme Versus Intralesional Triamcinolone Acetonide in Treatment of Keloid
Khaled Gharib MD | Professor of Dermatology and LASER

Keloid refers to an abnormal connective tissue encompassing fibrous and vascular elements and often results from abnormal reaction of skin to injurious stimuli.

Patient and methods: Group I: intralesional TAC in the right half and BTA in the left half of the keloid. Group II: intralesional injection of TAC in the right half and HYAL in the left half of the lesion. Results: The percentage of improvement was 57.2% in TAC side vs 50% in the BTA side with no statistically significant difference. Conclusion: the efficacy of both intralesional TAC and BTA is comparable. TAC was superior to BTA but the difference was not significant.

The aim of this study was to evaluate the clinical efficacy, safety and tolerability of intralesional injection of Botulinum toxin A, Hyaluronidase enzyme in keloid versus triamcinolone acetonide.

DAY ONE TUESDAY

5th March 2024

CONFERENCE HALL 3

COSMETIC & SURGICAL DERMATOLOGY

17:15 - 17:30

Overview of Complications with Hyaluronic Acid (Ha)-Fillers

Jesper Thulesen MD | Ophthalmologist and Oculoplastic surgeon

Complications following injections of HA-filler divert from mild to very severe, e.g. blindness as the most feared complication. For the professional and experienced aesthetic physician prompt and relevant intervention is expected in these situations although specific treatment algorithms for most of the HA-filler-related complications are lacking.

A schematic overview of the complications with clear statements for treatment solutions will be presented based on the up-to-date findings and most recent published recommendations in the literature.

This overview will help the aesthetic physician in the clinical settings with prompt diagnosis of the condition, and facilitate sufficient reactions to diminish the consequences for the patient with a complication.

17:30 - 17:45

Complications and Sad Effects after Cosmetic Injections

Laurent BENADIBA MD | Plastic Surgeon

The management of sad effects and complications are absolutely necessary for beginners and experts in cosmetics injections.

Cosmetics injections are more and more popular around the world and especially in some countries where the impact of social networks is very high. The significant increase of injectors explains the augmentation of sad effects and complications. Some of them are irreversible such as necrosis and blindness. In this presentation, the author, University Professor in France presents how to prevent and manage complications and unsatisfaction with fillers and toxin injections. The author gives the tools to prevent and resolve potential conflicts with patients after cosmetic injections.

The author explains the management of simple sequences, the management of complications: yours and those of your colleagues and fake injectors and the management of dissatisfaction.

17:45 - 18:00

Role of Hyaluronidase in The Treatment of Complications of Hyaluronic Dermal Filler

Mohamad Essam Kayyali MD | Consultant of Plastic Surgery

As demands for filler injections increases because of the great interest with beuty and youth as number of aesthetic pratitioners and filler syringes in use increases. Sometimes during or after of injection of filler doctor might be hesitant if this discoloration is a case of bruising due to bleeding (vessel injury) or real vascular occlusion (ischemia) , he or she couldn't differentiate between the 2 diagnosis , each of the 2 diagnosis has totally different management so in the first diagnosis (simple bruising) it is enough to press on the affected area to stop the bleeding and it will resolve spontaneously after few days without any sequelae, but on the other hand in case he decided the 2nd diagnosis(ischemia) he should do a lot of prompt actions like injections of huge amount of hyaluronidase and give the patient so many medications and observations and the case might end with tissue necrosis or blindness and disability

DAY ONE TUESDAY
5th March 2024

CONFERENCE HALL 3
COSMETIC & SURGICAL DERMATOLOGY

Is it a simple bruising or real ischemia (arterial occlusion) As demands for filler injections increases because of the great interest with beauty and youth as number of aesthetic practitioners and filler syringes in use increases. Sometimes during or after of injection of filler doctor might be hesitant if this discoloration is a case of bruising due to bleeding (vessel injury) or real vascular occlusion (ischemia) , he or she couldn't differentiate between the 2 diagnosis , each of the 2 diagnosis has totally different management so in the first diagnosis (simple bruising) it is enough to press on the affected area to stop the bleeding and it will resolve spontaneously after few days without any sequelae, but on the other hand in case he decided the 2nd diagnosis(ischemia) he should do a lot of prompt actions like injections of huge amount of hyaluronidase and give the patient so many medications and observations and the case might end with tissue necrosis or blindness and disability . at this situation if the doctor couldn't put the right diagnosis, he might put wrong plan for management and the case could be ended catastrophic results, for example if the case is simple bruising and mistakenly was diagnosed as ischemia the doctor will inject unnecessary huge amount of hyaluronidase which will increase the bleeding and bruising and dissolve the injected filler material. on the other hand, if the case is ischemia and diagnosed as bruising and no action was taken, this could lose the golden time to treat the ischemia and might end with tissue necrosis. This presentation to talk in details how to differentiate between the 2 diagnoses of bruising and ischemia which might help the doctor to put the right diagnosis and prompt action to manage it which can help to decrease the rate of complication after filler injection.

18:00 - 18:15

Tear Trough Correction Using High G Prime Hyaluronic Acid Filler: My Innovative Bolus Technique

Afsheen Bilal MD | CEO, Consultant Dermatologist

"Tear trough "correction and treatment of under-eye dark circles is one of the most challenging areas of facial rejuvenation. Improper treatment of dark circle is a cause of significant psychological distress. Under-eye dark circles are seen in all types of skins and strong familial tendency is noted in darker skin types. The causes are usually multifactorial as soft tissue and bony changes, lifestyle routines, skin changes, hormonal factors and different allergies. Loss of volume in skin and subcutaneous tissues of tear trough area, along with tethering of skin to tear trough ligament gives sunken appearance to lower eyelid with associated prolapse of the orbital fat and age related thinning of skin can further worsen the appearance of dark circles. Usually low viscosity hyaluronic acid fillers are being used to treat tear trough, which results in Tyndall effect and soft tissue swelling which may further cause worsening of the eye bags and dark circles leading to high level of psychological distress and patient's dissatisfaction.

Summary: Keeping the above description in mind the author has introduced an innovative technique (Modified Mauricio de Maio's technique) to treat tear trough. It includes use of high G prime filler to be given in small bolus using 30 gauze BD syringe in pre-periosteal plane in the tear trough area and also along orbital rim. Multiple small bolus of 0.1ml per bolus to be given along the orbital rim. To make flow easier the HA gel was diluted with 0.1-0.2ml lidocaine 2% with adrenaline. This case series includes 50 patients ,who were treated with 1-2ml high G prime filler(HA 25mg/ml) for periorbital rejuvenation. Pretreatment topical anesthetic cream was applied to lower periorbital region for 30 minutes. Diluted high G prime HA filler (1-2ml) was given at 5-6 places along the orbital rim in pre-periosteal plane using 30 gauze BD syringe on each side(0.5ml-1ml per side). Almost all the patients showed high level of satisfaction with the results which lasted for over 12 months on follow up. The procedure was uneventful in most of patients except for few patients who developed post procedure bruising which resolved in 7-14 days without treatment. One patient developed Tyndall effect because she had very thin

DAY ONE TUESDAY

5th March 2024

CONFERENCE HALL 3

COSMETIC & SURGICAL DERMATOLOGY

skin, which was treated with hyaluronidase. Use of this innovative technique with high G prime HA fillers for tear trough correction may bring good esthetic outcomes in patient with dark circles and under eye bags with good longevity and low risk of complications. "Tear trough "correction and treatment of under-eye dark circles is one of the most challenging areas of facial rejuvenation. Improper treatment of dark circle is a cause of significant psychological distress. Under-eye dark circles are seen in all types of skins and strong familial tendency is noted in darker skin types. The causes are usually multifactorial as soft tissue and bony changes, lifestyle routines, skin changes, hormonal factors and different allergies. Loss of volume in skin and subcutaneous tissues of tear trough area, along with tethering of skin to tear trough ligament gives sunken appearance to lower eyelid with associated prolapse of the orbital fat and age-related thinning of skin can further worsen the appearance of dark circles. Usually, low viscosity hyaluronic acid fillers are being used to treat tear trough, which results in Tyndall effect and soft tissue swelling which may further cause worsening of the eye bags and dark circles leading to high level of psychological distress and patient's dissatisfaction. Summary: Keeping the above description in mind the author has introduced an innovative technique (Modified Mauricio de Maio's technique) to treat tear trough. It includes use of high G prime filler to be given in small bolus using 30 gauze BD syringe in pre-periosteal plane in the tear trough area and also along orbital rim. Multiple small bolus of 0.1ml per bolus to be given along the orbital rim. To make flow easier the HA gel was diluted with 0.1-0.2ml lidocaine 2% with adrenaline. This case series includes 50 patients, who were treated with 1-2ml high G prime filler (HA 25mg/ml) for periorbital rejuvenation. Pretreatment topical anesthetic cream was applied to lower periorbital region for 30 minutes. Diluted high G prime HA filler (1-2ml) was given at 5-6 places along the orbital rim in pre-periosteal plane using 30 gauze BD syringe on each side (0.5ml-1ml per side). Almost all the patients showed high level of satisfaction with the results which lasted for over 12 months on follow up. The procedure was uneventful in most of patients except for few patients who developed post procedure bruising which resolved in 7-14 days without treatment. One patient developed Tyndall effect because she had very thin skin, which was treated with hyaluronidase. Use of this innovative technique with high G prime HA fillers for tear trough correction may bring good esthetic outcomes in patient with dark circles and under eye bags with good longevity and low risk of complications.

DAY ONE TUESDAY

5th March 2024

CONFERENCE HALL 4

ASSOCIATION PROGRAM

Session 1: SHARM DERMA Session

Chairperson: : Assem Farag MD

09:30 - 09:50

Alopecia Areata: My New Data

Assem Farag MD | Professor of Dermatology

09:50 - 10:10

Tips & Tricks in Scar Management

Shady Mahmoud MD | Professor of Dermatology & Venereology

Scarring, especially disfiguring facial scars may be associated with a heavy emotional burden for patients. Facial Scarring may be a major source of dissatisfaction, psychological distress, depression, or embarrassment. Different modalities should be addressed in scar management according to type of scar such as resurfacing fractional lasers, vascular specific lasers in fresh scar, intralesional corticosteroid, surgical procedures, emulsified fat injection, filler injection, and exosomes. Combined treatment shows a promising result and can achieve best outcome for patients with scar.

10:10 - 10:30

Psoriasis: Clinical Tips

Amin Sharobim MD | Lecturer of Dermatology

10:30 - 10:50

JAK Inhibitors: Updated

Assem Farag MD | Professor of Dermatology

10:50 – 11:10

Tips in Midface and Tear Trough Injection

Nevine Dorgham MD | Professor of Dermatology

Filler injection for midface area is the most common in our practiceTo perfect our injection , we need to know the danger zones, different techniques for injection, how to choose the patient, material & injection method.

DAY ONE TUESDAY

5th March 2024

CONFERENCE HALL 4

ASSOCIATION PROGRAM

11:10 - 11:30

Tips in Upper Face and Temple Injection
Amin Sharobim MD | Lecturer of Dermatology

11:30 – 11:50

Updated Tips in Botulinum Toxin Injection
Rehab Hegazy MD | Professor of Dermatology

11:50 - 12:10

Tips & Tricks in Laser Practicing in Dermatology & Aesthetics
Shady Mahmoud MD | Professor of Dermatology & Venereology

Scarring, especially disfiguring facial scars may be associated with a heavy emotional burden for patients. Facial Scarring may be a major source of dissatisfaction, psychological distress, depression, or embarrassment. Different modalities should be addressed in scar management according to type of scar such as resurfacing fractional lasers, vascular specific lasers in fresh scar, intralesional corticosteroid, surgical procedures, emulsified fat injection, filler injection, and exosomes. Combined treatment shows a promising result and can achieve best outcome for patients with scar.

12:10 - 12:30

Tips in Melasma & Face Pigmentation
Nevine Dorgham MD | Professor of Dermatology

Melasma & face pigmentation is the very common in our practice

A lot of treatments are available, including topicals, injections, peels, microneedling & lasers

Choosing the method & combining more than one is the main key for success.

12:30 - 12:50

Off Label Uses of Drugs in Dermatology
Rehab Hegazy MD | Professor of Dermatology

12:50 - 14:00 **Q & A / Lunch Break**

DAY ONE TUESDAY

5th March 2024

CONFERENCE HALL 4

ASSOCIATION PROGRAM

Session 2: International Society of Dermatologists (ISD) Session

Chairperson: Abdullah Alakeel MD, Hassan Galadari MD

14:00 - 14:15

MicroBotox: Rising Trend or a Fading Fad?

Hassan Galadari MD | Associated Professor of Dermatology

Microbotox is a minimally invasive cosmetic procedure that involves injecting tiny amounts of diluted botulinum toxin into the skin to improve its texture and reduce the appearance of fine lines and wrinkles. Unlike traditional Botox injections, microbotox targets the superficial layer of the skin, resulting in a more natural and subtle effect without affecting muscle movement. It is also known to reduce oil production and shrink pores, making it an effective treatment for acne and oily skin. Microbotox is gaining popularity for its ability to provide a refreshed and rejuvenated appearance with minimal downtime and side effects. It is a promising option for individuals seeking non-surgical facial rejuvenation.

14:15 - 14:30

Hidradenitis suppurativa: An Update

Jacek C. Szepietowski MD | Chair of the Department of Dermatology, Venereology and Allergology

Hidradenitis suppurativa (HS) is a chronic inflammatory disorder of the hair follicle characterized by recurrent nodules, abscesses and pus-discharging sinus tracts in flexural regions. The pathogenesis is multifactorial and besides genetics, hormonal and lifestyle factors also microbial components seem to be involved. Endogenous genetic predisposition, changes in hormone levels as well as external agents, such as mechanical stimulation and smoking contribute to occlusion of the hair follicle, which is considered as the initiating event in HS. Continuing obstruction of the follicular infundibulum results in its rupture and extrusion of follicular contents into the surrounding dermis. The diffusion of released molecules from pilosebaceous unit elicits strong chemotactic inflammatory response leading to affluence of neutrophils, lymphocytes and histiocytes. Chronic inflammation in association with microbial infiltration of the subcutaneous tissue induces sinus tracts and fistulas formation. Current treatment of HS included both conservative and surgical managements. Systemic antibiotics have been a gold standard for moderate to severe HS. Nowadays, biologics like adalimunab, secukinumab and bimekizumab may effectively reduce severity of HS. The combined treatment with systemic anti-inflammatory drugs and surgical procedures should be gold standard in the contemporary management of patients with HS.

14:30 - 14:45

Post-inflammatory Hyperpigmentation, The Other Side of the Inflammation

Giovanni Pellacani MD | Chairman of Dermatology Department

DAY ONE TUESDAY
5th March 2024

CONFERENCE HALL 4
ASSOCIATION PROGRAM

14:45 - 15:00

Spot Light on Translational Studies in China
Xinghua Gao MD | Professor, Chair of Dermatology and Deputy Director

Aiming at producing new techniques and products for management of skin diseases, Chinese dermatologists, along with scientists from other disciplines, are endeavoring and has made remarkable progress on translational studies.

This presentation illustrates a couple of examples of translational studies mostly initiated by Chinese dermatologists. Including defining and using biomarkers for diagnosis and evaluation of SLE, prevention of dapsone induced severe adverse drug reactions, local hyperthermia devices for 'cold ' mucocutaneous HPV and other microbial infections and, AI aided technique for dermatopathology.

15:00 - 15:15

Acquired Dermal Macular Hyperpigmentation
Rashmi Sarkar MD | Director -Professor, Dept of Dermatology

15:15 - 15:30

What's the Deal with Exosomes?
Samar Khalil MD | General and Cosmetic Dermatologists

Exosomes are an exciting new area of scientific research with huge potential in fields like regenerative medicine and cancer treatment. These tiny, membrane-bound vesicles secreted by cells carry a cargo of bioactive molecules, including proteins and nucleic acids, that can influence neighboring or distant cells. However, as we delve deeper into the potential therapeutic applications of exosomes, a host of challenges become apparent. One of the foremost concerns is the safety of utilizing exosomes for clinical purposes, as their complex composition raises questions about potential side effects and unintended consequences. Additionally, there is an urgent need for standardization in the processes of isolating, purifying, and quality controlling exosomes to ensure consistency and reliability across experiments and applications. Addressing these challenges is essential to unlock the full potential of exosomes as a transformative tool in medicine and biology.

15:30 - 15:45 **Q & A / Break**

Session 3: SIDEMAST Session
Chairperson: Giovanni Pellacani MD, Ketty Peris MD

15:45 - 16:05

Inflammatory Skin Disease and Imaging
Giovanni Pellacani MD | Chairman of Dermatology Department

DAY ONE TUESDAY
5th March 2024

CONFERENCE HALL 4
ASSOCIATION PROGRAM

16:05 - 16:20

Effectiveness and Safety of a 675 nm Laser Device in the Treatment of Facial Aging and Melasma
Elena Zappia MD | Medical Doctor

Wrinkles represent a major sign of aging skin and are considered a major topic in cosmetic dermatology, representing a common problem that negatively impacts patients' quality of life. Melasma is a common dermatological condition especially on darker skin types in asian population, often recalcitrant and difficult to treat. Different types of topical and laser-based treatments are currently available to counteract ageing skin signs and melasma.

The aim of this presentation is to assess the efficacy and safety of a new 675 nm laser source system on facial wrinkles and pigmentary disorders as it acts selectively on melanin and collagen, sparing surrounding tissue.

This novel peculiar mechanism of action of the 675 nm laser system can be considered a promising and effective tool in patients with facial wrinkles and melasma, and it involves a simple post-treatment management.

16:20 - 16:40

Medical Approach to Skin Pigmentation
Stefania Guida MD | Assistant Professor of Dermatology

Skin hyperpigmentation can be related to different dermatologic conditions, such as solar lentigo, post-inflammatory hyperpigmentation and melasma. Additionally, other skin diseases should also be ruled out and a proper diagnosis before treatment is pivotal for treatment planning.

Several skin conditions may present with skin hyperpigmentation. After performing the proper diagnosis, medical treatments usually involve a combination of peelings and home treatment exploiting anti-pigmentary, anti-oxidant and anti-inflammatory properties of different agents. Clinical cases will be presented and discussed.

16:40 - 17:00

Spesolimab in the Treatment of Generalized Pustular Psoriasis
Annunziata Dattola MD | Researcher at Department of Dermatology University of La Sapienza, Rome

Generalized pustular psoriasis (GPP) is a rare, chronic, and severe skin disorder characterized by the eruption of non-infectious pustules on an erythematous background often associated with systemic symptoms. It may appear in association with plaque psoriasis or occur in previously healthy individuals. It differs from psoriasis vulgaris in clinical presentation, immunopathogenesis, histology, and therapeutic strategies. Overexpression of interleukin 36 (IL-36) or a loss-of-function mutation of IL-36 receptor antagonist (IL-36RA) are thought to play a pivotal role in the pathogenesis of this disease. There are currently no globally approved guidelines for the treatment of GPP and the therapies used so far, with variable results, have given unsatisfactory results. Spesolimab, a selective humanized antibody against the IL-36 receptor that blocks its activation, is the first biologic drug approved in Europe in December 2022 for the treatment of GPP flares. It represents a promising therapy, demonstrating efficacy in reducing disease severity and improving patient outcomes. In our review we have analyzed the latest advancements and findings regarding the efficacy and safety of Spesolimab in the context of GPP management.

DAY ONE TUESDAY

5th March 2024

CONFERENCE HALL 4

ASSOCIATION PROGRAM

17:00 - 17:15

Extreme Makeover-injectable Edition: Beyond Beautification

Ilaria Proietti MD | Dermatologist

Hyaluronic acid fillers and botulinum toxin play a crucial role beyond aesthetics. These treatments are often used for medical purposes, improving the quality of life for many individuals.

Fillers can be used to address acne scars, congenital deformities, or post-surgical issues. Additionally, both substances are employed to treat medical conditions such as urinary incontinence, enhancing bladder function.

Hyaluronic acid and botulinum toxin play a crucial role in the treatment of facial asymmetries, post-trauma reconstruction, aesthetic enhancement, and overall well-being. Hyaluronic acid is used to correct facial asymmetries, restoring volume and harmony. In cases of trauma, it can be employed to reconstruct damaged soft tissues, improving both appearance and functionality.

Botulinum toxin relaxes hyperactive facial muscles, reducing wrinkles and asymmetries, enhancing the overall appearance. These treatments can positively impact patients' quality of life, boosting self-confidence and self-esteem. Furthermore, they contribute to functional recovery in post-trauma situations, allowing patients to lead a more satisfying and balanced life.

17:15 - 17:30

A New Technology in Non-invasive Face Contouring and Rejuvenation

Elena Zappia MD | Medical Doctor

Facial contouring is a widely practiced aesthetic procedure aimed at enhancing facial shape and definition. In recent years, the use of microwaves has emerged as a promising non-invasive option for improving facial contours. This abstract provides an overview of microwave applications in facial contouring, highlighting mechanisms of action, clinical outcomes, and safety considerations associated with this emerging technology.

Abstract Summary: Microwaves have been successfully employed in the field of aesthetic medicine due to their ability to penetrate deep into adipose tissue structures. During microwave-based facial contouring treatments, a probe emits controlled microwaves at a specific frequency. These microwaves induce selective heating in adipose cells, triggering a cascade of cellular events that lead to lipolysis and contraction of adipose tissue. This process, known as selective thermolysis, results in a reduction in subcutaneous fat and enhanced facial contour definition. Numerous clinical studies have demonstrated the effectiveness of microwaves for facial contouring. Patients undergoing this procedure have reported significant improvements in facial definition, with visible results appearing within weeks of treatment. Furthermore, microwaves stimulate collagen production in the skin, helping improve skin elasticity and tone, as well as combating signs of aging. One of the primary advantages of microwaves in facial contouring is their non-invasive nature. Unlike traditional surgical procedures, no incisions, sutures, or extended recovery times are required. Patients can typically resume their daily activities almost immediately after treatment, making this aesthetic option highly appealing to many individuals. However, it is crucial to emphasize the importance of proper patient evaluation and careful candidate selection. Not all patients are suitable for microwave-based facial contouring, and the experience and expertise of the medical professional are essential for achieving satisfactory and safe outcomes. Additionally, multiple treatment sessions are required to achieve optimal results, and patients should be informed about the need to adhere to the prescribed treatment plan. Safety is a critical aspect of microwave use in facial contouring. Equipment must be precisely calibrated to avoid skin injuries or unwanted effects. Adequate training of medical practitioners in the use of this technology

DAY ONE TUESDAY
5th March 2024

CONFERENCE HALL 4
ASSOCIATION PROGRAM

and strict adherence to guidelines are essential to ensuring patient safety. In conclusion, the use of microwaves in facial contouring represents a promising non-invasive option for enhancing facial contours and reducing subcutaneous fat. This technology has proven to provide effective and visible results, with the added benefit of minimal recovery times. However, accurate patient selection and safety considerations are crucial for achieving optimal outcomes. Ongoing research and the development of new technologies in the field of microwave-based facial contouring promise further enhancements and innovations in aesthetic medicine.

17:30 - 17:45

Which Injectable for Different Skin Conditions? Evaluation by 2D,3D Photographs, RMC, Ultrasound, and Oct

Federica Trovato MD | Dermatology Resident

Hyaluronic injectables have been used in the field of aesthetic medicine for many years for volumizing, replenishing, and regenerative purposes. We wondered what happens at the epidermal, dermal, and hypodermal levels after treatment with various types of hyaluronic acid in patients with different needs (rejuvenation, scar minimization, texture enhancement), and investigated through non-invasive in vivo imaging (Visia System, RCM, OCT).
We treated 11 patients with different skin problems (photoaging, chronoaging, acne scars, rosacea) with hyaluronic acid injectables, chosen according to patient characteristics (skin problem, skin texture, age, phototype, aesthetic history and expectations). We performed acquisitions with 2d, 3d dynamic photography, Reflectance Coherence Microscopy (RCM) and Optical Coherent Tomography (OCT)

SKINMEDIENCE

TAPSKO
Semi-permanent
Tripod lifting
TAPS
KOKO
#5

PCL-Press cog
19G 40mm

PCL-Press cog
19G 60mm

PCL-Mesh
21G 60mm

PCL-Mesh ball
21G 60mm

SKINMEDIENCE

Ellipse press cog
Deeper and Thicker Cog

- Strong lifting and fixation
- Long Lasting Durability

ABSTRACTS

Wednesday| 6 March 2024

DAY TWO

CONFERENCE HALLS

1 | 2 | 3 | 4

DAY TWO WEDNESDAY

6th March 2024

CONFERENCE HALL 1

DERMATOLOGY SCIENCES & RESEARCH

Session 4

Chairperson: Fouad El Sayed MD, Firas Al Qarqaz MD

08:30 - 09:00

Psychosocial Burden of Acne

Jacek C. Szepietowski MD | Chair of the Department of Dermatology, Venereology and Allergology

Acne vulgaris is a common inflammatory disease of pilosebaceous unit. It affects mainly adolescents and young adults; however, acne lesions may occur also in older people (adult acne). It is estimated that acne is present in about 80% of adolescents and 40% of adults. In the majority of patients it has a mild clinical severity, however about 20% of acne subjects suffer from severe disease. Acne, although not being a life-treating disease, should not be considered as only cosmetic problem as it has serious psychosocial consequences. Study conducted by the European Society for Dermatology and Psychiatry in 13 European countries clearly showed that acne patients are at increased risk of the development of depression and anxiety. Moreover, suicidality is an important problem of acne suffers. Our group documented that facial acne markedly contributes to the decreased quality of life (QoL). Additionally, acne patients have increased level of stigmatization. Although, acne does not seem to predispose to alexithymia, alexithymia in acne subjects correlates with QoL impairment and stigmatization level. All above should be taken into consideration in the holistic approach to patients with acne vulgaris.

09:00 - 09:30

Update in the Management of Lichen Planus

Fouad El Sayed MD | Professor and Head of Dermatology, Lebanese University

Lichen planus is an inflammatory disorder of the skin and mucous membranes with no known cause. It appears as pruritic, violaceous papules and plaques most found on the wrists, lower back, and ankles. A lattice-like network of white lines called Wickham striae overlies the lesions but is most easily observed on the buccal mucosa where erosions can also be present. Drug-induced lichen planus, or lichenoid drug eruption, is frequently photodistributed but may be indistinguishable from idiopathic LP. This activity describes management of lichen planus based on case presentation with appropriate guidelines.

09:30 - 09:45

Concepts and Differences of Platelet-Rich Plasma (PRP), Platelet-Poor Plasma (PPP), and Platelet-Rich Fibrin (PRF)

Burcu Yamangöktürk Solak MD | Dermatologist, General Secretary and Founding Member

The latest approach in plasma biomaterial and its application in various dermatological conditions in practice.

This presentation delves into the fundamental concepts of Platelet-Rich Plasma (PRP), Platelet-Poor Plasma (PPP), and Platelet-Rich Fibrin (PRF), elucidating the key distinctions among these three therapeutic approaches. Platelet-Rich Plasma (PRP) is derived from the patient's own blood and processed to concentrate platelets, commonly

DAY TWO WEDNESDAY

6th March 2024

CONFERENCE HALL 1

DERMATOLOGY SCIENCES & RESEARCH

employed in fields such as orthopedics and dermatology to stimulate tissue healing, reduce inflammation, and promote tissue regeneration. On the other hand, Platelet-Poor Plasma (PPP) is a plasma type obtained after the removal of platelets during the preparation of PRP, characterized by a lower platelet concentration. Platelet-Rich Fibrin (PRF), similar to PRP, is derived from the patient's own blood, encompassing not only concentrated platelets but also fibrin and white blood cells. Prepared without the use of anticoagulants, the PRF preparation process differs from that of PRP.

09:45 - 10:00

Autologous Plasma Gel; Facts and Pearls for Practice

Ersan ÖN MD | Dermatologist, Treasurer General

Autologous platelet gel injections appear to be a cost-effective, safe, and well-tolerated technique for enhancing facial volume and skin density. The gel produces significant aesthetic correction of facial wrinkles and facial appearance and may be a solution for those seeking natural facial rejuvenation methods. Autologous platelet gel injections might be an alternative to costly HA fillers injections, at the same time having a stimulating effect on the skin and improving its condition. It may be a safe therapeutic solution for patients who cannot be qualified for HA treatments due to medical contraindications.

10:00 - 10:15

Psoriasis and Metabolic Syndrome

Abdullah Al Eisa MD | Consultant Dermatologist and Medical Director

Psoriasis is chronic skin disease relation of psoriasis with systemic disease is growing in recent years with a lot of medical literature support dermatologist should be aware of serious consequences of psoriasis association and when to refer and what proper investigation to do and when to refer to internist.

10:15 - 10:30

Exosomes and Hair Loss

Abdullah Al Eisa MD | Consultant Dermatologist and Medical Director

Exosomes very tiny particles secreted by Eukaryotic cell which discover more than 30 years recently the benefits of exosomes in medical field as new strong gun will discuss the effect of this modality on hair and the concern when we decide to use it also I ll show my personal experience with it.

10:30 - 11:00 Q & A / Break

DAY TWO WEDNESDAY

6th March 2024

CONFERENCE HALL 1

DERMATOLOGY SCIENCES & RESEARCH

Session 5: Pigmentation & Vitiligo

Chairperson: Manal Bosseila MD, Ali Singel MD, Fouz Hassan MD

11:00 - 11:15

The Many Faces of Bcc: Dermoscopic Identification

Manal Bosseila MD | Professor of Dermatology

Dermoscopy is now a well-established non-invasive diagnostic tool that improves sensitivity and specificity in diagnosing melanoma as well as non-melanoma skin cancer.

Dermoscopy aids in the identification of basal cell carcinoma by providing additional morphological information . By identifying specific characteristics like a spoke-wheel pattern or pigmentation resembling a maple leaf, it is important in differentiating pigmented BCC from other pigmented tumors. Experienced dermoscopists can often diagnose superficial BCCs and non-pigmented BCCs. Its value extends beyond the detection of more or less evident lesions as it provides a detailed analysis of the tumor's morphological features. Dermoscopy improves the clinical diagnosis of BCC, enabling its detection even at an early stage when the tumor is still clinically unrecognizable. It also provides additional significant information for guiding the management of the tumor, and is gaining a pivotal role in follow-up of treatment by spotting early recurrence of the tumor. Clinical Cases addressing the above-mentioned points will be presented.

11:15 - 11:30

Selecting the Appropriate Biologic in Psoriasis

Dalia Shaaban MD | Professor of Dermatology and Venereology

Psoriasis is a genetically determined, systemic immune-mediated inflammatory disease that affects predominantly the skin and joints. It is now recognized as a systemic disease that has a significant impact on quality of life. The treatment of psoriasis has undergone a revolution with the advent of biologic therapies. There are many types of biologics including: anti TNF-α, Il-12/IL/23 inhibitors, IL-23 inhibitors and IL-17 inhibitors. However, not every biologic treatment is effective and suitable to every psoriasis patient.

Psoriasis is a genetically determined, systemic immune-mediated inflammatory disease that affects predominantly the skin and joints. It is now recognized as a systemic disease that has a significant impact on quality of life. Patients with moderate to severe psoriasis are candidate for systemic therapy and phototherapy. The treatment of psoriasis has undergone a revolution with the advent of biologic therapies. There are many types of biologics including: anti TNF-α, Il-12/IL/23 inhibitors, IL-23 inhibitors and IL-17 inhibitors. However, not every biologic treatment is effective and suitable to every psoriasis patient. Appropriate selection of biologic for every type of psoriasis and for different conditions associated with psoriasis will be discussed.

DAY TWO WEDNESDAY

6th March 2024

CONFERENCE HALL 1

DERMATOLOGY SCIENCES & RESEARCH

11:30 - 11:45

The Efficacy and Safety of Micro-needling Combined with Tacrolimus versus Tacrolimus Monotherapy for Vitiligo Treatment: A Systematic Review and Meta-analysis

Hadeel Maaddawi MD | Medical Intern

Vitiligo is an autoimmune disfiguring skin disease that manifests as a non-scaly, amelanotic, chalky-white macule with distinct margins. Vitiligo is classified into two major classes: non-segmental vitiligo (NSV) and segmental vitiligo (SV) as they differ in their prognostic implications. The etiology of vitiligo is multifactorial and polygenic with autoimmune nature highly suggested as vitiligo is associated with other autoimmune diseases such as diabetes mellitus, thyroid disease, and alopecia areata. Genetics, environmental factors, oxidative stress, and cell detachment abnormalities are also associated factors in the pathogenesis of vitiligo. Vitiligo appears to be difficult to treat and satisfactory outcomes are challenging to achieve since treatment options cause some adverse events, carry a recurrence depigmentation rate, and appear to be resisted by some individuals. Combining tacrolimus with micro-needling (Mn) is one of the novel proposed methods to treat localized and stable non-segmental vitiligo.

Background: Vitiligo is a common disfiguring autoimmune disease that negatively impacts patients' quality of life. Tacrolimus is a topical immunomodulator medication that has been used successfully in treating vitiligo; however, based on recent studies, combination of topical tacrolimus with micro-needling suggests improved technique for drug delivery through stratum corneum. Objectives: The aim of this systematic review was to assess the efficacy and safety of micro-needling combined with Tacrolimus versus Tacrolimus monotherapy in treating vitiligo.

Materials & Methods: We searched Medline, Embase, and CENTRAL. We included randomized controlled trials (RCTs) that compared micro-needling combined with Tacrolimus versus Tacrolimus monotherapy for treating individuals diagnosed with vitiligo. We sought to evaluate the following outcomes: the 5-grade re-pigmentation scale or Physician's Global Assessment (PGA), histopathological assessment, and adverse events. The risk ratio (RR) was used to represent dichotomous outcomes whereas Odds ratio (OR) used for adverse events, and the data were pooled using the inverse variance weighting method.

Results: A total of 5 RCTs that enrolled 158 participants were deemed eligible. Administration of micro-needling combined with tacrolimus were significantly more efficacious than tacrolimus monotherapy in achieving improved re-pigmentation on PGA with a rate 75-100% (RR= 1.97, 95% CI: 1.35 to 2.86). Similarly, micro-needling combined with Tacrolimus has significantly increased the positive melanoblasts in histopathological assessment (RR= 2.11, 95% CI: 1.31 to 3.39). Regarding adverse events, micro-needling combined with Tacrolimus did not exhibit any significant difference than tacrolimus monotherapy (OR= 1.72, 95% CI: 0.10 to 29.36). Conclusions: This meta-analysis demonstrated that even though micro-needling combined with Tacrolimus is an innovative approach, it could be a promising modality as it showed a clinically and statistically substantial improvement in re-pigmentation of vitiligo sites with acceptable tolerability and safety profile.

11:45 - 12:00

Experience in Treating Vitiligo Patients at King Abdullah University Hospital (KAUH), Jordan

Diala Alshiyab MD | Associate Professor and Consultant Dermatologist

Vitiligo is a common acquired skin disorder affecting 0.4% to 2% of the world population. The management of vitiligo remains one of the most difficult challenges in dermatology.

Vitiligo is a common acquired skin disorder affecting 0.4% to 2% of the world population. The management

DAY TWO WEDNESDAY

6th March 2024

CONFERENCE HALL 1

DERMATOLOGY SCIENCES & RESEARCH

of vitiligo remains one of the most difficult challenges in dermatology. Ideally, management should focus on stopping the immune destruction of melanocytes, halting the depigmentation, stabilizing depigmented lesions, stimulating repigmentation and finally preventing relapses once the repigmentation is achieved. To date, there is no fully effective treatment for vitiligo. However, various treatment modalities have been reported, including topical therapies, UV therapy, depigmenting treatments, and surgical interventions. A proper diagnosis and careful initial assessment are the first step in managing patients with vitiligo. In this presentation, we will share our experience in treating vitiligo patients at King Abdullah University Hospital (KAUH).

12:00 - 12:15

Childhood Psoriasis

Jayakar Thomas MD | Emeritus Professor, Founder and National Chairman

Psoriasis is a common dermatosis that affects children, with approximately one third of all cases beginning in the first or second decade of life. An ongoing distorting skin sickness, psoriasis, in youth is probably going to make significant profound and mental impacts, and subsequently requires unique consideration. It has been reported that children's psoriasis is more likely to be itchy than adult psoriasis; plaques are moderately more thin, milder, and less textured; the guttate type is the typical presentation, and involvement of the face and flexures is common. Whether beginning in youth predicts a more serious type of psoriasis involves debate, it might cause huge dreariness especially on the off chance that it continues to backslide. Most kids have gentle type of psoriasis which can be by and large treated successfully with effective compounds, for example, emollients, coal tar, corticosteroids, dithranol, calcipotriol and so on, based on age and the affected locations. Narrow band UVB is the favoured type of phototherapy in kids for moderate to serious sickness or in patients not answering effective treatment alone. Internal treatments are saved for additional, extreme, and broad cases that cannot be controlled with skin treatment as well as phototherapy, for example, serious plaque type, unsound structures like erythrodermic and summed up pustular psoriasis and psoriatic joint pain. There are no controlled preliminaries of fundamental treatments in this age; most experience being with retinoids and methotrexate with positive outcomes. Cyclosporine is an effective short-term and intermittent medication for crisis management. There is an early encouraging involvement in the utilization of biologics (etanercept and infliximab) in youth psoriasis. Fundamental medicines as well as phototherapy have restricted use in youngsters because of aggregate portion impacts of medications, low acknowledgment, and chance of gonadal toxicity. More proof-based information is required about the adequacy and long-haul wellbeing of effective, phototherapy and foundational treatments in children.

12:15 - 12:30

Implications of Dilated Nail Bed Capillaries in Normal Looking Nails of Children with Mild Psoriasis – Pilot Study

Parimalam Kumar MD | Professor & Head of the Department of Dermatology

Introduction: Angiogenesis plays a major pathogenic role in psoriasis, and is enhanced in both involved and uninvolved skin. Early diagnosis of nail psoriasis is a challenge in clinically normal nails. Presence of dilated nail bed capillaries [DNBC] points to nail bed involvement, which may be an indicator of increased risk for development

DAY TWO WEDNESDAY
6th March 2024

CONFERENCE HALL 1
DERMATOLOGY SCIENCES & RESEARCH

of psoriatic arthritis. This pilot study was aimed at studying clinically normal looking nails of children with mild psoriasis for DNBC on dermoscopy. Objective: To analyse and evaluate the significance of DNBC of clinically normal nails in children with mild psoriasis and compare with normal controls. Materials and Methods: 32 children upto 12 years of age in two groups, 16 with mild psoriasis [A] and 16 controls [B], all having clinically normal looking nails were enrolled. Dermoscopy of all the 20 nails were done and findings recorded with reference to DNBC.

Results: Eleven in group A [68.75%] and one in group B [6.25%] had DNBC in two or more nails. The control with positive finding was a twin of a child with positive finding in group A. Dots and linear vessels were the most common findings observed. Fingernails showed more positive findings than toenails. Conclusion: Involvement of nail may provide clue to the diagnosis, predictive course of the disease, and appropriate management of psoriasis. Based on the findings of above study, there is evidence that DNBC are important signs towards nail involvement in children with psoriasis. If these findings are proved on a larger sample, dermoscopic examination can be recommended even for normal nails in children with suspected and confirmed diagnosis of psoriasis. This seems to be the first dermoscopic study in psoriatic children with clinically normal nails.

12:30 - 12:45

Efficacy and Safety of Oral Apremilast in Patients of Mild to Moderate Chronic Plaque Psoriasis

Ashba Nasir Cheema MD | Consultant Dermatologist

The basic aim of the study is to find the efficacy and safety of oral apremilast in patients of mild to moderate chronic plaque psoriasis and psoriatic arthritis. Material and methods: This prospective study was conducted in Department of dermatology and Rheumatology, Services hospital Lahore during 1st January to 30th June 2023. After approval from Hospital's Ethical Review Board, 40 patients were included in the study. Written informed consent and detailed history was taken from each patient along with PASI measurement and photographs. Patients get 30mg of tab Apremilast twice daily for 24 weeks. Dose was gradually built over a week to avoid diarrhea. Patients was assessed initially after a week and then after 2 weekly for a month and then one monthly. Photographs was taken on every follow up visit and patients will be assessed for PASI and for side effects. Results: Data were collected from 40 patients. Results showed a significant reduction in PASI scores from 12.5 ± 3.2 at baseline to 3.8 ± 1.5 at week 24, indicating substantial improvement in psoriasis severity. DLQI scores decreased from 15.7 ± 4.6 to 6.2 ± 2.3, signifying enhanced quality of life. 65% of patients with psoriatic arthritis met ACR response criteria. Apremilast was well-tolerated, with mild gastrointestinal symptoms in 10% of patients. Conclusion: It is concluded that, Apremilast's is a potential and useful treatment option for mild to moderate psoriasis and psoriatic arthritis. Key words: Patients, Quality, Psoriatic, DLQ1, Improvement.

12:45 - 13:00

Melanoma in Non-European Ethnic Population and Utilization of Radiological and Molecular Imaging in The Management of Melanoma in Aotearoa New Zealand

Umaima Khatoon MD | Medical Registrar

Melanoma in non-European ethnic population and utilization of radiological and molecular imaging in the management of Melanoma in Aotearoa New Zealand. Aim: To establish the epidemiology of melanoma in non-European ethnic populations in Southern Aotearoa, New Zealand and investigate the pattern of utilization

DAY TWO WEDNESDAY
6th March 2024

CONFERENCE HALL 1
DERMATOLOGY SCIENCES & RESEARCH

of sentinel lymphoscintigraphy (SLS), Computed, and Positron Emission Tomography (CT, PET/CT) in their management. Method: A retrospective review of the epidemiology, utilization of SLS, CT, and PET in the management of melanoma in non-Europeans from 2000-2020. Data was analysed from clinical records on patient demographics, melanoma histology, clinical management, follow up, and accessibility to imaging and follow up. Results: The epidemiology of melanoma in non-European population in the Southern region of NZ is 3 per 100000. Of 1411 melanoma cases, 38 of these were non-Europeans. The average age of this group was 60.6 years, and 46% were female. The time from diagnosis to tertiary intervention was 6.4 weeks. Histological characteristic of the melanoma was an average Breslow thickness of 2 mm, 68% had Clark level 2 or above and ulceration absent in 71%. Ninety percent of patients had wide local excision +/- SLS. The remission rate was 74%. Twenty-one percent of patients proceeded for SLS, 11% of which had a positive SLS, 50% had negative SLS. The mean time from diagnosis to SLS was 6.6 weeks. Thirty percent proceeded to staging CT, with a mean time from diagnosis to staging CT of 28 months. Sixteen percent proceeded for staging PET with a mean time from diagnosis to PET of 16 months. The average travel time for follow-up was 46.8. Seventy-six percent of patients were followed according to national guidelines. Majority of care was under Plastic or ENT surgeons. Conclusion: Melanoma in non-Europeans in the Southern region of NZ is 3 per 100000. Non-Europeans appear to have higher Breslow thickness and Clark level of invasion. Majority received imaging and follow up as per national guidelines. Most clinical management was not by Dermatologist. Long travel distances were involved.

13:00 - 14:00 **Q & A / Lunch Break**

Session 6: Hair
Chairperson: Mohamed Elazzab MD, Alia Al Mualla MD, Bakri Al Agraa MD

14:00 - 14:15

Borderline Leprosy is One of the Greatest Imitators in Dermatology
Mohammed Elazzab MD | Consultant Dermatologist & Chairman

- Borderline leprosy is characterized by annular skin lesion with a characteristic punched out inner border and slopping outer edge "Swiss cheese' 'appearance.
- Don't miss borderline leprosy in any patient presented with annular skin lesions.
- Consider type 1 lepra reaction (reversal reaction) in any leprosy patient which may be presented by only swelling, pain and tenderness in hands and feet.
- Slit skin smear may be more sensitive than biopsy in many cases.
- Don't miss to do slit skin smear once you suspect leprosy.
- An early slit skin smear test helps to early detection of leprosy cases and hence helps to prevent lifelong leprosy stigmata.
- This presentation will show some of leprosy cases that may be misdiagnosed by many physicians.

DAY TWO WEDNESDAY

6th March 2024

CONFERENCE HALL 1

DERMATOLOGY SCIENCES & RESEARCH

14:15 - 14:30

Topical Pentoxifylline; Metformin Versus Betamethasone in the Treatment of Alopecia Areata: A Clinical and Dermoscopic Study

Alaa Eldin Moubasher MD | Professor of Dermatology, Venereology and Andrology

Alopecia areata (AA) is a common hair loss disorder. Dermoscopy is an essential tool to monitor disease progress & recovery. Although many treatments are available, the need for an effective, convenient, safe & cost-efficient local therapy for patchy AA is still urgent. This forces researchers to innovate more treatment options for this disease. Pentoxifylline (PTX) has powerful anti-inflammatory actions & is used as an adjuvant in treating many skin diseases e.g. psoriasis. Metformin has potent immunoregulatory effects. Topical metformin was used successfully in treating skin disorders as melasma & acne.

To compare the efficacy & safety of topical PTX 2% gel; metformin 10% gel versus betamethasone valerate 0.1% cream, in treating patchy AA. Methods: Sixty patchy AA patients are recruited from the Dermatology Department clinic, Assiut University Hospital & randomly allocated in 3 groups (20 patients each): Group A receives betamethasone valerate 0.1% cream; group B receives PTX 2% gel & group C receives metformin 10% gel. All treatments are applied twice daily for 6 months or till recovery. Assessment is done monthly by photography, Severity of ALopecia Tool (SALT), dermoscopy, recording side effects & patients' satisfaction. Follow-up for 2 months after the end of treatment is done. Results: Comparison of the response and safety of each topical agent will be demonstrated

14:30 - 14:45

The Evidence Behind Topical Hair Loss Remedies on Social Media.

Reem Khater MD | Cosmetic Dermatologist, Consultant and laser Therapist

Hair loss affects a notable portion of the population and is a common chief concern in dermatology clinics. Misinformation on social media continues to grow in prevalence. It is important for all Dermatologists to be aware of the hair loss remedies that are commonly touted to patients online so that we may provide evidence based opinions to our patients.

With the rise of social media influence and ease of accessibility of information, patients often encounter and implement hair loss advice from sources other than medical professionals. Many of these recommendations include herbs and other natural extracts (i.e., rosemary oil, rice water, onion juice, garlic gel and others) as treatments. This presentation aims to investigate the evidence-based research behind these claims.

14:45 - 15:00

Antiandrogens and Hair: Update

Adel Alsantali MD | Consultant Dermatologist, Head of Dermatology Department

Androgenetic alopecia (AGA) is a common condition characterized by thinning of scalp hair. AGA is a multifactorial disease that carries a significant psychological burden with it. Dihydrotestosterone, the main pathogenic androgen in AGA, is produced by conversion of testosterone, which is catalyzed by the 5-alpha reductase (5-AR) isoenzyme family. Finasteride and dutasteride are inhibitors of these enzymes. Finasteride, which is a single receptor 5-alpha

DAY TWO WEDNESDAY

6th March 2024

CONFERENCE HALL 1

DERMATOLOGY SCIENCES & RESEARCH

reductase inhibitor (5-ARI), acts by blocking dihydrotestosterone (DHT). Dutasteride, a dual receptor DHT blocker, has a higher potency than its predecessor, finasteride. In this presentation we will discuss various types of anti-androgens (Spironolactone, cyproterone acetate, flutamide, Finasteride and dutasteride), the evidence of effectiveness of them and possible side effects of antiandrogens used to treat AGA.

15:00 - 15:15

What's New and Hot in Alopecia Areata Management?

Adel Alsantali MD | Consultant Dermatologist, Head of Dermatology Department

Alopecia areata is a common, non-scarring, autoimmune disorder affecting any hair-bearing area. It is estimated to be the presenting complaint in 2% of dermatologic consultations, and can appear at any age although it is more common in young patients. Treatment depends on several factors, such as extent of the disease and age. Current treatments, including topical, systemic and injectable interventions show varying response and frequent relapses reflecting the unmet clinical need. Thus, the new emerging concepts and therapeutic approaches, including Janus kinase inhibitors are eagerly awaited. Traditional and emerging therapies of AA will be discussed, in order to provide physicians with guidance for AA management. An overview of the up-to-date pathophysiology and the underlying signaling pathways involved in AA together with diagnostic and therapeutic recommendations will be provided.

15:15 - 15:30

Comparison of Efficacy and Safety of Biogenetically engineered Exosomes versus Platelet Rich Plasma in Patients of Androgenetic Alopecia: A Randomized Control Trial

Alina Abbass MD | Senior Registrar

Androgenetic alopecia (AGA) is a common condition that affects up to 50 percent of males and females. It is characterized by progressive loss of terminal hair of the scalp any time after puberty. It has a very typical distribution in both males and females. In males, hair loss is mostly on vertex and frontotemporal regions, while in women the frontal hairline is mostly involved with diffuse hair loss at the crown and top of head.1 Currently, FDA approved treatments are topical minoxidil and oral finasteride. But due to its adverse effects, most patients refuse to take this drug. Platelet rich plasma (PRP) is currently effective alternate therapy used very commonly. PRP is autologous concentration of platelets, having multiple growth factors in their alpha granules, injected intradermally in scalp.2 There is another emerging treatment modality which is exosomes. Exosomes are 30-150nm extracellular vesicles (EVs) derived from various mesenchymal stem cells (MSCs). Exosomes contain various proteins, nucleic acids and various cell mediators and growth factors. They have same biological properties as that of their parent derived cell along with advantages of small size, easy penetration of biological membranes, low immunogenicity, easy storage, and no tumorization. Recently, exosomes have been genetically modified so that they can exhibit better therapeutic properties, such as enriched active ingredients, targeted delivery, and physiological barrier to penetration.3 Because of their properties they have roll in hair growth. Exosomes are providing promising results in patients of androgenetic alopecia.4 Both PRP and exosome therapy has found to be effective in various studies across the globe. Very less literature is found on comparison of these two treatment modalities specially in the world.5 Key Words : Exosomes, Platelet Rich Plasma, Androgenetic Alopecia METHODS It is a randomized clinical trial going on in Dermatology department of Services hospital Lahore, Pakistan. After getting approval

DAY TWO WEDNESDAY

6th March 2024

CONFERENCE HALL 1

DERMATOLOGY SCIENCES & RESEARCH

from Ethical Review Board, all patients of androgenetic alopecia having ages between 18 and 70 years and of either gender are included. Patients with platelets disorders, thrombocytopenia, and those using anti-platelet therapy are excluded. Use of pharmacological therapeutics targeting AGA as Finasteride®, antiandrogens, topical Minoxidil®, prostaglandin analogues, or imunocompromised patients are not enrolled. Pre-treatment assessment is done by hair pull test, global physician assessment, patient global assessment and hair density by trichoscopy of the involved areas of scalp. The patients are randomized into two groups by paper lottery method. After regional nerve block under aseptic conditions, Group A patients are injected exosomes intradermally at a strength of 2 to 10 billion particles/5ml, at a dose of 0.1 ml/cm2 of scalp, and group B patients are injected PRP intradermally in scalp.Exosomes used are GFCCELLTM EXO SCALP KIT. PRP is prepared under aseptic precautions, around 10ml of blood is collected from the median cubital vein and is transferred into a sodium citrate tube. Then the tubes are rotated in a centrifuge machine at 1500 RPM for 10 minutes. This first centrifugation is called "soft spin," which separates the blood into 2 layers: the lower RBC layer; the upper acellular plasma layer which is further subdivided into an upper layer which contains platelet poor plasma and a lower layer which contains platelet rich plasma also known as the buffy coat. The buffy coat along with the plasma was collected with a pipette and transferred into another test tube. This tube was again subjected to a second centrifugation at 4000 RPM for 10 minutes, called "hard spin." This allows the platelets to settle at the bottom of the tube. Both the upper layer containing platelet poor plasma and the lower layer of the PRP was collected in another clean tube. The plasma is filled into insulin syringe and then injected evenly into the affected areas of the scalp. Multiple PRP injections of 0.1 mL were given at each site in a linear pattern 1 cm apart. The patients are followed monthly after the first treatment session for 6 months. The primary efficacy endpoints of this study are decrease in hair fall assessed by positive and negative hair pull test, hair regrowth assessed by Global physician assessment and patient global assessment on scale of three (<50% as poor, 50-75% as good response, 75% as excellent response) and number of hairs are calculated by trichoscopy. Demographic data and pretreatment parameters are recorded on a predesigned proforma. Data is entered and analyzed using SPSS vs 20. RESULTS As it is an ongoing trial, 20 patients have completed the study including 10 each in exosomes and PRP group. Rest of the patients are in follow up for another two months. Mean age of patients is 38 ± 15. Among 20 patients, 16 patients (80%) are male and 4 (20%) are females. At the end of 6 months follow up, 8 out of 10 patients in group A have achieved a negative hair pull test as compared to 4 out of 10 in group B. Mean hair density before treatment was 110 ± 28.36/cm2 which increased to 177.20 ± 15.91/cm2 in group A and 140 ± 28.36/cm2 in group B after 6 months of treatment. On a scale of three, mean scores of physicians and patient global assessments were 2.15 ± 0.47 and 1.90 ± 0.62 for group A and 1.47 ± 0.47 and 1.60 ± 0.62 for group B, respectively. Few patients are still under process of data collection whose data will be completed by the end of December 2023. So complete results of this study including comparative tests and p-values will be shared by then. CONCLUSION Although current clinical evidence is not complete, yet it is concluded from this study that the exosomes not only have a role in hair growth but also are better tolerated than platelet rich plasma in regrowing hair in androgenetic alopecia. (I am sending this abstract in anticipation of a good response and will be pleased to share any further details as required.)

15:30 - 15:45

Dermoscopy Guided Biopsy

Amal Wagih MD | Specialist of Dermatology

This review aims to evaluate the effectiveness and benefits of dermoscopy guided biopsy compared to traditional biopsy methods, Dermoscopy guided biopsy is a technique used in dermatology to improve the accuracy of skin

DAY TWO WEDNESDAY
6th March 2024

CONFERENCE HALL 1
DERMATOLOGY SCIENCES & RESEARCH

biopsies. The review will analyze various studies and clinical trials that have investigated the use of dermoscopy guided biopsy in different skin conditions. The review will assess the impact of dermoscopy guided biopsy on diagnostic accuracy and patient outcomes. Additionally, potential limitations and challenges associated with this technique will be discussed. The findings from this review will provide valuable insights into the utility of dermoscopy guided biopsy in clinical practice and guide future research in this field.

15:45 - 16:00 **Q & A / Break**

Session 7
Chairperson: Amani Abdulla Alfalasi MD, Badreya Alshehhi MD, Samir Almahfoud MD

16:00 - 16:15

A Descriptive Study of Patterns of Genital Dermatoses in Patients Attending A Tertiary Care Centre in South India and Assessment of Quality of Life, Depression and Anxiety in Them
Anupa Job MD | Assistant Professor

Background:Disorders affecting the external genitalia can be classified into venereal and non-venereal dermatoses. Research focusing on assessing quality of life in patients with genital dermatoses and evaluating psychological morbidity in them is currently limited. Aims and objectives:To evaluate the quality of life in patients with various genital dermatoses and to estimate the prevalence of anxiety and depression among them. Materials and methods:Patients aged 18 and above with genital dermatoses were recruited.Caution was executed to exclude patients with known psychiatric comorbidities,malignancies and prior diagnosis of venereal diseases before their assessment.Following a detailed clinical evaluation of these venereal and non-venereal dermatoses,Quality of life was assessed using Finlay Dermatology Life Quality Index questionnaire.Further, evaluation of anxiety and depression was done(for those willing to undergo evaluation for the same)using Hamilton rating scale for anxiety and depression. Results:A total of 100 patients with genital dermatoses were seen and 25 different dermatoses were identified.There were 58 males and 42 females in this study.Genital dermatoses had small,moderate and large impact on quality of life in 79 patients.Advanced education status,co-existing cutaneous diseases and multiple symptoms were associated with poor quality of life.No correlation was found between quality of life and parameters such as sex,age,marital status,socioeconomic status,duration, high-risk behaviour,venereal versus non venereal dermatoses.The mean anxiety and depression scores translated to mild anxiety and depression in the sub group of 60patients who consented to psychiatric evaluation Conclusion:Assessing quality of life and addressing anxiety and depression must be included in standard of care holistic management of patients with genital dermatoses.

16:15 - 16:30

A Case of Bullous Pemphigoid in an Immunosuppressed Renal Transplant Child- a Paradoxical Phenomenon?
Wedad Abdelrahman MD | Consultant Dermatologist

We report an interesting case of a 12-year-old girl presenting with a sudden widespread bullous rash. Her background renal history included a single dysplastic kidney secondary to HNF1 beta syndrome with MODY type 5. She received a deceased donor kidney transplant aged 20 months and her kidney function was stable (eGFR

DAY TWO WEDNESDAY

6th March 2024

CONFERENCE HALL 1

DERMATOLOGY SCIENCES & RESEARCH

64ml/min/1.73m2) with tacrolimus and prednisolone for the past 10 years. 4 months prior to presentation, in view of her rising HbA1C (6.5%), she began weaning prednisolone, and mycophenolate mofetil (MMF) commenced. At this point her serum creatinine had gradually risen too.

Over a 2-week period, she developed a widespread itchy bullous eruption but otherwise remained systemically well with low inflammatory markers.

A skin biopsy for histology and direct immunofluorescence revealed typical features of bullous pemphigoid. She was treated with high dose prednisolone for 2 weeks followed by a gradual steroid wean which enabled her skin to achieve remission. Her eGFR is currently above baseline (57ml/min. 1.73m2) and an allograft biopsy done was suggestive of antibody mediated rejection.

We believe this is the first case of bullous pemphigoid reported for a child with HNF1B-MODY type 5. Bullous pemphigoid is rare in adolescence. Although cases have been reported on bullous pemphigoid in renal transplant recipients, this has been in the context of failing transplant grafts and weaning immunosuppression. In this case, she was started on MMF, therefore had increased her background immunosuppression.

16:30 - 16:45

The Frequency of Different Causes of Facial Melanosis in A Series of 2020 Cases

Waqas Saad MD | Consultant Dermatologist. Head of Dermatology Department

Facial melanosis has a great psychological and cosmetic impact on the life of every patient. There are many etiological factors involved in its etiopathogenesis commonly melasma. Objective: To gather all patients with facial melanosis and try to categorize them into different diseases or groups of diseases. Patients and methods: This is a cross-sectional descriptive study where all patients with facial melanosis were gathered together during the period from 2014-2023 years. All patients with Fitzpatrick skin type 111 and 1V. Full demographic information was taken. A clinical assessment was performed and skin biopsies were done for histopathological evaluation. Results: A total of 2020 cases with facial melanosis was analyzed and the following frequencies were recorded: melasma and melasma-like butterfly lichen diffuse planus actinicus in 1220 (61%) cases, frictional melanosis in 270 (13.5%), post-inflammatory melanosis in 210 (10.5%), butterfly lichen planus actinicus in 180 (9%), black hair dye facial melanosis in 100 (5%), nevus of Ota in 20 (1%), Phytophotodermatitis in 10 (0.5%) gazelle eye like facial melanosis in 10 (0.5%) patients. Conclusion: Facial melanosis is a major health problem with great psychological impact where melasma, frictional melanosis, and post-inflammatory melanosis constitute the commonest diseases. All share increased melanin stores in the epidermis and dermis.

16:45 - 17:00

Holistic Needs Assessment and Skin Cancer in The Uk: What Can We Learn? A National Survey

Sami Raza MD | Doctor

The rising incidence of skin cancer, with particular respect to melanoma, is a palpable concern for dermatologists. With more than 16,000 new cases of melanoma in the UK yearly (1), it there is a compelling need to concert efforts to tackle this, particularly against the backdrop of climate change. Although there is an arsenal of tools to treat skin cancer, efforts should be consolidated in its prevention, which can take form of the use of sunscreen, amongst

DAY TWO WEDNESDAY

6th March 2024

CONFERENCE HALL 1

DERMATOLOGY SCIENCES & RESEARCH

other options. A relatively cheap and accessible product, sunscreen can play a central role in reducing the risk of the incidence of skin cancer. 1. Cancer Research UK [Internet]. 2023 [cited 2023 Sep 20]. Melanoma skin cancer statistics. Available from: https://www.cancerresearchuk.org/health-professional/cancer-statistics/statistics-by-cancer-type/melanoma-skin-cancer

We distributed a semi-structured online questionnaire to the mailing list of a melanoma patient support group in the UK. We collected data for a period of 6 weeks, from July to August 2023. We canvassed 571 responses in total, with 82.5% (n=471) female respondents and 17.5% (n=100) male respondents. Most respondents (60.1%; n=343) previously had melanoma, and 17.2% (n=98) previously had non-melanoma skin cancer. With regards to wearing sunscreen, nearly half of respondents (48.7%; n=278) apply it every day, compared to 42% (n=240) who apply it when it is sunny only. 5.8% (n=33) apply it occasionally, with 2.8% (n=16) applying it when they can remember. Only 0.7% (n=4) never apply sunscreen. 79.2% (n=452) knew how much sunscreen to apply, compared to 20.8% (n=119) who did not. Those that did know how much to apply, the most popular answer in measuring the amount of sunscreen was finger-lengths (38.7%; n=216). With regards to frequency of application, 32% (n=180) apply it once a day, with 28.5% (n=160) apply it twice a day. Most respondents (64.2%; n=360) have been applying sunscreen for more than 10 years. The most popular cosmetic benefit of sunscreen use respondents were aware of is reduced redness on sun exposed areas of the skin (73.2%; n=418). However, when asked if they would be persuaded to use sunscreen if manufacturers marked the cosmetic benefits of sunscreen, 57.1% (n=326) were already aware of the benefits; 27.7% (n=158) indicated it would, compared to 15.2% (n=87) who indicated it would not. With regards to knowledge of burn time, 50.3% (n=287) were not aware of this, compared to 49.7% (n=284) who were. There is an overwhelming consensus that more education is needed regarding the importance of sunscreen, with 96.7% (n=552) agreeing with this statement. The most important factors for respondents when choosing a sunscreen included: SPF more than 50 (52.4%; n=299), SPF more than 30 (52.2%; n=298), and recommendation by a dermatologist (46.8%; n=267). 45.9% (n=262) noted price is also an important factor, and 41.9% (n=239) stated texture is also a key aspect. We found that less than half of respondents (48.7%; n=278) found the labelling of sunscreen confusing This study demonstrates a respectable level of knowledge concerning sunscreen and its benefits, and this provides much needed reassurance. However, we would urge dermatologists to further increase the use of sunscreen via opportunistic health promotion in clinic, as our study highlights this would be a key factor in choosing sunscreen. We would urge pharmaceuticals to consider simpler package, and to consider pricing points of sunscreen, as this is essential to reducing the healthcare inequity attributed to the wide-ranging polarity of different socio-economic backgrounds which may leave those with low income without the means to purchase sunscreen.

17:00 - 17:15

Nutritional Deficiencies in Patients with Inherited Epidermolysis Bullosa

Olga Orlova MD | Head of the Center

Congenital epidermolysis bullosa (CEB) is a group of genetically and clinically heterogeneous diseases characterized by a tendency to form blisters and/or erosions on the skin and mucous membranes with minimal trauma [1]. VBE occurs due to impaired synthesis of skin proteins due to genetic mutations in more than 16 genes. In CEB, aberrant proteins that are located in the dermo-epidermal junction zone do not perform their functions, which leads to skin stratification between the epidermis and the dermis and is accompanied by the formation of blisters. The disease can be inherited both autosomal dominant and autosomal recessive. There are four main types of CEB: simple, junctional, dystrophic and Kindler syndrome. The severity of the course of CEB can vary from

DAY TWO WEDNESDAY
6th March 2024

CONFERENCE HALL 1
DERMATOLOGY SCIENCES & RESEARCH

mild to extremely severe. The treatment of the disease is symptomatic, including skin care and wound surfaces, adequate anesthesia, nutritional support, as well as prevention and treatment of complications. Among the latter, for example, in dystrophic CEB, there is often a lesion of the mucous membranes of the oral cavity, which leads to microstomy and ankyloglossia, lesion of the mucous membranes of the esophagus with the development of strictures. Due to damage to the mucous membrane of the eye, corneal erosion develops, which can lead to irreversible loss of vision. With junctional and dystrophic types of CEB, as well as with Kindler syndrome, there is a high risk of damage to the organs of the genitourinary system with the development of urethral strictures. A frequent complication of severe forms of CEB is limb deformity with the development of contractures of large joints and fusion of toes and hands. Multiple complications of CEB in combination with the severity of the skin process led to the development of nutritional insufficiency and, as a consequence, to the development of anemia, secondary osteoporosis, growth retardation and puberty. Nutritional insufficiency is a multifactorial problem in CEB and occurs due to an imbalance between the needs for nutrients and their intake into the body. The severity of nutritional disorders and lack of essential nutrients and energy are directly proportional to the severity of CEB, which is typical for dystrophic and junctional type of disease due to loss of protein, electrolytes and other blood components due to a large area of skin lesion.

Background: Inherited epidermolysis bullosa (IEB) is a group of genetically and clinically heterogeneous disorders characterised by a tendency to form blisters and/or erosions on the skin and mucous membranes with minimal trauma. The clinical manifestations of IEB are not limited to skin and mucosal lesions and can range from mild to extremely severe, depending on the form of the disease. Patients with IEB often have nutritional deficiencies due to multiple factors. Extensive skin erosion is associated with loss of macro- and micronutrients, resulting in increased catabolic and anabolic repair processes, which in turn require increased energy and protein requirements. The aim of this study was to evaluate the nutritional status of children with simple and dystrophic IEB, to assess the severity of the disease course, and to calculate the correlation between the Birmingham Epidermolysis Bullosa Severity Score (BEBS) and the z-scores of anthropometric indicators. Material and Methods: 59 children aged 3-17 years (Me 8 ± 3.94) with simple (n=25) and dystrophic (n=34) forms of IEB were included in the study. Physical development indicators were assessed using the WHO Anthro software, including a set of z-scores: weight-for-age z-score (WAZ), height-for-age z-score (HAZ), BMI-for-age z-score (BAZ). The BEBS scale was used to assess disease severity. RESULTS: WAZ, HAZ and BAZ indicators in children with epidermolysis bullosa simplex were within normal limits in most cases: WAZ (Me 0.5 ± 0.94), HAZ (Me 0.23 ± 0.94), BAZ (Me 0.83 ± 1.5). In patients with dystrophic form of IEB, WAZ was within normal limits only in 29.5% (n=10), HAZ - in 65% (n=22), BAZ - in 26.3%. Values of the BEBS scale ranged from 1 to 24 (Me 3.5 ± 6.5) in children with the simple form of IEB and from 5 to 51.5 (Me 25.2 ± 10.5) in patients with the dystrophic form. Nutritional deficiency was inversely correlated with BEBS score ($p<0.005$). Conclusions: The performed analysis shows obvious disturbances of nutritional status and nutrient deficiencies in children with dystrophic form of IEB. Despite the modern possibilities of using therapeutic foods, severe forms of IEB are still difficult to be subjected to dietary therapy.

17:15 - 17:30

Efficacy of Combined Treatment with Adipose Tissue Stem Cell Exosomes (Asce) and Microneedling for Facial Skin Aging: A 12-week Prospective, Randomized, Split-face Study

Taewook Jeoung MD | General Practitioner

Recent studies have reported promising results of mesenchymal stem cell therapies for skin aging. However, in the use of mesenchymal stem cells, some drawbacks including rarely possible tumorigenicity and immunogenicity,

DAY TWO WEDNESDAY

6th March 2024

CONFERENCE HALL 1

DERMATOLOGY SCIENCES & RESEARCH

and low engraftment rates have limited their widespread clinical use. Exosomes are nano-sized (30 – 200 nm in diameter) lipid bilayered vesicles secreted by most cell types. Adipose stem cell exosomes (ASCEs) are emerging as effective cell-free therapeutic agents to treat a variety of skin aging. Materials / method: 1. ASCE were isolated from the serum-free conditioned media by sequential filtration and characterized as recommended by the International Society for Extracellular Vesicles (ISEV). 2. The effects of ASCE were demonstrated from a variety of in vivo & in vitro studies against dermal fibroblasts and others. 3. A 12-week, prospective, randomized, split-face, comparative study was conducted. Twenty-eight individuals underwent three treatment sessions separated by 3-week intervals and were followed up for 6 weeks after the last session. At each treatment session, ASCEs were administered to one side of the face, and normal saline solution was administered to the other side as a placebo, followed by the microneedling application to both sides of the face.

The Global Aesthetic Improvement Scale score was significantly higher on the ASCE-treated side than on the control side at the final follow-up visit ($p = 0.005$). • The difference between the two treatments was not significant at week 3 ($p = 0.202$). • But, it became statistically significant at week 6 ($p = 0.023$). • At the final follow-up visit (week 12), 13 cases (46%) had a GAIS score of 3, 4 cases (14%) scored 4, and 4 cases (14%) scored 5 for the ASCE side; whereas 13 cases (46%) scored 3, 2 cases (7%) scored 4, and 2 cases (7%) scored 5 for the control side. • These results indicate that the ASCE side exhibited a significantly greater improvement in facial skin aging than the control side at the final follow-up visit ($p = 0.005$). Objective measurements obtained by different devices confirmed greater clinical improvements in skin wrinkles, elasticity, hydration, and pigmentation on the ASCE-treated side than on the control side. The results of the histopathological evaluation were consistent with the clinical findings. No serious adverse events were observed.

17:30 - 17:45

Role of Direct Immunofluorescence on Tzanck Smear and Plucked Hair in the Diagnosis of Pemphigus Vulgaris

Kehkshan Tahir MD | Associate Professor

Pemphigus vulgaris is an autoimmune, fatal, intra epidermal blistering disorder affecting skin and mucosa. It is an immunologically mediated disease in which autoantibodies are directed against desmoglein 3 & 1 resulting in loss of adhesions between keratinocytes. Clinically it is characterized by flaccid blisters and erosions that usually starts in oral mucosa and then involves rest of the body. Diagnosis of the disease should be established earlier in the course of the disease due to its life-threatening nature. Suprabasal clefting & acantholysis are histopathological hallmarks of the disease. Acantholysis also extends in the outer root sheath (ORS) of hair follicle which is structurally analogous to epidermis. Demonstration of immune deposits has been the gold standard for the diagnosis of Pemphigus. Direct immunofluorescence of the peri-lesional skin demonstrates intercellular deposition of IgG with or without C3 in the epidermis. But this requires expensive and sophisticated equipment and specific expertise, in addition it is not always possible to take biopsy as in mucosa, flexural areas and in children. Moreover, this facility is not available in every setting. Tzanck smear is a rapid and useful test for the diagnosis of pemphigus vulgaris. The presence of acantholytic cells in the smear indicates but cannot confirm the diagnosis so it is not a specific test. DIF performed on the Tzanck smear indicating immunoglobulin deposits on the acantholytic cells makes it a specific, inexpensive and easy diagnostic test for the diagnosis of pemphigus vulgaris. Outer root sheath of anagen hair is structurally similar to epidermis of skin. The process of acantholysis in pemphigus vulgaris seen in epidermis also involves the wall of hair follicle. Pemphigus specific immunofluorescence pattern found in the skin has also been demonstrated in the ORS of a plucked hair follicle. DIF on hair is easier and less invasive as compared

DAY TWO WEDNESDAY

6th March 2024

CONFERENCE HALL 1

DERMATOLOGY SCIENCES & RESEARCH

to DIF on perilesional skin. Taking a sample for DIF from oral or skin biopsy is a relatively invasive and unpleasant method for the patient. It is further complicated by the need for repeating the test until positive test results are obtained causing reluctance in many patients to accept it. Therefore, finding a less invasive way for collecting an appropriate substrate would be helpful.

METHODS: Thirty patients of pemphigus vulgaris diagnosed clinically with histopathological confirmation were included in the study. Patients of any age and of either sex having active disease and with any duration of disease were enrolled after taking an informed consent. The disease was considered to be active if patients had new blisters for the last 2 weeks. Patients with other forms of pemphigus and vesiculobullous disorders were excluded from the study. DIF was performed on Tzanck smear & plucked hair of each of the patient. Tzanck smear was prepared by scraping the base of each blister/ erosion. Material obtained was then smeared on glass slide. Four slides were made & air dried. Smears were stained with FITC conjugate antihuman IgG, IgM, IgA & C3 for 30 minutes. These slides were then rinsed in phosphate buffer saline (PBS) solution 3 times for 10 minutes each, mounted in buffered glycerol and examined under fluorescent microscope. Bright green fluorescence at margin of cells in case of individual cells and in intercellular region in case of group of cells was considered as positivity of smear for pemphigus vulgaris. Hairs were plucked from the scalp using rubber tipped artery forceps. Four anagen hair were selected, placed on glass slide and washed in PBS for 10 minutes. They were then incubated with antihuman IgG, IgM, IgA & C3 FITC conjugates for 1 hour. At the end of procedure, they were washed again with PBS with 3 cycles of 10 minutes each, mounted in buffered glycerol and examined under fluorescent microscope. Intercellular deposition of immunoglobulins in ORS of plucked hair was considered positive for the diagnosis of pemphigus vulgaris. RESULTS: A total of 30 patients of pemphigus vulgaris were studied. Among these patients there were 21 (70%) males and 9 (30%) females with mean age of 36 years. There were 11 (37%) patients who were having the disease for greater than 3 months and 19 (63%) patients had the disease for less than or equal to 3 months. Patients with both mucosal and cutaneous involvement were 23 (77%) and those with disease limited to mucosa were 7 (23%). There were 16 (53%) patients of pemphigus vulgaris who had lesions on the scalp while 14 (47%) patients did not show any scalp involvement. DIF was positive on Tzanck smear in 23 (76.7%) of patients. DIF on plucked hair was positive in 27 (90%) of patients. In 20 (67%) of the patients both tests were positive. Chi square test was used to compare the diagnostic value of both these tests using the Exact's method. There was no significant difference between the diagnostic value of these tests suggesting that both tests are useful to diagnose pemphigus vulgaris ($p = 0.436$). In order to determine the reliability of each test, the results of DIF on Tzanck smear and on plucked hair were compared separately against an expected 'n' using Chi-square test - exact method with the hypothesis that the results were positive in all the patients. The result indicated that DIF on plucked hair is more reliable ($p = 0.071$) as compared to DIF on Tzanck smear ($p = 0.001$) in the diagnosis of pemphigus vulgaris. Patients with duration of disease less than & equal to 3 months showed DIF positivity on Tzanck smear in 16 (84.2%) and on plucked hair in 17 (89.5%) patients. DIF was positive on Tzanck smear in 7 (63.6%) patients and on plucked hair in 10 (90.9%) patients with disease of greater than 3 months duration. There was no statistically significant difference on DIF positivity in respect of disease duration. Patients with mucocutaneous involvement had higher DIF positivity on Tzanck smear & plucked hair as compared to those with only mucosal involvement. But this difference was not found to be statistically significant. Patients with scalp involvement showed higher DIF positivity on plucked hair 15 (55.6%) as compared to the patients who did not have any scalp lesion 12 (44.4%). CONCLUSION: Direct immunofluorescence on Tzanck smear and plucked hair is a simple, painless and non-invasive test in diagnosing pemphigus vulgaris. DIF on hair is more reliable as compared to DIF on Tzanck smear. Hence, It is recommended that DIF on plucked hair should be used for the routine diagnosis of pemphigus vulgaris.

DAY TWO WEDNESDAY

6th March 2024

CONFERENCE HALL 2

THERAPEUTICS/NEW DRUGS/CASE PRESENTATIONS

INTERNATIONAL CLINICAL CASE PRESENTATION AND COMPETITION

Session 6 : Junior Dermatologists Competition

Jury Members: **Zbigniew Ruszczak MD** | Chairman, International Clinical Case & Poster Presentation & Competition
Shaden Abdelhadi MD | Co-Chairman, International Clinical Case & Poster Presentation and Competition
Mohammed El Banhawy MD | Senior Consultant Dermatologist

09:00 - 09:10

Case Presentation
Afnan Samy MD | Resident Dermatologist

Leukocyte adhesion deficiency type 1 (LAD-1) is a rare, life-threatening autosomal recessive primary immunodeficiency syndrome caused by the mutation of integrin b2 (CD18) gene. The most distinctive features of LAD-1 are persistent leukocytosis with neutrophilia and recurrent serious bacterial or fungal infections of the skin and soft tissues. Many patients with LAD I have a history of skin ulcerations that are frequently diagnosed as ''pyoderma gangrenosum'' . Skin ulceration can begin as early as the first year of life , or be delayed until later in childhood. The ulcers are chronic, recurrent, and multiple.They often begin as pustular lesions, with a rapid progression to an exquisitely tender ulceration with an erythematous or violaceous rim (12). Healing is slow, with paper-thin scars, either hyperpigmented or hypopigmented. Different methods of therapy have been used in the treatment of patients with LAD-1 presenting with PG with varying efficacy, such as systemic glucocorticoids, IVIG, cylcosporine, infliximab but Allogeneic hematopoietic stem cell transplantation (HSCT) is the only definite treatment option recommended in LAD-1.

2 -year- old female patient referred from pediatric department with chronic painful ulceration at gluteal region 1 month ago. Although, she received several broad spectrum antibiotics and surgical debridement, there was progression of skin lesions. The lesions had appeared as erythematous pustule that progressed rapidly into necrotic ulcers. Histologically, the lesions showed ulceration with a diffuse lymphohistiocytic infiltrate, but with a relative sparsity of neutrophils. Pateint had past history of recurrent chest infection and subsequent investigation revealed persistent neutrophilia and complete absence of CD11a/CD18 b2 integrins on surface of neutrophils confirming diagnosis of Pyoderma gangrenosum like lesions in a child with congenital leucocyte adhesion deficiency syndrome type 1. The ulcers respnded to systemic steroid and intravenous immunoglobulins.

09:10 - 09:20

A Rare Case of Cutaneous Metastasis from Poorly Differentiated Thyroid Carcinoma
Nafkot Girum MD | Assistant professor of Dermatovenereology

Cutaneous metastasis from internal malignancy is relatively uncommon and rarely may be the presenting sign of an internal malignancy. It shows spread of malignant cells to the skin by metastatic spread of distant primary tumor. Occurs in 1-10% of patients with metastatic disease and in 0.5 – 1% of the cases it is the presenting feature. Cutaneous metastasis from thyroid carcinoma is rare. Scalp is most common site of thyroid carcinoma metastasis to the skin. Cutaneous metastasis is usually suggestive of disseminated disease and indicate a correspondingly

DAY TWO WEDNESDAY

6th March 2024

CONFERENCE HALL 2

THERAPEUTICS/NEW DRUGS/CASE PRESENTATIONS

poor prognosis. The estimated mean survival after the diagnosis of cutaneous metastases is 50% at 6 months and survival is only about 3 months in patients with disseminated skin metastases.

Report of the case A 28 years old female presented to the dermatology department with multiple, round, ulcerated nodules on the scalp of 6 months and small round skin-colored subcutaneous nodules on the neck, abdomen, back and chest. The lesions were painless but had associated intermittent itching and burning sensation. In association she has easy fatigability, recent significant weight loss and night sweating. At presentation she had anterior neck mass which was painless and moves upon swallowing. Otherwise has no previously diagnosed known chronic medical illness. On physical examination she was chronically sick looking with multiple ulcerated nodules, plaque and tumorous lesions with overlying hemorrhagic crust on the scalp with areas of alopecia overlying the lesions and has multiple firm skin-colored subcutaneous nodules on the chest, back, neck, axilla and on bilateral breast. There is mobile, firm, non-tender multinodularanterior neck mass which moves with swallowing. She had no lymphadenopathy in all accessible areas. There is no palpable mass on the breast, abdomen and pubic area. The laboratory investigations (CBC, LFT, RFT, TFT) were all in the normal range. Chest X-ray showed metastasis and abdominal ultrasound was normal. Microscopic features FNAC from the scalp, thyroid and soft tissue shows cellular aspirate composed of cohesive pleomorphic round to oval cells with abundant bluish cytoplasm at areas forming hemorrhagic background. With a conclusion of poorly differentiated carcinoma considering Follicular thyroid carcinoma. Skin biopsy was done from 2 sites, a 4mm punch biopsy from the subcutaneous nodule and incisional biopsy from the scalp lesion. The 4mm Punch Biopsy showed bland looking maturing epidermis and dermis. There are focal deposits of hyperchromatic round to oval cells with eosinophilic cytoplasm arranged in cohesive aggregates within the subcutaneous tissue. Focal area of vascular invasion seen and the incisional Biopsy showed bland looking epidermis. Dermal subcutaneous deposits of cohesive aggregates of pleomorphic round cells with eosinophilic cytoplasm. The patient was diagnosed with cutaneous metastasis from poorly differentiated carcinoma considering the top differential Thyroid ca. She was linked to the oncology unit of Black lion hospital. Patient deferred follow up and passed away after 3 months of initial presentation. Discussion Cutaneous metastasis represent involvement of the skin by metastatic spread of a distant primary tumor. Metastasis to the skin occurs as a result of lymphatic or haematogenous dissemination of tumor. The most common sources of cutaneous metastases are, in generally accepted order of frequency: breast, Melanoma, lung, colon, stomach, upper aerodigestive tract, uterus and kidney. Develop an average of 36 months after the initial diagnosis of the primary malignancy. In about 0.5–1% a cutaneous metastasis is the presenting feature of internal cancer. The thorax is the most common site for cutaneous metastasis, as a result of the high frequency of metastatic breast and lung cancers. The scalp is another common site, for metastases from lung, kidney, and breast tumors. On the scalp, the metastatic tumors typically present as single or multiple firm nodules, but scarring alopecia, known as alopecia neoplastica, can be seen. Thyroid cancer is the most common type of endocrine-related cancer. Spread of thyroid cancer outside the neck (metastases) is rare, occurring in between 1.2 and 13% of patients. Metastatic sites include cervical lymph nodes, lungs, bone. Metastases to the brain, breast, liver, kidney, muscle, and skin are rare. Diagnosis is based on clinicopathologic assessment of the involved skin. Histopathologic features help identify the source of the primary tumor. Microscopically, the collection of neoplastic cells, which usually resemble their malignancy of origin, seen in the dermis and/or subcutaneous tissue. Additional features, such as tumor cells in an "Indian filing" pattern, lymphovascular invasion, necrosis, and a tumor-free "grenz zone," are also helpful for the diagnosis of metastatic skin lesion. Immunohistochemical staining is often required to achieve the correct diagnosis in poorly differentiated carcinoma. Treatment needs a multidisciplinary approach, including medical and surgical oncologists, radiation oncologists, and mental health care providers. Treatment follows the regimen appropriate for the primary metastatic malignancy. Removal of skin lesions by simple excision may enhance the patient's quality of life but has little effect on the final outcome that is dictated by the primary cancer. For functional, palliative, cosmetic outcomes local treatment is indicated. Local treatment options include Imiquimod

DAY TWO WEDNESDAY

6th March 2024

CONFERENCE HALL 2

THERAPEUTICS/NEW DRUGS/CASE PRESENTATIONS

cream, Liquid nitrogen cryotherapy, Photodynamic therapy, Excision, Carbon dioxide laser therapy, Pulsed dye laser therapy, Topical and intralesional chemotherapy and cytokines. When malodorous, topical metronidazole solution can be applied via cotton gauze or pump spray once to twice daily. Debridement can be done if lesions bleed or crust. Systemic therapies are indicated for Immuno- or chemotherapy- responsive tumors. Treatment follows the regimen appropriate for the primary metastatic malignancy. Electrochemotherapy combines the administration of nonpermeable or poorly permeable highly intrinsic cytotoxic drugs with the application of short and intense electric pulses to the tumors to facilitate the drug delivery into the cancer cells. In conclusion, Cutaneous metastasis is usually suggestive of disseminated disease and indicate a correspondingly poor prognosis. Thus, early diagnosis and treatment is mandatory.

09:20 - 09:30

What is Wrong with this Child Scalp?

Aiah Atiah Elfeky MD | Resident of Dermatology, andrology and venerology

Abstract of a case of cutis verticis gyrata in seven years old child cutis verticis gyrata is a descriptive term for a condition of the scalp manifesting as a convoluted folds and furrows formed from thickened skin of the scalp resembling cerebriform pattern classified into primary essential in which no other abnormality was found, and non-essential which was named cutis verticis gyrata -intellectual disability syndrome or secondary cases associated with different diseases

We have a case of 7 years old male child presented with hypertrophied hard intradermal navus dated since birth with continuous changes in morphology taking the shape of convoluted folds suggesting most probably secondary case of cutis verticis gyrata diagnosis of the underlying cause was reached out clinically and confirmed by biopsy wide scale of work out was done to exclude primary essential and non-essential causes treatment depends on properly establishing diagnosis in order to exclude or treat underlying process in our case , surgical decision was the best .

09:30 - 09:40

Bloom Syndrome with Growth Hormone Deficiency: A Rare Association of A Rare Syndrome

Hadir Shakshouk MD | Assistant lecturer of Dermatology, Andrology and Venereology

Bloom syndrome is a very rare autosomal recessive disorder, first described in 1954. About 250 cases have been reported to date. The principal features of the syndrome are short stature, a photosensitive telangiectatic erythema of the face and a marked predisposition to the development of malignant disease, notably acute leukemia. Bloom syndrome is caused by a mutation in the BLM gene, which encodes the RecQ helicases. Being essential for DNA replication, defects in RecQ helicases lead to impaired DNA repair, particularly after exposure to ultraviolet light with elevated risk of photosensitivity. The lack of DNA repair is also likely to be the reason for the high incidence of malignancy in these patients as they accumulate mutations. Follow up of those patients is required for early detection of malignancy.

A 3 year old girl presented with persistent erythematous facial rash of 2 years duration, which was exacerbated by sun exposure. Her mother is a known systemic lupus (SLE) patient. The patient had short stature 4.5 below standard deviation for her age. She had narrow, bird-like facies with small mandible and pointed nose, high

DAY TWO WEDNESDAY

6th March 2024

CONFERENCE HALL 2

THERAPEUTICS/NEW DRUGS/CASE PRESENTATIONS

arched palate, and dolichocephalic skull. Dermatologic examination revealed characteristic facies with diffuse erythema extending onto the forehead, nose and malar areas with thin atrophic scarring and telangiectasias. Our differential diagnosis included congenital photosensitivity disorders; Congenital erythropoietic porphyria, SLE, Rothmund Thomson syndrome, Bloom syndrome and Cockayne syndrome. Detailed examination showed multiple café-au-lait macules of varying sizes, measuring from 1 to 4 cm in diameter, over the trunk, back, and thighs. Also, multiple hypopigmented macules of 1 to 3 cm in diameter were noted over the trunk and thighs. Routine hematologic investigations were normal. Immunologic studies including ANA, Anti-Ro and Anti-La were negative excluding systemic lupus. Biochemical profile of blood and urine was negative for porphyrins. Plain X-rays of long bones showed delayed bone age. Basal Growth hormone level was low and remained low after stimulation test. The association of growth hormone deficiency with Bloom syndrome is exceedingly rare. Treatment with GH can potentially be dangerous, as the inherently high incidence of malignancies in Bloom syndrome may be exacerbated by GH. This case report raises important questions: Is there a causal association of GH deficiency and Bloom syndrome? Is GH treatment appropriate in the rare scenario of Bloom's syndrome with GHD?

09:40 - 09:50

Pagetâs Disease of the Breast Mimicking Chronic Eczema

Selamawit Yigletu MD | Assistant Professor of Dermatology and Venereology

Paget's disease of the breast is a rare form of breast cancer accounting for approximately 1-3% of all breast cancers. It mainly affects in postmenopausal women, with an average age of onset of 56 years. An underlying instiu or invasive breast carcinoma is present 88% of the cases, although mostly without the presence of palpable mass or mammographic abnormality. The initial eczematous nature of the disease can cause a delay in diagnosis. Immunohistochemistry has a major role in differentiating it from Bowen's disease of the nipple –areola complex, which resembles it both histologically and clinically. The surgical treatment of Paget's disease is controversial (radical or conservative), with/with out radiotherapy and is generally guided by the stage of the underlying breast cancer.

Here, we report mammary Paget's disease in an HIV infected 50 years old female patient, from Addis Ababa, Ethiopia. The patient who has been on ART, for past 20yrs, with a recent viral load of 20 presented with painful eczematous lesion involving the right areola and nipple, which was partially responsive to topical steroids of one-year duration. Examination revealed, erythematous eroded plaque with crustation and retraction of right nipple, as well as bilateral axillary lymphadenopathy. No mass identified on ultrasound of the breast, but bilateral axillary lymphadenopathy suspicious for malignancy was seen. Biopsy of the lesion demonstrated infiltration of the epidermis with Paget cells, with positive staining for HER-2 on immunohistochemistry. The patient underwent modified radical mastectomy with axillary lymph node dissection with a final diagnosis of micro invasive breast cancer. She was put on postoperative adjuvant chemotherapy. In conclusion, prompt biopsy of unilateral, treatment unresponsive eczema of nipple and areola is necessary in order to avoid undue delay in diagnosis and thereby a worse prognostic outcome

DAY TWO WEDNESDAY

6th March 2024

CONFERENCE HALL 2

THERAPEUTICS/NEW DRUGS/CASE PRESENTATIONS

09:50 - 10:00

Pancreatitis, panniculitis and polyarthritis- A Rare Presentation

Akriti Agrawal MD | Senior Resident

Pancreatitis-Panniculitis-Polyarthritis (PPP) syndrome is characterized by the development of erythematous nodules typically affecting the lower extremities as well as poly or oligoarthritis in the setting of pancreatitis. The pathologic hallmark is sub cutaneous fat necrosis of the affected tissues. Although the pancreatic pathology is considered causative, abdominal symptoms are often mild or absent. This leads to misdiagnosis, delay of appropriate therapy and worsening of prognosis.

A 38-year-old male presented with complaints of multiple painful skin lesions over body since past 1 week. Lesions started over the bilateral lower limbs and progressed to involve the trunk and upper limbs within the next few days. There was associated history of intermittent grade fever and joint pain involving bilateral knee and ankle joints. There was no history of ulceration from lesions, any abdominal pain, dyspnea or any other comorbidities. Examination revealed multiple erythematous tender indurated nodules over trunk and limbs. Investigations showed anemia, leukocytosis with neutrophilia, elevated serum aspartate aminotransferase, serum amylase (950 U/L) and lipase (421.4 U/L) levels. Histopathology revealed lobular panniculitis with subcutaneous fat necrosis. Ziehl-Neelsen staining for acid fast bacilli, GeneXpert for MTB and CBNAAT were negative. CA19-9 was within normal limits. Synovial fluid and blood cultures were negative. Computed tomography of abdomen did not reveal significant findings. Based on raised serum pancreatic enzymes, histopathology suggestive of pancreatic panniculitis and multiple peripheral joint involvement, patient was diagnosed as a case of Pancreatitis, panniculitis and polyarthritis (PPP) syndrome. Patient was started on oral antibiotics and supportive management and underwent arthrotomy and lavage for knee and ankle joints. Pancreatitis, panniculitis and polyarthritis (PPP) is a rare syndrome presenting with a triad of elevated pancreatic enzymes, lobular panniculitis and non-infective polyarthritis. It is hypothesized that release of pancreatic enzymes, especially lipase, due to underlying pancreatic disease results in fat necrosis and secondary inflammation in multiple sites such as visceral organs, joints, and the skin. Panniculitis presents with soft or coarse subcutaneous erythematous knots of the extremities, predominantly of the lower limbs and can develop spontaneous ulcerations and oily sterile discharge. Polyarthritis occurs mostly symmetrically for hand, ankle and knee joints. For one-fourth of patients with the triad of PPP, arthralgia is the leading symptom The main therapy of the PPP-syndrome is the treatment of pancreatitis. Parenteral nutrition, antibiotic treatment and anti-inflammatory along with surgical interventions are recommended. The delay in diagnosis of PPP syndrome results in poorer prognosis of patients. We wish to emphasize this rare syndrome and highlight the importance of early diagnosis and management in such cases.

10:00 - 10:10

Diving Deep into Yao Syndrome: Causes, Symptoms, and Treatment

Zeinah AlHalees MD | Associate Consultant

Yao syndrome, previously referred to as NOD2-associated autoinflammatory disease, is a complex condition characterized by recurrent episodes of fever, myalgia, arthritis, dermatitis, sicca-like symptoms, swelling in the distal extremities, as well as gastrointestinal symptoms.1,2 It was first described in 2011 in a cohort of adult patients who presented with clinical features resembling Blau syndrome but lacked the classic triad of granulomatous dermatitis, uveitis, and arthritis associated with this disorder. 7 Yao syndrome was recently categorized as a genetically transitional disease in which a mutation is required but is insufficient to cause disease. It is associated

DAY TWO WEDNESDAY

6th March 2024

CONFERENCE HALL 2

THERAPEUTICS/NEW DRUGS/CASE PRESENTATIONS

with mutations in the NOD2 gene. This gene is located on chromosome 16 and encodes a protein known as nucleotide-binding oligomerization domain-containing protein 2 (NOD2).3,7 Notably, NOD2 gene mutation has also been found to be associated with a group of diseases including Blau syndrome, sarcoidosis, and Crohn's disease.4 One common feature among this group of systemic autoinflammatory diseases is the occurrence of inflammatory episodes with a benign autoimmune workup.5

Yao syndrome typically presents spontaneously in adulthood, and a common cutaneous manifestation includes the presence of erythematous patches and plaques.4 Histopathologically, various findings have been described including mixed lymphocytic and neutrophilic infiltrates, spongiotic dermatitis, and granulomatous changes.7 The diagnoses of Yao syndrome is based on the fulfillment of specific diagnostic criteria with the major criteria including the occurrence of at least two periodic flares of fever, dermatitis, or both. In addition to the major criteria, there are several minor criteria that can contribute to the diagnosis, such as oligo- or polyarthralgia/arthritis, distal extremity swelling, abdominal pain or diarrhea, sicca-like symptoms, and pericarditis or pleuritis. The molecular criterion involves identifying mutations in the NOD2 gene, specifically IVS8+158 or R702W, or other rare variants. Additionally, the diagnosis requires a negative autoimmune workup as well as the exclusion of other autoinflammatory syndromes. A patient must fulfill at least two major criteria, one minor criterion, the molecular criterion, and meet the exclusion criteria.6,7 Regarding therapeutic approaches, a significant proportion of Yao syndrome patients exhibit favorable responses to glucocorticoid treatment. Other options include sulfasalazine, and in the cases of refractory symptoms, interleukin 1 (IL-1), interleukin 6 (IL-6), and tumor necrosis factor (TNF) -alpha inhibitors were found to be effective alternatives. 7 We describe two cases of individuals who have experienced longstanding episodic dermatitis accompanied with systemic symptoms (fever, arthralgia, myalgia, GI symptoms) and a negative autoimmune workup. These patients had previously received alternative diagnoses (neutrophilic dermatosis in context of ulcerative colitis, and pancreatic insufficiency) and underwent various treatments that proved to be ineffective. Subsequently, genetic testing revealed the presence of a mutation in the NOD2 gene, which, when combined with their clinical presentation, led us to a diagnosis favoring Yao syndrome and treated them accordingly. Given its rare occurrence, Yao syndrome can be quite challenging to identify, underscoring the necessity for further research into its underlying characteristics. When encountering patients with unexplained episodic fevers, dermatitis, and other systemic manifestations such gastrointestinal symptoms, it becomes crucial to entertain the possibility of an autoinflammatory process, particularly one linked to a NOD2 mutation. A comprehensive evaluation that includes skin biopsies, as well as autoimmune and genetic analyses, should be actively pursued. Here, we present two cases of Yao syndrome, which contribute valuable insights to our continuously evolving comprehension of this condition. These cases can serve as a resource for healthcare professionals, aiding them in recognizing and effectively managing this complex disorder.

References 1. Yang X, Wu D, Li J, Shen M, Zhang W. A Chinese case series of Yao syndrome and literature review. Clin Rheumatol. 2018;37(12):3449-3454. doi:10.1007/S10067-018-4274-0/METRICS 2. Yao Q, Zhou L, Cusumano P, et al. A new category of autoinflammatory disease associated with NOD2 gene mutations. Arthritis Res Ther. 2011;13(5). doi:10.1186/AR3462 3. Ogura Y, Inohara N, Benito A, Chen FF, Yamaoka S, Núñez G. Nod2, a Nod1/Apaf-1 family member that is restricted to monocytes and activates NF-kappaB. J Biol Chem. 2001;276(7):4812-4818. doi:10.1074/JBC.M008072200 4. Esse I, Kincaid C, Horton L, Arnold JD, Mesinkovska NA. Yao syndrome: Cyclical folliculitis, fevers, and abdominal pain. JAAD Case Reports. 2023;35:71-73. doi:10.1016/J.JDCR.2023.01.039 5. Yao Q, Shen M, Mcdonald C, Lacbawan F, Moran R, Shen B. NOD2-associated autoinflammatory disease: a large cohort study. Rheumatology (Oxford). 2015;54(10):1904-1912. doi:10.1093/RHEUMATOLOGY/KEV207 6. Yao, Q., & Shen, B. (2017). A Systematic Analysis of Treatment and Outcomes of NOD2-Associated Autoinflammatory Disease. The American Journal of Medicine, 130(3). Retrieved from http://dx.doi.org/10.1016/j.amjmed.2016.09.028 7. Esse I, Kincaid C, Horton L, Arnold JD, Mesinkovska NA. Yao syndrome: Cyclical folliculitis, fevers, and abdominal pain. JAAD Case Reports. 2023;35:71-73.

DAY TWO WEDNESDAY

6th March 2024

CONFERENCE HALL 2

THERAPEUTICS/NEW DRUGS/CASE PRESENTATIONS

10:10 - 10:20

Atypical Presentations of Cutaneous Leishmaniasis

Shashika Chandraratne MD | Acting Consultant Dermatologist

Cutaneous leishmaniasis (CL) is an important tropical disease, with significant socio-economic and public health impacts, particularly concerning non-resolving lesions or lesions in the face and mucosa. CL is endemic in Sri Lanka with a rapid spread across different regions mainly in North-central, Central, North-western, and Southern provinces. Anuradhapura, Polonnaruwa, Hambantota, Kurunegala, and Matara districts are the areas recorded the highest number of cases with the highest incidence per 100,000 persons seen in Hambantota district3, as of a recent study. CL in Sri Lanka is known to be caused by Leishmania donovani zymodeme MON-375, which leads to cutaneous disease. Confirmed cases of Visceral Leishmaniasis in Sri Lanka are rare. Typical CL is an asymptomatic lesion over an exposed part of the skin which remain more than four weeks duration. Classic morphologies are papule, nodule, plaque with volcanic type central ulceration or crust formation (Picture 1). Unattempt lesion or a lesion with surgical intervention will progress to an asymptomatic ulcer. Ulcer extending to the periphery implies another differential or intervention (picture 2). Picture 1 Picture 2 Objectives of the study are to identify the atypical manifestations of Cutaneous Leishmaniasis and to discuss the possible causes giving rise to such presentations.

Main objective is to identify the atypical presentations of CL and their prevalence. New patterns of clinical manifestations are to be identified. Materials and Methods Cross sectional study design with systematic sampling for randomization of data was used in the study. Consented patients' pictures were taken for the assessment. 256 patients were selected for the analysis. Results 220 adult patients and 36 children were included to the study. Most of the lesions were seen over exposed skin of face, upper limb, lower limb and few lesions over non-exposed parts of trunk. Mucosal extension and lip lesions were noted in four patients. Atypical type of facial lesion was noted over nose with induration in an elderly patient. Pyoderma gangrenosum like ulcerative lesions were noted over leg in three patients. Erysepeloid type lesions and Vegetative type lesions were noted in few patients. Lymphatic spread was noted in one upper limb lesion. Conclusion Limited number of atypical CL lesions were seen and most of the appearances were due to interventions or changes occur with day today activities. Knowing of the different types of atypical `lesions are very important to come to the diagnosis in remote settings. Author affiliations 1. Acting Consultant Dermatologist - District base Hospital Dambulla, Sri Lanka 2. Medical officer - District base Hospital Dambulla, Sri Lanka Key words Cutaneous Leishmaniasis Pyoderma gangrenosum Leishmania donovani.

10:20 - 10:30

Angiolymphoid Hyperplasia with Eosinophilia : Is it Vascular or Reactive?

Nivvedhetha S. MD | Senior Resident

Angiolymphoid Hyperplasia with Eosinophilia is a benign vasoproliferative condition that is characterized by infrequent occurrences. It is a relatively rare entity and is also known as Epitheloid hemangioma. It is known to occur in any age group and in both males and females. Eventhough the exact etiology of this condition is unknown, various hypotheses has been proposed. One is the vascular hypothesis, which is supported by associated Arterio-venous shunt and preceding trauma in some cases. Latest theories suggest that the increase in the level of the hormone Renin in the presence of AV shunts, contributes to the proliferation of blood vessels. Another theory is the Lymphoproliferative hypothesis, which is supported by the presence of lymphocytic infiltrate histopathologically in almost all cases and also the recurrent nature of the tumor. Some authors have reported associations with HUmanherpes virus 8, Human T lymphocytic viru and HIV. Clinically, the patient presents with

DAY TWO WEDNESDAY

6th March 2024

CONFERENCE HALL 2

THERAPEUTICS/NEW DRUGS/CASE PRESENTATIONS

red to purple, epidermal, dermal or subcutaneous papules or nodules. Lesions typically are seen in the head and neck region, although it might occur in other areas like extremities, trunk, penis, vulva, inguinal folds and even mucosal involvement may be seen, in nasal, oral or gnital mucosa. Few cases have been reported to involve internal organs and arteries. Patients might frequently report symptoms like pain, pruritus or bleeding. About one in five cases may present with an associated eosinophilia. Histopathology of the lesion shows angiomatous lesions with abundant proliferating blood vessels lined by prominent endothelial cells. A diffuse infiltration of lymphocytes and accompanying few eosinophils may be observed. The treatment options for this condition includes topical therapies like Steroids, Calcineurin inhibitors and agents like Timolol. Systemic agents like Retinoids, steroids, pentoxifylline have been tried with minimal success. Reports of successful management with oral methotrexate and thalidomide have been reported in case of orbital ALHE. Surgical sxcision, laser therapies, cryotherapy and radiotherapy has also been tried. Inspite of the various modalities, this condition has proved to be a highly recurrent condition.

This report is about a 25-year-old pregnant female, who came with multiple reddish skin lesions over her right ears and postauricular region for 5 months. The patient, who reported when she was in her third trimester, started developing the lesion at the end of her first trimester. Patient observed a increase in the number and size of the lesions in the following period. This is her first pregnancy and the patient had no history of similiar lesions previously. Apart from associated pruritus, she had episodes of bleeding from the lesion. No systemic symptoms reported since the onset of the lesion. On examination, patient had multiple erythematous to purplish, non-pulsatile, smooth papules over the right ear concha, posterior conchal prominence and in the right post auricular margin as well. No lymphadenopathy in the patient. On further imvestigations, the absolute eosinophil count of the patient was slightly elevated, amounting to 420 cells/cu. mm. A skin biopsy was done and it showed focal spongitoic changes in the epidermis. In the dermis, proliferating capillaries with plump endothelial cells arranged in a lobular pattern was seen. This was accompanied by a lymphocytic infiltrate and few eosinophils were observed. Owing to the pregnant status of the female, topical therapy with Timolol was initiated. Patient later went into labour and delivered a healthy baby. During the follow-ups during her postpartum period, patient reported no change in the lesion size or number but had improvement in the symptoms. No bleeding episodes occurred after initiation of therapy. During her last clinical visit, when she was 8 months into her postpartum period, there was no decrease or increase in the size and number of lesions. Pregnancy as we all know is a hyperestrogenic state in which increase in incidence of many vascular tumors have been observed. This case alongwith few previously reported cases where in Angiolymphoid Hyperplasia with Eosinophilia, developed for the first-time during pregnancy, is a valuable argument in favour of the vascular hypothesis of this condition. However, the absence of spontaneous regression in this case, as opposed to previous such reports in pregnant females, should also be kept in mind.

10:30 - 10:40

An Unexpected Cause of Recurrent Sustained Viral Skin Infection

Hadir Shakshouk MD | Assistant lecturer of Dermatology, Andrology and Venereology

Recurrent or severe viral skin infections can be a harbinger of primary immunodeficiency. The T lymphocyte–specific protein tyrosine kinase (Lck) is a key component of the TCR signaling machinery. On the basis of its function, LCK gene can be the underlying culprit in patients with severe combined immunodeficiency.

A 7 year old boy presented with multiple crusted lesions and superficial erosions on his buttocks and right popliteal fossa. Lesions were not responding to topical nor systemic antibiotics. A skin biopsy revealed acantholysis, some keratinocytes demonstrated viral cytopathic changes in the form of margination of the nuclear chromatin,

DAY TWO WEDNESDAY

6th March 2024

CONFERENCE HALL 2

THERAPEUTICS/NEW DRUGS/CASE PRESENTATIONS

multinucleation and nuclear inclusions. A diagnosis of varicella infection was made. He received oral acyclovir with mild improvement. He also had a history of repeated chest infections. After pediatrics consultation, chest CT was done which showed bronchiectasis. The patient presented after 1 month with vesicular skin lesions suggestive of chicken pox. He also had fever and poor general condition, he was admitted and given IV acyclovir with good improvement. Given the recurrent and severe viral infection together with repeated chest infections, immunodeficiency was suspected. Routine laboratory investigations were normal. HIV antibody was negative. Immunoglobulin profile (IgA, IgE, IgG and IgM) was also normal. CD profiling for T and B lymphocytes was significant for reduced CD4 and CD 8 T-lymphocytes. These data were indicative of a profound T-cell immunodeficiency. Genetic testing with whole exome sequencing revealed LCK deficiency. Another 5-year-old girl presented with extensive verruca plana on the trunk and extremities. She also had repeated chest infections with hospital admissions. Her work up was similar to the first patient and whole exome was diagnostic for LCK deficiency. These 2 cases highlight the significance of LCK gene in viral skin infections. Defects in LCK increase patients' susceptibility to common viruses. Recurrent or persistent viral skin infections can be the feature that drives a diagnostic evaluation for primary immunodeficiency, which should be considered in such settings.

10:40 - 11:00 Q & A / Break

Session 7 : Resident Dermatologists Competition - Part 1

Jury Members:
Zbigniew Ruszczak MD | Chairman, International Clinical Case & Poster Presentation & Competition
Shaden Abdelhadi MD | Co-Chairman, International Clinical Case & Poster Presentation and Competition
Mohammed El Banhawy MD | Senior Consultant Dermatologist

11:00 - 11:10

Is Basaloid Follicular Hamartoma a New Additional Criterion to Nevoid Basal Cell Carcinoma Syndrome?
Sara Affara MD | Dermatologist

Nevoid basal cell carcinoma syndrome, or (Gorlin syndrome), is a rare autosomal dominant inherited disorder that is characterized by the development of multiple basal cell carcinomas (BCC). It features widespread associated developmental defects as well. It is caused by defects in hedgehog signaling which result in constitutive pathway activity and tumor cell proliferation. Basaloid follicular hamartoma (BFH) is a benign adnexal neoplasm that clinically appears similarly BCC. A recent article by the American Journal of Dermatopathology suggested that BFHS and NBCCS may fall along a disease spectrum with a shared genetic profile (PTCH1 germline mutation) rather than being two separate entities.

50 years old female presenting by multiple gradually progressive pigmented painless lesions distributed over face and trunk, of 10 years duration. Patient fulfilled diagnostic criteria of nevoid basal cell carcinoma syndrome (NBCCS); having multiple types of BCCs confirmed histopathologically, palmar keratotic pits and large mandibular keratocyst diagnosed and being enucleated by maxillofacial surgery. CT brain showed calcification of falx cerebri and bilateral tortuous optic nerves with minimal hydrops. Her son has positive history to mandibular keratocyst enucleation 2 years ago. Patient presented by another clinically pigmented lesions where dermoscopy demonstrated non-specific features. Histopathologically, it was composed of cords and strands of bland basaloid cells extending from distorted hair follicle with loose stroma, confirming the diagnosis of basaloid follicular

DAY TWO WEDNESDAY

6th March 2024

CONFERENCE HALL 2

THERAPEUTICS/NEW DRUGS/CASE PRESENTATIONS

hamartoma (BFH). Most important pathologic differential diagnosis is infundibulocystic BCC. After 6 months follow up, the patient presented by another clinically suspicious BCC lesions by dermoscopy. Will this patient be operated surgically every 6 months or is she candidate for systemic chemotherapy to guard against further disease progression?

11:10 - 11:20

Self-Mutilating Behavior in A 2-Year-Old Girl Unveiling the Diagnosis of A Rare Entity

Fida Anjum MD | Resident Dermatologist

Midface toddler excoriation syndrome (MiTES) is a newly identified condition that has been linked to a PRDM12 gene mutation. Clinically, MiTES presents with infantile onset excoriations and long-lasting scratch sequelae over the midface with a preference for nasal bridge. We report a 2-year-old girl who presented with MiTES.

Case discussion: A 2 year old girl born of non-consanguineous marriage, presented with itchy lesions on her face which appeared since the child was of 1 1/2 years of age. Her parents reported repeated scratching of the nose and surrounding areas. There was associated sleep disturbances in the child. There was no developmental delay present. On cutaneous examination, bilaterally symmetrical lichenified lesions were present over the bridge of nose and adjacent areas, along with multiple excoriation over the central portion of face.Child was constantly scratching the nose even during clinical examination. Differential diagnosis of Midface toddler excoriation syndrome,Dermatitis artefacta,neurotic excoriations,Lesch-Nyhan syndrome were considered.After detailed evaluation, diagnosis of Midface toddler excoriation syndrome (MiTES) was made. The child was prescribed emollients, topical and systemic antibiotics, and topical anaesthetic applications and moderate improvement in clinical appearance was noted. Conclusion: This case reinforces the fact that a child with infantile onset, pruritic skin lesions over midface should arouse the suspicion of MiTES as these patients can present to paediatricians/ dermatologists/ psychiatrists in clinical practice.

11:20 - 11:30

Non-surgical Treatment of Verrucous Hyperplasia on Amputation Stump

Sajeda Alnabelsi MD | Resident

verrucous hyperplasia, also known “papillomatosis cutis lymphostatica” is a rare condition which shows multiple, irregular warty papules and plaques but histologically no evidence of viral warts. It has been suggested that verrucous hyperplasia results from persistent stump edema, usually when the distal stump is unsupported in the prosthesis socket. The process is reversible if external compression is applied in combination with adequate control of bacterial infection and edema. Prosthetic adjustments usually help with this condition.

A 35 year old male patient presented with raised skin lesions which grouped in plaques with demarcated borders on the lower limbs amputation stumps for duration of 5 years. he had to undergo a bilateral below knee surgical amputation at age of six because of congenital deformities. since that he used prosthesis to enable him to perform his daily activities, replacing it from time to time. the lesion started as warty-like lesions on the right side, then developed on the left one after two years. he was treated externally as common warts with keratolytic and liquid nitrogen, but there is no benefit. then the lesions started to ooz pus and bloody fluids, and became black in color with crusts. Examination: multiple brown to black colored hyperkeratotic papules forming well demarcated

DAY TWO WEDNESDAY

6th March 2024

CONFERENCE HALL 2

THERAPEUTICS/NEW DRUGS/CASE PRESENTATIONS

asymptomatic plaques on the amputation stumps. examination of the skin in other areas, hair and nail was normal. no edema was found in the lower limbs Investigations: fungal infection was investigated: the result was negative. affected skin biopsy shows acanthosis, hyperkeratosis, parakeratosis, papillomatosis, unspecific dermal infiltration, lymphatic and blood vessels dilation and proliferation. we recommended the patient to apply external compression, and adjusting the prosthesis, and the result was disappearing the lesions after 7 months without any medications.

11:30 - 11:40

Eccrine Angiomatous Hamartoma: Unveiling An Uncommon Dermatological Entity - A Case Report

Jomol John MD | Junior resident

Eccrine angiomatous hamartoma (EAH) is a rare and benign cutaneous lesion that arises from the hamartomatous proliferation of eccrine glands and vascular structures. It occurs frequently at birth or during childhood, rarely appearing in adulthood. Clinically, the colour of EAH may be flesh-coloured, blue-brown, or reddish, and it may occur as a nodule or plaque, usually solitary, on the extremities.

This case report presents a unique instance of EAH in a 32-year-old female patient who presented with hyperpigmented, slow-growing swellings on the left ankle for 15 years associated with itching and purulent discharge. Clinically suspected to be a deep fungal infection, the tissue sample was sent for histopathological examination. Histopathological examination of the excised lesion showed a lesion composed of dilated and congested vascular channels with focal extension into the epidermis and vascular proliferation in the dermis and subcutis. The dilated vascular channels are capillary-sized and closely related to eccrine sweat glands, confirming the diagnosis. The rarity of EAH, its atypical presentation, and its clinical resemblance to other cutaneous lesions lead to misdiagnosis, contributing to a delay in appropriate management. This case report emphasises the importance of recognising EAH and highlights the significance of an accurate diagnosis. Further collaborative efforts and reporting of such cases are warranted to better comprehend the pathogenesis and improve the management of this rare cutaneous entity.

11:40 - 11:50

Childhood Granulomatous Perioral Dermatitis

Balaqis Alsaadi MD | Dermatology resident

Childhood granulomatous periorificial dermatitis (CGPD), considered a clinical variant of perioral dermatitis, typically affects prepubertal children of African descent. It is a condition of unknown etiology characterized by the presence of a monomorphic yellow-brown papular eruption limited to the perioral, perinasal, and periocular regions that histopathologically shows a granulomatous pattern. This disorder should be differentiated from other conditions as granulomatous rosacea, sarcoidosis, and lupus miliaris disseminatus faciei. We report a case of a 8-year-old boy who presented with monomorphic perorificial papules on the face, since two months.

DAY TWO WEDNESDAY

6th March 2024

CONFERENCE HALL 2

THERAPEUTICS/NEW DRUGS/CASE PRESENTATIONS

11:50 - 12:00

1 in a Million: A Boy with Silvery Hair

Jaswandi Shirodkar MD | Resident Doctor

Introduction: Griscelli Syndrome is a rare condition with a prevalence of less than 1 in a million. There are 3 types, namely type 1 – 3, caused due to gene mutations in MYO5A (Type 1), RAB27A (Type 2) and MLPH (Type 3). Type 1 may have neurological abnormalities due to an abnormal Myosin Va which plays a crucial role in neuronal structure and function. Type 2 is the most common type and is associated with immunological abnormalities such as hemophagocytic lymphohistiocytosis, which is fatal unless treated with a bone marrow transplantation. It is caused due to a defective melanosome-anchoring complex in melanocytes affecting the cytolysis caused by T lymphocytes and NK cells. Type 3 presents only with partial albinism (pigmentary dilution) with normal neurological and immune systems. Only 13 cases have been reported till 2016. It must be differentiated from similar conditions such as Chediak Higashi, Elejalde's Syndrome and Hermansky Pudlak Syndrome.

Case history: A young boy of age 3 years, born out of a 2nd-degree consanguineous marriage was brought by his mother with complaints of silvery white hair on his scalp, eyebrows and eyelashes since birth. Some of the hair became brownish as his age advanced. He gave no history of recurrent illnesses, failure to thrive or delayed milestones. There was no history suggestive of neuropsychiatric impairment. He gave a positive family history of similar complaints in a distant relative. On examination, all the hair on his scalp, eyebrows, eyelashes and body hair were silvery white to translucent brown in colour. Both the irises were dark brown and he had normal vision. He had no neurological deficits. IQ was normal. No signs of infection were present. No organomegaly. No other systemic involvement. References & Investigations: A pediatric reference was sought wherein no additional abnormalities were found. Complete hemogram and Peripheral smear were normal. However, a sample of his plucked hair was sent to the histopathology lab for microscopic examination which revealed large clumps of melanin unevenly dispersed along the medullary area of the hair shaft. Genetic testing to confirm the causative gene is planned for the child. Our diagnosis, based on clinical features of silvery grey hair, and the unevenly distributed large melanin clumps in the medullary area of the hair shaft on microscopic examination, is Griscelli syndrome - type 3 (pending the genetic test result). Take home points: 1. Hypopigmented hair can be associated with immunological and neurological complications which could also be fatal. Hence, a detailed history and examination are warranted. 2. A simple bedside test like a microscopic examination of the hair shaft can help to diagnose and differentiate the unevenly distributed large clumps of pigment in Griscelli syndrome from Chediak Higashi syndrome which has regularly arranged small pigmentary clumps.

12:00 - 12:10

Brucellosis-induced Leukocytoclastic Vasculitis

Zamzam Al Qutaiti MD | Dermatology resident

Brucellosis is one of the most common zoonotic infectious diseases worldwide. It is caused by intracellular Gram-negative coccoid or rod-like aerobic bacteria from the genus Brucella. The disease is transmitted to humans via direct or indirect contact with infected animals, or through the consumption of infected animal products like raw meat or dairy products2,12. It is mostly encountered in the Middle East, Central Asia, China, India, sub-Saharan Africa, and parts of Mexico and Central and South America2. So far, 4 Brucella species have been identified to cause human disease. B. melitensis (found in goats, sheep, and camels) is the most common cause of brucellosis in humans, Others include B. abortus (isolated from cattle), B. suis (isolated from swine), and B. canis (isolated

DAY TWO WEDNESDAY

6th March 2024

CONFERENCE HALL 2

THERAPEUTICS/NEW DRUGS/CASE PRESENTATIONS

from dogs)2. Brucellosis is a multisystemic infection. It can affect osteoarticular, genitourinary, central nervous, cardiovascular, respiratory, and ocular systems6. It presents a wide spectrum of clinical manifestations which are non-specific and can therefore lead to misdiagnosis and delay the proper treatment12. Patients may present with intermittent fever, weight loss, depression, hepatomegaly, splenomegaly, and joint pain3. Fever (87%), tiredness (63%), arthralgia (62%), and muscular discomfort (56%) are the primary clinical characteristics3,4. Skin involvement is less common in this disease, and it was observed in less than 10% of the cases2. Leukocytoclastic vasculitis is one of the rarest and less frequently reported manifestations of the infection in the skin. In this case, we reported this rare cutaneous manifestation in a brucella-infected patient.

Brucellosis is a zoonotic bacterial infectious disease caused by Brucella spp. It is transmitted to humans through contact with animal products and body fluids. The resulting disease is multisystemic with skin being rarely involved at presentation or during the disease course. In this case, we reported a case of 36 years old female, who presented with a history of intermittent fever, polyarthralgia, and painful non-pruritic round erythematous psoriasiform and erythema multiforme-like plaques with raised border and papulonodular skin eruptions on her extremities for 1 month. Laboratory findings showed positive serology for brucellosis and skin biopsy showed leukocytoclastic vasculitis. She was successfully treated with a combination therapy of prednisolone and antibiotics (Doxycycline and Rifampicin) with complete resolution of all symptoms.

12:10 - 12:20

Treatment of Hypotrichosis Simplex of the Scalp with Topical Gentamicin

Reem Hasan MD | Resident

Hypotrichosis Simplex of the Scalp is a rare autosomal dominant disoreder that manifests as an islolated scalp alopecia with normal hair at birth. It is mostly associated with nonsense mutations in CDSN gene that encodes corneodesmosin. Until recently there is no treatment to this condition so based on clinical studies, we decided to put our patient on toplical gentamicin and the improvement was magnificent. Our case highlights the safety and efficacy of topical gentamicin in treating such disorder.

Our case is a 2,5 year-old girl that suffered from gradual scalp hair loss since 1 year. The clinical history showed that the father had the similar condition and drug history showed application of topical minoxidil with no improvent. Examination showed pull test was positive and other hairy regions, scalp skin and other parts of body skin, nails, and teeth were all normal. Microscopic findings showed the hair shaft and bulb were normal Labaratory analysis including CBC, Zinc, Vit D were all within the normal range. Due to the abscense of genetic testing, we diagnosed our patient with HSS based on clinical findings with excluding other differentail diagnosis. Till now, there is no specific treatment so we put our patient on topical gentamicin twice daily with follow up for 6 months and the results were extremely remarkable with no side effects at all.

12:20 - 12:30

Lumps, Bumps and Joints so Stiff: Hyaline Fibromatosis Syndrome

Viola Elvia Sequeira MD | Post Graduate Resident

Hyaline Fibromatosis Syndrome (HFS) is an extremely rare autosomal recessive disease with less than a hundred cases reported worldwide. It represents a disease spectrum with infantile systemic hyalinosis (ISH) being the

DAY TWO WEDNESDAY

6th March 2024

CONFERENCE HALL 2

THERAPEUTICS/NEW DRUGS/CASE PRESENTATIONS

severe form and juvenile hyaline fibromatosis (JHF) being the mild form. Dermatologic manifestations include thickened skin, perianal nodules, and facial papules, gingival hyperplasia, large subcutaneous tumors on the scalp, hyperpigmented plaques over the metacarpophalangeal joints and malleoli, and joint contractures. ISH shows a severe visceral involvement, recurrent infections, and early death.

Case Report Two - year -old child, born of a second-degree consanguineous marriage, presented with inability to extend the knees and wrist joints from 6 months of age and asymptomatic skin lesions over the head, neck and back from one year. Cutaneous examination showed multiple, skin-colored tumors over the scalp, chest and back. Innumerable, grouped, pink to skin colored, smooth, flat to dome shaped papules over the face, scalp, ears, neck, chest and back for the past one year. Gingival tumors were also seen. Movements of the wrist and knee joints were limited, with fixed contractures over forearm and thighs. Fine motor, social and language skills were adequate for age. Laboratory examination were normal. X-rays of the long bones of the upper and lower limbs were normal except for soft tissue contractures. MRI brain and fundoscopy were normal. Skin biopsy revealed PAS-positive, homogenous, eosinophilic deposits in the dermis, with epidermal atrophy. The above features were diagnostic of Hyaline Fibromatosis Syndrome (HFS). She was referred to plastic surgery for palliative removal of the tumours and for release of soft-tissue contractures. Discussion HFS is diagnosed based on clinical features, histopathology and confirmed by genetic testing. The skin lesions have a tendency to recur after excision. Joint contractures are crippling. Case reports and studies have shown early surgical treatment provides better results. Intralesional and systemic steroids as alternative modalities with temporary outcomes.

12:30 - 13:00

Q & A

13:00 - 14:00 **Lunch Break**

Session 8: Resident Dermatologists Competition - Part 2

Jury Members:
Zbigniew Ruszczak MD | Chairman, International Clinical Case & Poster Presentation & Competition
Shaden Abdelhadi MD | Co-Chairman, International Clinical Case & Poster Presentation and Competition
Mohammed El Banhawy MD | Senior Consultant Dermatologist

14:00 - 14:10

Seven years in Distress
Meera Al Marzooqi MD | Dermatology Resident

14:10 - 14:20

Acute Genital Ulcer
Mariam Al Hammadi MD | Dermatology Resident

DAY TWO WEDNESDAY

6th March 2024

CONFERENCE HALL 2

THERAPEUTICS/NEW DRUGS/CASE PRESENTATIONS

14:20 - 14:30

Crawling Shadows: Unraveling Challenges in the Management of Delusional Infestation
Khulood Al Marzooqi MD | Dermatology Resident

Delusional infestation describes a fixed, false belief where a person believes that they are infested with living or inanimate pathogens despite the absence of medical evidence for such infestation. The descriptions of alleged pathogens have evolved over time, including the emergence of inanimate objects such as fibrous strands. With the emergence of Morgellon disease and its controversy, we report a case of an overlap with delusions of parasitosis and the challenges faced.

Abstract Summary: (Maximum of 100 words)

Delusional infestation describes a fixed, false belief where a person believes that they are infested with living or inanimate pathogens despite the absence of medical evidence for such infestation. The descriptions of alleged pathogens have evolved over time, including the emergence of inanimate objects such as fibrous strands. With the emergence of Morgellons disease and its controversy, we report a case of an overlap with delusions of parasitosis.

A 40-year-old female, presented with a strong belief that her body is infested with scabies along with fibers emerging from her skin. Comprehensive investigations including urine toxicology failed to disclose any underlying organic cause for her sensations. However, after a thorough assessment and discussion of the treatment plan, a challenging disclosure ultimately led to a failure to follow up. Many challenges were encountered in this case, including engaging the patient with the treatment. In addition, the patient's presentation is marked by the intersection of both dermatological and psychiatric manifestations, making it challenging to diagnose and manage. Further, although insects are still the most alleged source of infestation the overlap of Morgellons and delusion of infestation supports it to be a delusional infestation variant and questions the notion of its existence as a separate diagnostic entity.

14:30 - 14:40

More than Eczema?
Alya Al Ali MD | Dermatology Resident

14:40 - 14:50

Look Beyond the Scales
Sara Almarzooqi MD | Dermatology Resident

14:50 - 15:00

A Series of Unfortunate Events: Life with a Genetic Disease
Mariam Alafeefi MD | Dermatology Resident

DAY TWO WEDNESDAY

6th March 2024

CONFERENCE HALL 2

THERAPEUTICS/NEW DRUGS/CASE PRESENTATIONS

15:00 - 15:10

The Puzzling Rash? Bring out your Detective Skills

Taif Al Yammahi MD | Dermatology Resident

9: Resident Dermatologists Competition - Part 3

Jury Members:
Zbigniew Ruszczak MD | Chairman, International Clinical Case & Poster Presentation & Competition
Shaden Abdelhadi MD | Co-Chairman, International Clinical Case & Poster Presentation and Competition
Mohammed El Banhawy MD | Senior Consultant Dermatologist

15:10 - 15:20

Painful Rash

Sheikha Alketbi MD | Resident Dermatologist

Polyarteritis nodosa (PAN), a rare vasculitis, presents challenges in diagnosis and treatment. Genetic and environmental factors contribute to its unclear etiology. Neutrophil activation and immune complex formation play pivotal roles in vascular damage. Clinical manifestations vary, affecting multiple organs. Improved diagnostic techniques aid timely identification, allowing for the initiation of steroids and immunosuppressive agents. Research focuses on uncovering molecular pathways and refining treatment strategies for better patient outcomes in this complex condition.

Case report We report a previously healthy 8-year-old male, who presented to us with 1 month history of painful skin rash.It started initially as fever and painful skin rash over lower leg and upper arm associated with painful ankle and knees, admitted to other hospital and treated with IV antibiotics according to parents. Then seen in private clinic with similar symptoms, blood test showed high inflammatory markers, treated with IV medications as outpatient, no medical report. Presented to our ER as his problem worsened again, he cannot walk properly, complaining of painful heels, he developed 2 new tender lesions over the back of his leg, not associated with joint pain or swelling, No morning stiffness, Denies abdominal and urinary symptoms. Physical examination revealed non blanching rashes over both shins and left upper arm. Blood investigation showed high inflammatory markers. steroids was started since admission. We suspected Erythema nodosum, HSP, Urticaria vasculitis and familial mediterranean fever. Results Although clinical presentation was close to Erythema nodosum, we took biopsy to confirm in which it showed medium vessel vasculitis Favor Polyarteritis nodosa. Patient completed 15 days of prednisolone, in which he improved and rash resolve, furthermore he had 1 relapse episode so steroid continued for 3 weeks. For now patient off steroids , if he relapsed will consider another long term therapy.

15:20 - 15:30

When Two Histological Patterns Collide

Danya Alawadhi MD | Dermatology Resident

This is a case of a 35-year-old Asian male who presented to the emergency department with history of a progressive rash of 7 days duration. The red itchy rash started on his feet and gradually generalized. This was associated with painful oral ulcer, and generalized fatigue. He denies other systemic symptoms. The patient denied using any

DAY TWO WEDNESDAY

6th March 2024

CONFERENCE HALL 2

THERAPEUTICS/NEW DRUGS/CASE PRESENTATIONS

medication or having any recent illness. On physical examination, the patient had generalized violaceous lichenoid plaques, as well as intact and eroded bullae with excoriations and crust on an erythematous base or overlying the lichenoid plaques. The lesions were tender. The head, neck, palms and soles were spared. However, he had white macerated plaques between his toes. Upon examining his oral mucosa, an erythematous ulcer was noted in buccal mucosa. Other mucosal surfaces were spared. With a differential of vesiculobullous diseases, and drug reaction, the patient was investigated. His full blood count, liver and renal functions were normal. Inflammatory markers were insignificant. His IgE level was 1,140KU/L (<100 KU/L). His HbA1C was elevated. Two punch biopsies were taken. The biopsy showed subepidermal vesicular dermatitis with subepidermal cleft. The superficial dermis showed lichenoid infiltrate, brisk perivascular and interstitial inflammatory infiltrate composed of numerous eosinophils. Direct immunofluorescence antibody localization showed positive linear basement membrane zone immunoreactivity for IgG and C3. It was negative for IgA and IgM. We reached a diagnosis of lichen planus pemphigoides based on the clinical, histological and immunopathological findings. The patient was treated with topical and systemic therapy. Lichen planus pemphigoides is a rare variant of lichen planus and bullous pemphigoid. Its prevalence is unknown due to a low number of reported cases. Reporting such cases can increase data for establishing features and prevalence of the disease.

15:30 - 15:40

Harmony in Chaos

Ayesha Al Shawab MD | Resident

25 years old previously healthy presented with 3 months history of worsening ulcer in the inner right thigh. It initially started as a small non tender nodule then enlarged and ulcerated. New nodules appeared on upper limbs, neck, face, scalp and lower limbs. 4- 5 days back the ulcer started to become painful with bloody and puss discharge. No history of fever, shortness of breath, sore throat, no history of previous trauma. Biopsy taken from 2 sites showing dense diffuse lymphocytic infiltrate in the dermis with a grenz zone. With adittional immunostains including CD3,CD20,CD30, Bcl2,Bcl6,CD21 and CD138

15:40 - 16:00 **Q & A / Break**

Session 10: Resident Dermatologists Competition - Part 4

Jury Members:
Zbigniew Ruszczak MD | Chairman, International Clinical Case & Poster Presentation & Competition
Shaden Abdelhadi MD | Co-Chairman, International Clinical Case & Poster Presentation and Competition
Mohammed El Banhawy MD | Senior Consultant Dermatologist

16:00 - 16:10

A Not so Nosy Nodule - A Rare Case of Nodular Amyloidosis Disguising as Sarcoidosis

Sanjana Mathew MD | Resident Dermatologist

Amyloidosis is a rare disorder characterised by the deposition of insoluble amyloid proteins in various organs. Nodular cutaneous amyloidosis (NCA) is the rarest subtype of primary localized cutaneous amyloidosis, accounting for 1.5% of all cases. It presents as asymptomatic, waxy nodules or plaques with a predilection for acral sites. We report an unusual presentation of this rare tumor

DAY TWO WEDNESDAY

6th March 2024

CONFERENCE HALL 2

THERAPEUTICS/NEW DRUGS/CASE PRESENTATIONS

Case history A 53 year old male, with no known co-morbidities presented with an asymptomatic erythematous to violaceous firm nodule that had gradually progressed in size over a period of one year measuring about 2 x 3 cm over the right nasal alae at presentation. History of trauma was present prior to onset of the lesion. Differential diagnoses of sarcoidosis and lupus vulgaris were considered. Histopathology revealed nodular deposition of eosinophilic, amorphous, acellular, material spanning the entire dermis, along with interspersed plasma cells. Congo red staining was positive for amyloid. Further diagnostic workup done to rule out systemic amyloidosis including serum and urine protein electrophoresis were normal. A final diagnosis of primary nodular cutaneous amyloidosis was made. Patient was planned for excision. Conclusion Primary localized cutaneous nodular amyloidosis is rare and difficult to treat, with high rates of recurrence. There is a paucity of reported cases and treatment protocols for the same. Regular monitoring and close follow up is necessary as there is a 7 % estimated lifetime risk of progression to systemic amyloidosis in these patients. This case is being presented for its rarity.

16:10 - 16:20

Pemphigus Vegetans with Deep Scalp Ulcer: An Uncommon Presentation

Samreedhi Nath MD | Resident Dermatologist

Pemphigus vegetans is a rare clinical variant of pemphigus vulgaris accounting for less than 5% of total cases. It is an autoimmune bullous disease which manifests as verrucous hypertrophic vegetating plaques commonly in the intertriginous (the axillae, groins and inframammary folds), scalp and periorificial areas. Local moisture, heat and friction are important factors in the development of the lesions. Cerebriform tongue, where typical pattern of sulci and gyri is seen over the dorsum of tongue is well-known as "Premlatha sign" in pemphigus vegetans. There are two clinical variants of pemphigus vegetans, namely the Hallopeau and Neumann type. The Hallopeau type has a relatively benign course and is characterised by appearance of pustular lesions that after rupturing, coalesce together to gradually evolve into vegetating plaques. The oral mucosa is frequently uninvolved. The Neumann type is more severe in nature and refractory to treatment. It begins as flaccid vesicles and bullae that later develop into vegetating plaques. The oral mucosa here is usually involved. Cerebriform tongue has been reported in up to 50% cases of Neumann type. The lesions of pemphigus vegetans can also be classified into wet and dry lesions. Wet lesions are the ones found at intertriginous areas and flexural surfaces where semi-occlusion, maceration and mixed bacterial infection give rise to exudation and granulation tissue formation. Dry lesions are seen at non-intertriginous locations where the lesions dry out to form warty, fissured, painful, seborrheic keratosis like lesions. Due to these variable presentations, it gets really difficult to diagnose in its early phase and many a times may even get misdiagnosed leading up to various complications. The most common underlying pathology of pemphigus vegetans is presence of autoantibodies against Desmoglein 3 (DSG 3) and Desmoglein 1 (DSG 1). The mainstay of treatment is similar to pemphigus vulgaris, consisting of systemic corticosteroids and immunosuppressants. We are presenting an unusual case of pemphigus vegetans with a deep scalp ulcer and extensive involvement of trunk as well as extensor surface of both upper and lower extremities. Both clinical and histopathological findings were compatible with diagnosis of pemphigus vegetans. Patient showed excellent response with systemic corticosteroid, immunosuppressants, surgical debridement of scalp ulcer and good local care. We herein report this case of pemphigus vegetans due to its rare representation involving atypical sites, scaly lesions and a deep scalp ulcer.

A 50-year-old Hindu female from a remote village of Maharashtra presented to emergency room of our hospital with chief complaints of thick raised itchy lesions involving trunk, extensor surface of both upper and lower extremities for 15 days. The patient also had a swelling over centre of scalp with foul smelling discharge. The skin

DAY TWO WEDNESDAY

6th March 2024

CONFERENCE HALL 2

THERAPEUTICS/NEW DRUGS/CASE PRESENTATIONS

lesions initially begin 2 years back with itching over both upper extremities followed by eruptions of multiple clear fluid filled vesicles which used to ruptured on their own. The ruptured lesions coalesced together to form raw areas of erosions that gradually evolved into thick, elevated, moist verrucous hypertrophic vegetating plaques. The lesions later spread to involve trunk and both lower extremities. She was treated for the same at a nearby peripheral healthcare facility with various antibiotics and topical agents without much relief. Later she got referred to higher centre due to worsening of condition 15 days back. No history of joint pain, photosensitivity, drug intake, topical irritant application prior to appearance of lesion. Past history is not suggestive of any sexually transmitted disease, drug reaction, any other chronic skin condition. No history of similar complaints in any family member. Patient is not a known case of type 2 diabetes mellitus, hypertension, asthma, COPD, thyroid disorder. General physical and systemic examination revealed nothing abnormal. Cutaneous examination reveals generalised, mostly symmetrical, multiple well defined, skin coloured to dark brown, elevated, verrucous vegetating scaly plaques of variated sizes approximately 1cm x 1cm to 12cm x 8cm over abdomen, back, extensor surface of both upper and lower extremities associated with itching. Largest plaque of size 12cm x 8cm was seen over extensor aspect of right lower extremity which was covered with granulation tissue and thick crust with scaling. Few plaques showed induration and were covered with thick adherent scaly crusts. Some appeared red in colour due to application of vermillion over it. Oral and genital mucosa were spared. Tongue was not involved. A boggy swelling was present over parietal region of scalp of size 5cm x 5cm with ill-defined border, ellipsoidal in shape, tender on palpation, soft to firm in consistency with no local rise of temperature with irregular texture of the overlying skin. Complete blood count reveals raised WBC. ESR and C-reactive protein levels were normal. Biochemical test showed raised serum creatinine and blood urea. Rest all blood parameters were within normal limits. Chest X-Ray and USG findings showed no significant abnormality. HIV serology, Hepatitis B antigen and VDRL tests were non-reactive. Skin biopsy was taken and desmoglein antigen was sent. Histopathological examination showed stratified squamous keratinised epithelium with marked hyperplasia, mild acanthosis, papillomatosis, suprabasal intraepidermal microabscess comprising of plenty of polymorphs, eosinophils. Dermis revealed mild focal perivascular lymphocytic infiltrate mixed with eosinophils. All the investigations and histopathological findings were compliant with the diagnosis of Pemphigus vegetans of Hallopaeu type. Patient was started on injection hydrocortisone 100 mg thrice a day along with antibiotics and oral Azathioprine 50 mg daily. Potassium permanganate compressions were given followed by topical antibiotic cream application twice a day over the lesions. The lesions showed remarkable clinical improvement after which corticosteroid was tapered gradually. Surgical debridement of the scalp swelling was done till the base of the lesion of exposed. Initially it was filled with pus and few maggots which later got replaced by healthy granulation tissue. On subsequent follow ups, the lesions cleared drastically leaving behind areas of residual hyperpigmentation. Pemphigus vegetans is a very rare variant of pemphigus vulgaris. Its varied presentations come as a challenge in getting the disease properly diagnosed. The patient here had most of the lesions on extensor surface rather than flexural surface which is an unusual presentation. Scaling was also seen on most of the lesions due to which it could have been easily confused with pemphigus erythematosus where scaly plaques are a characteristic feature. Although scalp is not so uncommon site but the presence of a deep scalp ulcer in this particular case has not been documented before in our knowledge. All these rare findings make this case quite unique on its own and thus the need to present the case.

DAY TWO WEDNESDAY

6th March 2024

CONFERENCE HALL 2

THERAPEUTICS/NEW DRUGS/CASE PRESENTATIONS

16:20 - 16:30

Cases Series on Lichen Planus Pemphigoides

Nidhin Niclavos MD | Resident Dermatologist

Lichen planus pemphigoides (LPP) is a rare autoimmune blistering disorder characterized by the coexistence of lichen planus (LP) and bullous pemphigoid (BP) lesions. This case series aims to present a comprehensive analysis of the clinical features, diagnostic approaches and therapeutic modalities employed in the management of LPP.

Materials and methods: A retrospective chart review of seven patients diagnosed with LPP at a tertiary care hospital was done over a period of 6 years. Mean age of the population was 44 +/- 21 years; with the youngest patient being 5 years old. The male: female ratio was 1: 2.5. The study population exhibited a wide range of cutaneous manifestations including pruritic and lichenoid papules, plaques, erosions and tense bullae over both lichenoid and normal skin, predominantly involving the extremities, with the exception of one patient where LPP was limited to the genital mucosa. All the patients underwent skin biopsy, which showed lichenoid interface dermatitis and subepidermal blister formation with eosinophilic infiltrates. Direct immunofluorescence studies were done in six patients and showed linear deposition of IgG and C3 along the basement membrane zone in five patients, further confirming the diagnosis. Indirect immunofluorescence done in three patients showed positivity to BP 180 and 230. Systemic corticosteroids were the mainstay therapy. Additional immunosuppressive agents such as dapsone or rituximab were also employed. Conclusion: The challenges in diagnosing LPP lie in its rare occurrence and the overlapping clinical and histopathological features with LP and BP. Furthermore, the lack of standardized treatment guidelines adds complexity to its management. This case series provides valuable insights into the clinical presentation, diagnostic workup and therapeutic strategies utilized in LPP, emphasising the need for a multidisciplinary approach involving dermatologists and pathologists.

16:30 - 16:40

Encephalocraniocutaneous Lipomatosis

Saeid Davoodi MD | Resident Dermatologist

Encephalocraniocutaneous lipomatosis (ECCL) or Haberland syndrome is an extremely rare mosaic condition caused by postzygotic activating mutations in the fibroblast growth factor receptor 1 gene (FGFR1). Patients usually present with clinical presentations in three organs included: skin, eye and central nervous system. Major p resentations are cerebral malformations, ipsilateral eye abnormalities (usually choristomas), and papulonodular skin lesions including lipomas, fibromas, fibrolipomas, and angiolipomas. Here we report a case of a Child with compatible with Haberland Syndrome. cerebral lesions, eye problems and skin findings All the patient sociodemographic, clinical, and neuroradiological data was collected. Case Report A 7yearold boy presented to our dermatology clinic in April 2023 with a history of a large yellowish verrucose plaque on the left temporoparietal area since His Birth (Fig 1). He also had a previous history of a left eye tumor, the tumor was described as a firm exophytic pedunculated lesion in the left eye which underwent surgical resection (Fig The histological examination of the tumor revealed bundles of elongated spindle2). shaped (Fig 4) . cells that were positive for S100, indicating a diagnosis of lipomatous plexiform neurofibroma His parents declared no complication at birth and a normal bodyweight. His past history was unremarkable and his family had no consanguinity or history of neurocutaneous disease. Examination: Upon examination, the patient exhibited large yellowish verrucose plaque measuring 8*12cm on the left temporoparietal area similar to lipoma with alopecia overlying it, known as nevus psiloliparus.

DAY TWO WEDNESDAY

6th March 2024

CONFERENCE HALL 2

THERAPEUTICS/NEW DRUGS/CASE PRESENTATIONS

There were no other specific cutaneous lesion or significant findings suggestive of lymphadenopathy or systemic involvement. Investigation: Magnetic Resonance Imaging (MRI) of the brain was performed to evaluate the extent of the disease. The imaging revealed well-demarcated enhancing mass lesions following the course of the trigeminal nerves along the cavernous sinus. Additionally, a crescent-shaped epibulbar mass with fatty intensity was observed at the left lateral can thus, supero-lateral to the eyeball and inferolateral to the lacrimal gland. The MRI findings showed a bright signal on both T1 and T2 weighted images, with signal loss after saturation of the fat signal. Based on these findings, the brain MRI report concluded that the patient had bilateral trigeminal nerve neurofibroma/schwannoma and a left orbital dermolipoma (Fig 5 & 6). All metabolic, serologic and screening laboratory tests were in normal ranges. Discussion: Encephalocraniocutaneous lipomatosis (ECCL), also known as Haberland syndrome, is a rare mosaic condition caused by postzygotic activating mutations in the fibroblast growth factor receptor 1 gene (FGFR1). This case report highlights the clinical manifestations of ECCL, including cerebral malformations, eye abnormalities, and various skin lesions. Our patient presented with typical triad of clinical presentation in ECCL including specific scalp lipoma known as nevus psiloliparus in skin, left orbital dermolipoma as central nervous system lipoma and history of left eye tumor which as mentioned histologically reported as lipomatous plexiform neurofibroma. The imaging modalities including brain MRI supported the diagnosis of ECCL and demonstrated the involvement of the trigeminal nerves. Timely referral to a pediatric neurologist was deemed necessary for appropriate management and further evaluation of the patient. Further research is needed to better understand the underlying genetic mechanisms and optimize treatment strategies for ECCL. Conclusions With respect to all data about ECCL, clinical suspicion should be done with similar cases presenting with lesions which can be found in ECCL. And fur lowe ther analyses and possible genetic tests of a greater number of similar patients with lesions limited to the CNS are necessary for higher detectability. This would make a great impact, because misdiagnosed patients can be mistreated, which in turn can r the quality of their life as well as of their caregivers. Fig 1. plaq ue area large yellowish verrucose on the left temporoparietal similar to lipom a, alopecia overlying it, with known as nevus psiloliparus.

16:40 - 16:50

An Unusual Presentation of the Merkel Cell Carcinoma of the Right Cheek: A Case Report

Shaikha Alhaj MD | Resident Dermatologist

Background: Merkel cell carcinoma (MCC) is a rare primary neuroendocrine skin tumor usually represented as a flesh- colored or bluish-red nodule on the face, neck, or head. Long-term Ultraviolet (UV) radiation exposure and Merkel cell polyomavirus (MCV) are associated with Merkel cell carcinoma pathogenesis. The incidence of MCC has been increasing over the past few decades; however, the incidence of Merkel cell carcinoma in the cheeks is not well-documented in the literature. Therefore, we present a case of Merkel cell carcinoma in an 87-year-old male in right cheek.

Aim: The primary goal of presenting the case was to bring Merkel cell carcinoma, a diagnostic challenge, to the notice of dermatologists and oncologists, as early detection and prompt treatment are important.

Case Report: The patient is 87 years old and has a significant past medical history of diabetes mellitus, hypertension, dyslipidemia, chronic kidney disease stage 3, benign prostatic hyperplasia, chronic hyponatremia, acute pancreatitis, essential thrombocytosis on hydroxyurea, and ischemic heart disease. The patient presented

DAY TWO WEDNESDAY

6th March 2024

CONFERENCE HALL 2

THERAPEUTICS/NEW DRUGS/CASE PRESENTATIONS

with a mildly swollen right upper lip showing a poorly defined, relatively homogenous subcutaneous area with a history of persistence for 1.5 months.

The clinical examination revealed a 5x3 cm nodular lesion on the right side of the cheek with swelling of the right upper lip. Induration and nodules were felt under the plaque. All other systems were reviewed and were negative. Lab results revealed that WBC count, platelets count, and creatinine were high; hemoglobin and hematocrit were low. A skin punch biopsy revealed skin with diffusely infiltrative tumor within the dermis. Additionally, TTF-1 was negative, and CK20 was positive in the tumor cell. Ki67 showed a high proliferative index. Immunohistochemistry markers results and histopathological features confirmed the diagnosis of Merkel cell carcinoma. The patient was advised for a follow-up after a PET scan to discuss further management. The plan was to maintain a healthy lifestyle and monitor the lesion.

Conclusion: Merkel cell carcinoma of the skin is an aggressive lesion with a high risk of metastasis and recurrence, which is more common in immunocompromised people. Prompt management and treatment of Merkel cell carcinoma is essential because if left untreated, it can spread to other parts of the body and can also metastasize to lymph nodes and other organs.

16:50 - 17:00

Disseminated Tuberculosis With Cutaneous Involvement In An Immunocompetent Patient

Reham Alshehri MD | Medical Intern

Disseminated tuberculosis in immunocompetent individuals challenges our understanding of the disease, involving the spread of Mycobacterium tuberculosis to various organs, including the skin. This study explores the unique clinical patterns of cutaneous tuberculosis in this context.

A 22-year-old male from Saudi Arabia presented with a two-year history of persistent, non-healing ulcers on the chest wall, unintentional weight loss, chronic diarrhea, and painful swelling in the right knee. Despite no prior skin issues, he exhibited cachexia and a sick appearance. Deep-seated ulcers with purulent discharge were found on the chest wall. Admission for investigation raised suspicion of disseminated tuberculosis. Lab results indicated microcytic hypochromic anemia, and AFB smear confirmed TB. . Punch skin biopsy revealed granulomatous dermatitis with lymphoplasmacytic infiltrate. Ziehl-Neelsen (ZN) special stain revealed an acid-fast bacillus (AFB). A CT scan confirmed disseminated TB involving the skin, lungs and MSK. Treatment with RIPE therapy was initiated.

This case illustrates the diverse manifestations and characteristics of tuberculosis (TB) is crucial for timely diagnosis and effective management. The presented case underscores the significance of recognizing atypical TB presentations, such as disseminated TB involving the skin, which can mimic other conditions. Awareness of the varied clinical patterns of TB is essential for healthcare professionals to initiate appropriate investigations promptly. This knowledge not only aids in preventing diagnostic delays but also ensures the timely implementation of targeted treatments, thereby improving patient outcomes. As TB continues to present itself in various forms, a comprehensive understanding of its diverse characteristics remains paramount in the global effort to combat this infectious disease.

DAY TWO WEDNESDAY

6th March 2024

CONFERENCE HALL 2

THERAPEUTICS/NEW DRUGS/CASE PRESENTATIONS

17:00 - 17:45

Expert Education Lecture

Zbigniew Ruszczak MD | Chairman, International Clinical Case & Poster Presentation & Competition

17:45 - 18:00

Q/A

DAY TWO WEDNESDAY

6th March 2024

CONFERENCE HALL 3

COSMETIC & SURGICAL DERMATOLOGY

Session 4

Chairperson: Andre Mattos MD, Mohamed Adib Batal MD

08:30 - 09:00

Update on the Changing World of Non-Invasive Body Contouring

David J. Goldberg MD | Director of Cosmetic Dermatology

Non-invasive Skin Tightening is among the most rapidly growing areas of aesthetic dermatology throughout the world. Both facial and non-facial areas can be treated.

A variety of energy-based sources can be used for non-invasive skin tightening including ultrasound, radiofrequency and HIFEM to treat skin, fat, and muscle.

This talk will focus on the evolution of these technologies with a focus on better newer approaches. Both science

09:00 - 09:30

New Toxins in the US – What is Making its Way Through the Clinical Trial Domain in 2024

Michael H. Gold MD | Owner, Medical Director

Botulinum toxin A transformed the aesthetic and cosmetic arena into heights that no one saw coming when the first toxin was approved many years ago.

Newer toxins have emerged into the clinical scene and this presentation will differentiate these newer toxins and show the clinical evidence that has entered into the public domain with respect to these toxins. In addition, several newer toxins are in clinical trials at this time, and preliminary, public domain data will also be presented. It is an exciting time still for toxins for cosmetic use and we will focus on how some of these newer toxins may make a difference for our patients.

09:30 - 10:00

Comparative Study Between Plate Cryolipolysis and Vacuum in Dermal and Hypodermal Tissue

Patricia Froes Meyer MD | Physiotherapist

The plate cryolipolysis system offers the possibility of no complications arising from the use of suction, such as the presence of bruises , in addition to the treatment of areas that could not be clamped in the vacuum system, but this system it isn't the more effective according to the literature.

Objective: The objective is to compare the two cryolipolysis systems in relation to their effectiveness in dermal and hypodermal tissue.

Materials and Method: The sample were 12 female participants who underwent abdominoplasty surgery. The participants were divided in two groups (plate and vacuum cryolipolysis) randomly, and were evaluated using assessment protocols, perimetry, plycometry, photography, ultrasound and bioimpedance before the surgery. In the skin sample collected, immunohistochemical markers such as the inflammatory process (COX-2), Caspase,

DAY TWO WEDNESDAY
6th March 2024

CONFERENCE HALL 3
COSMETIC & SURGICAL DERMATOLOGY

fibroblasts (FGF2 e FGFR1), mitochondrial fission factor and PPARGama were analyzed. The application time will be approximately 62 minutes and only one session was carried out, at a temperature of -10ºC (vacuum cryolipolysis) and -5 ºC (plate cryolipolysis). The application methodology was 30 minutes of cryolipolysis, followed by 2 minutes of reperfusion, ending with another 30 minutes of cryolipolysis, with the right infraumbilical side treated and the left side maintained as control. After 60 days, the participants were reevaluated following the previous methodology and abdominoplasty surgery was performed. Results: The markers caspase, cyclooxygenase (COX-2), FGF2, FGFR1, DRP1 showed results of 50 to 100% greater in the application of vacuum than in the application of plate cryolipolysis in a statistically significant way, except in relation to FGFR1, where there was no superiority between the techniques. Type I collagen was present in both types of cryolipolysis, also without significant differences.

Conclusion: Vacuum cryolipolysis proved to be more effective in relation to dermal and hypodermic tissue. Further studies focused on analyzing the safety of these techniques are suggested.

10:00 - 10:30

Hemostatic Net - A Safer Facelift
Andre Mattos MD | Plastic Surgeon

Hematoma is the most common postoperative complication of rhytidoplasty. Its occurrence increases morbidity and impairs recovery. Internal sutures to close detached areas are used in abdominoplasty to prevent seromas. Taking this into account and in order to reduce the number of patients with hematomas post rhytidoplasty, we have developed a similar surgical procedure in which a hemostatic net is made of continuous nylon 4-0 transfixing stitches to include the skin and the superficial musculoaponeurotic system-platysma

Abstract Summary

Hematoma is the most frequent postoperative complication of rhytidoplasty, occurring in up to 8% of patients. Its occurrence affects postoperative recovery, as it is associated with an increased incidence of edema, ecchimosis, and, in some cases, ischemia, infection, and necrosis of the operated area. Over the past 4 decades, plastic surgeons have been looking for a solution to this problem without, however, finding a definitive answer to it. Neither drains, tissue glues, tumescent infiltration;nor dissection with ultrasonic instruments has been completely effective in preventing hematoma. On the other hand, studies that have observed no incidence of this complication have been based on the control of clinical variables that are sometimes difficult to reproduce. Seroma is a common complication after other plastic surgery procedures, especially abdominoplasty; however, there is an efficient and technically feasible solution to the problem. As conceived by Baroudi and Ferreira, it consists of an internal suture that leads to almost total closure of the detached area, thus avoiding eventual fluid deposits. In rhytidoplasty, the use of internal sutures is complicated due to the dynamic traction of the flaps and its inadequate accommodation under the skin. In these operations, the use of external sutures to stabilize the flap has already been described by Pontes. Based on the principle of mechanical and compulsory closure of the operated areas, as occurs in abdominoplasty, we describe here a surgical procedure in which a homeostatic net of continuous and transfixing sutures in the skin is created. This leads to almost total occlusion of the operated area. The hemostatic net is an efficient method for the prevention of early hematomas following rhytidoplasty. This surgical procedure did not result in a significant increase in the incidence of ischemia and necrosis. Keywords: Hematoma. Rhytidoplasty. Face. Necrosis. Ischemia

DAY TWO WEDNESDAY

6th March 2024

CONFERENCE HALL 3

COSMETIC & SURGICAL DERMATOLOGY

10:30 - 10:45

Botox Treatment for Hair Loss and Baldness

Khaled Othman MD | Consultant Dermatology, Andrology, Aesthetic Medicine & Laser

Androgenic alopecia is still a challenging disease that affects both genders and is characterized by hair loss in a specific pattern of the scalp. It is lifelong condition with plenty of treatment methodology options and updates. Botox consider effective and safe treatment option for Androgenic Alopecia. Systemic review for use of Botlinum Toxin for Androgenic Alopecia updates literatures will be discussed. The present theoretical role of Botox in Androgenic Alopecia, Hair Growth, Alopecia and Cosmoderma. The mechanism of Botox in Androgenic Alopecia and microvascular follicular blood flow effect and decrease level Transforming Growth Factor Beta. The compound treatment for Androgenic Alopecia including Botox is more effective in treatment supported by clinical experience, researches and scientific data. Understand the mechanism of Botox in hair treatment for androgenic Alopecia, Alopecia, and Cosmoderma. Discussing the effectiveness of Botlinum Toxin in hair treatment with clinical experience for treatment of Androgenic Alopecia, Hair Growth, Alopecia and Cosmoderma will be clarified during this presentation to use as guide for practical apply.

10:45 - 11:00 **Q & A / Break**

Session 5

Chairperson: Minal Patwardhan MD, Hadaf Aljunaiyeh MD

11:00 - 11:20

Management of photoaging through the infiltration of hybrid fillers based on hyaluronic acid and calcium Hydroxvapatite at different concentrations

Ilaria Proietti MD | Dermatologist

Photoaging is a particular condition of the skin where premature aging occurs caused by ultraviolet radiation from the sun. In fact, sun exposure causes dangerous damage to the skin which, extending over time, speeds up the natural biological skin aging. The main manifestations consist in alterations of the skin texture with an accentuation of expression wrinkles and the formation of large furrows, in alterations of the consistency with skin thickening, roughness, color alterations, xerosis and elastosis. This condition can be treated with laser therapy, biostimulation and chemical peels.

Abstract Summary: The use of hybrid fillers based on hyaluronic acid and calcium hydroxyapatite has an important role in the biorestructuring of the deep dermis and subcutaneous tissue. These devices are able to induce neocollagenesis and improve skin quality. We present the case of a 72-year-old Caucasian female with phototype II according to Fitzpatrick and Glogau 3 treated with fillers based on crosslinked hyaluronic acid (HA) (20 mg/ml) combined with calcium hydroxyapatite (55.7% CaHA).), with lidocaine (anesthetic) and hyaluronic acid 26 mg/ml, low cross- linked PEG polymer, glycine, L-Proline and 1% CaHA. The patient presented clinical improvement as assessed by digital morphometry and did not present with any adverse events.

DAY TWO WEDNESDAY

6th March 2024

CONFERENCE HALL 3

COSMETIC & SURGICAL DERMATOLOGY

11:20 - 11:40

Role of Nutraceuticals in Regenerative Dermatology

Seema Satyapal Singh MD | Specialist Dermatologist

Regenerative medicine encompasses innovative therapies that allow the body to repair or regenerate aging cells, tissues, and organs. The skin is a particularly attractive organ for the application of novel regenerative therapies due to its easy accessibility and nutraceuticals plays a significant part in this field.

The accumulated damage from intrinsic and extrinsic factors yields keratinocytes and fibroblasts that fail to produce important cellular components as well as they did when they were younger. Cellular factors that age cells include nuclear DNA damage, mitochondrial DNA damage, diminished lysosomal function, structural impairment of proteins, and damage to cell membranes.

Nutraceuticals have been gaining popularity steadily due to holistic trend preferring inside out approach.

Data gathered over the last few decades shows the protective effects of antioxidants such as polypodium leucotomos, ascorbic acid, green tea etc . Other antioxidants are associated with less data, but hypothetically should deliver similar benefits.

Addition of nutraceuticals to various in clinic professional dermatology treatments and at home therapies can promote better and enhanced antiaging.

Hair loss affects millions of people each year and has detrimental effects on self-esteem and psychosocial functioning. Person undergoing nonsurgical or surgical hair restoration with various treatment modalities need to nourish and replenish the hair roots.

Although nutraceutical products are not first-line therapy for hair loss, dermatologists may recommend these treatments in patients refusing prescription medications, specifically requesting a natural treatment, or in addition to a first-line agent such as minoxidil. Various supplements promote anti-inflammatory, adaptogenic, antioxidant, and DHT-inhibiting properties. Marine-derived nutraceutical substances also have been investigated for their role in treating hair loss.

Physicians must discuss patient preference and anticipated length of treatment when discussing treatment to maximize patient satisfaction.

11:40 - 12:00

Use of Progenitor Cells in Hair Restoration

Shweta Singh MD | Specialist Dermatologist

Autologous Micrografting is based on the concept that by increasing the superficial area of a tissue graft by cutting the graft into smaller “micrografts,” it is possible to cover a treatment area much larger than the donor site. Androgenetic alopecia is a disorder of multifactorial origin and several treatment modalities have been developed and used while many continue to be still under research and development. Tissue engineering in hair regeneration strives to provide novel, non-invasive hair regrowth therapies and involves the use of biological mediators providing a new tool for regenerative medicine. The choice of the biological sources used, such as stem cells and grafts, is crucial. Striae distensae or stretch marks are flat red, violaceous or white dermal lesions due to stretching of skin followed by damage to collagen and elastin during adolescenece, pregnancy, obesity and diseases like Cushings syndrome. It is a common cosmetic concern and causes psychological distress more than anticipated. In this instance, we use skin collagen, elastin and pigment forming progenitor cells to repair and remodel the damaged skin.

DAY TWO WEDNESDAY

6th March 2024

CONFERENCE HALL 3

COSMETIC & SURGICAL DERMATOLOGY

Conclusion: Autologous micrografting technique using the Rigenera system and protocol is an effective tool for managing patients with early to moderate stages of Androgenetic Alopecia. The treatment was effective and well tolerated. In regards to its use in striae distenae, it projects to be an effective tool but more cases need to be done and results analysed in the near future.

12:00 - 12:20

Adverse Effects of Botulinum Toxin in Cosmetic Uses

Fouz Hassan MD | Head of the Department of Dermatology and Venereology

Patients, more and more, are demanding cosmetic procedures that leave no scars and allow them to return to normal activity quicker.

Botulinum toxin (BT) is now known for its role in improving patient quality of life in many aspects of health care .

Treatment with botulinum toxin is widely viewed as safe, effective and largely devoid of serious side effects

There are no long-term or life-threatening adverse effects related to botulinum toxin treatment for any cosmetic indications .

The risk of possible complications can be reduced by means of a thorough analysis of the patient's medical history and the use of the appropriate dose and technique for the injection.

We will discuss all the adverse events that may be resulted after botox injection for cosmetic purposes>

12:20 - 12:40

Solid State Laser for Macular and Linear Vascular Lesions

Nicola Zerbinati MD | Associate Professor of Dermatology and Venereology

Until today the colorant lasers (dye lasers) thank to to a well absorbed by blood wavelength and the short pulse emission mode could be considered a gold standard for flat vascular lesions. The latest solid state laser technologies are now able to deliver short pulses at higher energy and with a solid and intelligent control of the pulse modulation flat or thicker lesions can be treated with no undesired post treatment effects such as purpura.

12:40 - 13:00

Simultaneous Ablative and Non-ablative Fractional Skin Resurfacing with Differential Densities: How to Maximize Results with Minimal Downtime

Nicola Zerbinati MD | Associate Professor of Dermatology and Venereology

Fractional laser treatments for skin rejuvenation are still evolving and recently, new mixed laser technologies have been presented to the aesthetic medicine field. The demand for a modality that combines the efficacy of ablative lasers with the minimal downtime of the non-ablative pushed the development mixed laser technologies, which delivers a fractional treatment of ablative CO2 and non-ablative 1550 nm lasers, simultaneously or sequentially in the same microdot or with different densities. In this talk we present how to operate and optimize results and downtime also with the support of preliminary in-vitro evidence of effects at different emission modes.

DAY TWO WEDNESDAY

6th March 2024

CONFERENCE HALL 3

COSMETIC & SURGICAL DERMATOLOGY

13:00 - 14:00 **Q & A / Lunch Break**

Session 6: IMCAS Session: Prejuvenation, Just an Illusion?

Chairperson: Hugues Cartier MD, Hassan Galadari MD

14:00 - 14:15

Mini Battle: Prejuvenation, The Ageless Paradox

Hugues Cartier MD | Dermatologist

Hassan Galadari MD | Associated Professor of Dermatology

14:15 - 14:30

Aging Backwards: The Prejuvenation Prescription

Diala Haykal MD | Cosmetic and Laser Doctor

Prejuvenation, a preventive treatment for aging, emerged in the early 2000s as Generation Z (Gen Z) started seeking a new approach to aging. Fueled by accelerated advancements in skincare and aesthetics coupled with the rise of social media as a prominent source of information, prejuvenation has gained immense popularity. Gen Z, being the first digital generation, relies heavily on social media and the internet for skincare and aging advice, leading to a dynamic sharing and dissemination of information on aesthetic dermatology within this generation. Consequently, prejuvenation has become a trending topic across all media platforms.

The presentation explores "Prejuvenation," a proactive anti-aging approach popularized by Generation Z. It offers non-invasive procedures such as fillers, laser treatments, and skincare routines to slow the process of aging, although not halting it completely. Generation Z's inclination towards Prejuvenation signals a cultural shift, valuing youthfulness and challenging the conventional aging norms. I will also explore how this trend has been enhanced by advancements in skincare, social media influence, and technological developments in aesthetic dermatology. Additionally, I will be highlighting the importance of managing patient expectations, and managing the shift from corrective practices to preventative measures in cosmetic dermatology.

14:30 - 14:45

Skin Prejuvenation Strategies: Stimulation rather than Inflammation

Arnaud Lambert MD | Physician and Medical Director

Prejuvenation is a new trend with a new generation of patients, younger than ever.

We seek strategies to answer their demands, without compromising the future of their skin. Some treatments, injectable or EBD's damage the skin to build collagen.

Some of them leave permanent fibroses or damages into the skin.

For younger patient we can wonder if it is wise to do such procedures. « Primum non nocere ». We should rather choose procedures we know won't affect the future of their skin.

DAY TWO WEDNESDAY

6th March 2024

CONFERENCE HALL 3

COSMETIC & SURGICAL DERMATOLOGY

14:45 - 15:00

The Aesthetic Generation - The Fake Generation

Dominique du Crest | Co-founder Skin & Digital Summit

This presentation explores the growing trend among individuals under 30 towards visibly enhanced looks, increasingly seen as a fashion statement and status symbol. This shift has led to a dramatic rise in cosmetic procedures, including botulinum toxins and fillers. Key medical professionals' express concerns over the excessive use of these procedures, especially among the youth. It also discusses the investigative work of French journalists who highlight the impact of both invasive and non-invasive cosmetic procedures on young people.

A significant aspect of this trend is the influence of social media and "Beauty influencers," who often promote these procedures without adequately addressing the potential risks or spreading misinformation. This situation has prompted responses from various sectors (Academic Institutions, Medical Professionals, Regulatory Bodies and the Industry)

The presentation concludes that it is crucial for all involved parties to understand the stakes and act decisively to protect this vulnerable young generation from the potentially harmful effects of an aesthetics-obsessed culture.

Session 7

Chairperson: Reza Robati MD, Mohamed Bazza MD

15:00 - 15:15

Botulinum Toxin Applications in the Lower Face and Neck

Reza Robati MD | Professor of Dermatology & Director

Botulinum toxin has been widely and mainly used for the treatment of conditions affecting the upper and middle face; however, recent efforts have expanded the indications of botulinum toxin injection to the lower face and neck areas for cosmetic and medical purposes.

A comprehensive literature search was performed using the following keywords [[botulinum] AND [[Toxin] OR [Neurotoxin]]] AND [[Lower AND Face] AND/OR [Neck]] within the main databases including Web of Science, PubMed, Embase, and grey literature on and before February 2023. The data were screened using titles and abstracts and those relevant to the topic were included in the paper.

15:15 – 15:30

Correction Of Nasolabial Folds Wrinkle Using Intraoral Non-ablative Er:Yag Laser

Khaled Gharib MD | Professor of Dermatology and LASER

The accentuated nasolabial folds (NLFs) is the most pronounced sign of aging. Non-ablative erbium:yttrium aluminum garnet laser (ER:YAG), Smooth mode was used for the treatment of mucosal tissue. It was reported that it is effective in facial rejuvenation.

Materials and methods: A total of 60 patients with different grades of NLFs wrinkle treated with 2940 nm Er: YAG

DAY TWO WEDNESDAY

6th March 2024

CONFERENCE HALL 3

COSMETIC & SURGICAL DERMATOLOGY

laser (20 patients intraorally, 20 patients extraoral, 20 patients inta and extraoral). Six sessions were done every 2 weeks. The efficacy was assessed by two blinded dermatologists. Photographs were taken at the baseline, end of treatment and 6 months after the final session to document visible changes in NLFs wrinkle. The assessment was based on Modified Fitzpatrick Wrinkle Scale (MFWS) and by comparing the photographs. Patient's self-assessment and patient's satisfaction were used for assessment of final results and any side effects associated to treatment were observed. Results: There was significant reduction of the NLFs wrinkle. The MFWS was significantly improved 6 months after treatment compared to before treatment ($p < 0.001$). At the end of the follow-up period, there was improvement in overall appearance of the wrinkles. Patient's self-assessment and satisfaction demonstrated better cosmetic outcomes. Conclusion: Combined intra and extraoral Er: YAG laser is safer, more painless, and more effective than intraoral treatment option for NLFs wrinkle.

15:30 - 15:45

Revolutionizing Auricular Keloid Treatment: The Power of Combined CO2 and Dye Laser Therapy

Simone Amato MD | Dermatology Resident

Auricular keloids pose significant aesthetic and functional challenges, and traditional treatments often fall short in addressing these. Our study presents an innovative combined approach of ablative CO2 and dye laser therapy for improved keloid management. This treatment protocol was applied to 15 patients with auricular keloids after an initial multispectral analysis to assess keloid composition. The laser sequence was tailored per patient based on this analysis. Evaluations using the Vancouver Scar Scale and Patient and Observer Scar Assessment Scale were carried out at baseline and at 3-week intervals post-treatment. The results showed a significant reduction in these scores at the final follow-up ($p<0.05$), suggesting improvements in keloid color, texture, and pliability, with minimal adverse events. Additionally, no recurrence of keloids was observed. Our findings indicate that this novel methodology of multispectral analysis followed by tailored laser therapy may offer a safe and effective solution for auricular keloids, promising enhanced keloid treatment and prevention of recurrence. However, further investigations, including randomized controlled trials, are needed to confirm and optimize this treatment protocol.

15:45 – 16:00 Q & A / Break

Session 8

Chairperson: Ahmed Alqahtani MD, Azer Rashid MD

16:00 - 16:15

The Exosomes Story: Who is Questioning?

Ahmed Alqahtani MD | Assistant Professor

In the last five years we started hearing more and more about exosomes and the magic they hold. Many have never heard of them; others confuse them with stem cells or growth factors. I have attended personally over 17 lectures about exosomes in the last 3 years, 13 of them were in renowned international conferences and the rest were organized by sponsored seminars. I read over 105 published papers and articles from 2019-2023. Nothing was found to support the claims made in these lectures. As result, I wanted to investigate the matter and publish my findings.

DAY TWO WEDNESDAY

6th March 2024

CONFERENCE HALL 3

COSMETIC & SURGICAL DERMATOLOGY

I ran an analysis on the products found in the market today to see if indeed there are exosomes in them or not. Moreover, I interviewed some of the doctors who presented lectures about Exosomes and asked them about their background and how much they know about exosomes. The products were tested in independent lab in Florida, USA. They used two methods to confirm the presence of exosomes, flow cytometry and western blot. Anti-bodies against CD9, CD63 and CD81 were used to detect the exosome markers. The results showed none of the products were positive for exosomes. To further confirm the results, we ran a test to detect if there are any RNA presence in the products using SYTO™ RNA select kit from Invitrogen. All samples came negative, indicating no RNA were present in the samples. I examined in detail the literature used by the manufacturer to prove their efficacy and potency. All the literature originated from one group in South Korea and were published in open access journals (online) and not peer reviewed. The data presented in the papers lack clarity and statistic relevancy. In addition, none of the authors signed or declared no conflict of interest. The doctors who presented in conferences mostly were sponsored by the manufacturer or been supported by the manufacturer. When I asked them of their experience in exosomes or regenerative medicine, they all admit they have limited knowledge and never published any scientific materials on exosomes. In fact, some admitted the data they used on their presentation were giving to them by either the manufacturer or colleagues who are sponsored by the manufacturer. In conclusion, the manufacturer exploited the lack of knowledge of exosomes by physicians and compensated the KOLs very well to gain acceptance and influence in the market. Dr. Leigh Turner, a bioethicist at the University of Minnesota who studies the anti-ageing filed said "You often have these lucrative markets emerge on a slender foundation of credible work".

16:15 - 16:30

Tissue Fibroplasia as A Modern Mechanism Used in Mesotherapy

Izabela Zaleska MD | Specialist in Aesthetic, Medical and Therapeutic Cosmetology

Tissue fibroplasia, i.e. the action of biorevitalization with a biostimulator in one preparation for mesotherapy, i.e. a new group of injection products. In order to verify, the effect of hyaluronic acid and sodium succinate on the parameters of aging skin was tested with the examination of its signs.

The study included 12 patients with dry skin with clear signs of aging. Before the study, skin parameters were measured: ultrasonography in a specific point on the face and control on the neck not subjected to the procedure; multispectral analysis; scalar and palpation assessment. Then, each of the 12 subjects underwent 6 treatments using a preparation based on molecular hyaluronic acid with sodium succinate (1%) (6 doses of 3ml/session) using the point-by-point technique with a 32G 4mm needle, from the angle of 15-30°, with an interval of 10 days between treatment sessions. The examination of the parameters was repeated during the treatment series and after the last treatment. The results were evaluated by statistical analysis.

16:30 - 16:45

Microneedling Delivery of Botulinum Toxin Versus Its Intradermal Injection in The Treatment of Facial Hyperhidrosis

Amany Nassar MD | Professor and Head of the Dermatology department

The objective was to study the efficacy and safety of botulinum toxin-A delivery by microneedling versus its intradermal injection in the treatment of FH. Forty-two patients with FH were subjected to microneedling (Mn)

DAY TWO WEDNESDAY

6th March 2024

CONFERENCE HALL 3

COSMETIC & SURGICAL DERMATOLOGY

followed by topical application of BTX-A on one side of the face and intradermal injection of BTX-A (Id BTX-A) on the other side. Two sessions was performed at 2 weeks interval. The assessment tools were Hyperhidrosis Disease Severity Scale (HDSS), dermatology Life Quality Index (DLQI), and patient's satisfaction.

The current treatments of Facial hyperhidrosis (FH) are often limited and are associated by many adverse effects. Objective The objective was to study the efficacy and safety of botulinum toxin-A delivery by microneedling versus its intradermal injection in the treatment of FH. Forty-two patients with FH were subjected to microneedling (Mn) followed by topical application of BTX-A on one side of the face and intradermal injection of BTX-A (Id BTX-A) on the other side. Two sessions was performed at 2 weeks interval. The assessment tools were Hyperhidrosis Disease Severity Scale (HDSS), dermatology Life Quality Index (DLQI), and patient's satisfaction. Results A score one of HDSS was achieved in (85.7%) on the intradermal injected side vs (83.3%) on the microneedling side (P=0.76%). Most of the patients on the injection sides responded with the1st session while the microneedling side responded with the second one (P<0.001). Post-treatment, the DLQI was highly significant on both sides (P<0.001). The side effects were pain in the intradermal injected sides while mild transient erythema occurred on the other side. The microneedling side showed higher patients' satisfaction compared to the intradermal injected side. Conclusion Both techniques were safe and effective in controlling the FH. Microneedling delivery of BTX-A was less painful and had higher patient satisfaction.

16:45 - 17:00

Collagen Zero a New Paradigm in Therapy of Collagen Deficiency in Skin

Stefan Lipp MD | Executive Director and CMO

OVERVIEW Collagen is a main component in the human skin. There are many different collagen types, at the moment 27 are described.

MATERIALS AND METHODES The degradation and detoriation of collagen in the skin is a main component of the aging skin.

PROCEDURE There is a patented new Collagen Typ 0 that can develop into all different collagen in skin.

CONCLUSION It was developed by a british start up and is now available for application to the skin and we found a 32% augmentation of collagen 3 and also very good results in collagen 7.

17:00 - 17:15

Dark Circles Under the Eyes Treatment

Victoria Inene MD | Dermatologist & Aesthetic Medicine Doctor

All new and old treatment for dark circles under the eyes

'Periorbital hyperchromia' – a technical name for dark circles around the eyes Dark circles may be considered cosmetically unappealing, but they are rarely a medical concern

DAY TWO WEDNESDAY

6th March 2024

CONFERENCE HALL 3

COSMETIC & SURGICAL DERMATOLOGY

17:15 - 17:30

Eyebrow Transplant, Is It Worth Doing?

Hossein Yavari MD | Specialist Dermatologist

Eyebrow Transplant is considered the toughest and most complicated type of hair transplant in the field of hair restoration surgery. Many patients are absolutely unsatisfied for the rest of their lives with the way their eyebrows look after surgery and are completely disappointed with horrible unnatural look. The disastrous part of improper eyebrow transplant is that patients cannot undo the eyebrow transplant and they would suffer from ugly eyebrows entire their life. Thanks to new techniques and skills of advanced eyebrow transplant, the dark corners of eyebrow transplant are now more understood and patients can appreciate the natural, permanent, full, greatly angled and beautiful eyebrows entire their life.

Lack or thin eyebrows may have several reasons including genes, over-plucking, permanent tattoos, hair disease or simply some people just like to have fuller, longer or wider eyebrows. Eyebrow transplant can address all these issues. It's believed as the hairline frames the face, eyebrows delicately frame the eyebrows. Aside from aesthetic point of view, eyebrows have important physiological roles in face and specifically eyes. Eyebrows have a unit function to protect the eyes from foreign bodies, moisture and sweat. They are also the great provider of subtle shade from the sun and glare. They have a very important aesthetic role to convey the emotion and expressions as well as the facial attractiveness. Eyebrow transplant surgery is a well-known aesthetic procedure across the world that involves the harvesting hair from the back of scalp, dissecting the hair under a stereo microscope to single hair follicles. These individual hair are inserted into the pre-made sites artistically to create perfect natural eyebrows. The most critical part of eyebrow transplant is the unique directional changes of eyebrow which plays the main role in creating the desired eyebrows. Missing the directional changes in each single segment of eyebrows can lead to extremely ugly and artificial results and it can be a big regret for patients entire their life. This unwanted shape of eyebrows is unfortunately irreversible and stays with patients permanently. The surgeon's skill is the most crucial part of surgery making sure each hair is implanted in the correct direction, distribution and angle otherwise eyebrow transplant could turn to a permanent regret. Every patient has full control in the shape, length and the width of eyebrows and each eyebrow needs the average of 100-500 hair follicles depending on the existing eyebrow and desired shape. Eyebrow transplant also like any other hair transplant surgery can be done in two ways of FUE (Follicular Unit Excision) and FUT/FUSS (Follicular Unit Strip Surgery). The only difference between these two techniques is the type of scar on the donor area which in FUE there would be invisible round scars whereas in FUT/FUSS there would be a strip or linear scar on the back of scalp. Additionally, in FUE the quality of grafts might be slightly inferior to FUT/FUSS. The most critical part of eyebrow transplant is creating the unique directional changes of eyebrow hair which is different from the head of eyebrow next to the nose until the tail of eyebrow. This is the part can lead to a beautiful natural eyebrow or could result in an ugly artificial eyebrow. Eyebrow transplant has another hidden point that some practitioners don't share it with the patients at first and once the final results appear it becomes disappointing for many of them. This is about the texture and growth rate of hair. Because the transplanted hair is taken from the back of scalp, the characteristics of this hair is slightly different from natural eyebrow hair. The surgeon should use the thinest and finest hair from the back of scalp in order to avoid the unmatched and thick hair texture on the eyebrows. Coarse donor hair tends to stick up more than fine hair. This is perhaps not a big issue for men as they have "bushy" eyebrows but can be a long term annoying issue for women who desire soft-groomed and feminine eyebrows. To sum up, eyebrow transplant can be a game changer for the appearance of patients without eyebrows or with thin eyebrows but at the same time could be a lifelong regret if the principals of eyebrow transplant is not considered by the surgeon.

DAY TWO WEDNESDAY

6th March 2024

CONFERENCE HALL 3

COSMETIC & SURGICAL DERMATOLOGY

17:30 - 17:45

The Lipid Shield of The Skin How to Protect the Skin Protection

Stefan Lipp MD | Executive Director and CMO

OVERVIEW The lipid shield plays a key role in protection of skin and the whole body therein. The sebum in its integrity and its composition is the focus in our investigation.

MATERIALS AND METHODES We reviewed and analyzed the clinical situation, as well as the current finding in our clinic.

We look into all the details of the lipidic shield and what happens during aesthetic procedures.

Then possibilities to improve the lipid barrier will be discussed.

PROCEDURE Many of today's intervention have an impact on the lipidic barrier, both negative and positive.

Especially after ablative and abrasive procedures the lipidic barrier has to be restored.

CONCLUSION We have defined different solutions to restore and replenish the lipidic shield which is the key to a flawless skin.

17:45 - 18:00

Face Lift And Rejuvenation by Monofilament and Cogged Polydioxanone Threads

Amany Nassar MD | Professor and Head of the Dermatology department

As we age, Sagging and laxity in the soft tissues leads to ptosis of eye brows, jowl formation, prominent nasolabial fold, malar flattening and appearance of rhytides (1). In the last decade, there was interest in threads lift as good alternative therapy for lifting the face in patients who don't like fillers or refuse surgical face lift. It is minimally invasive procedures with fewer operating time and less side effects. The surgical facelift associated with long downtime, cost more and much postoperative complication (2-4). polydioxanone (PDO) thread is crystalline, absorbable sutures of non animal origin that gives a natural looking appearance. It is absorbed within six to eight months gradually by the body. It is divided into monofilament and cogged one (5). Monofilament threads improve the texture and tone of the skin inducing rejuvenation. Barbs threads act as cogs to hold and lift redundant skin area. According to barbs, the cogged threads types are unidirectional and bidirectional type. In unidirectional threads the cogs make the suture to move in one direction only and not to move in the opposite one. Bidirectional cogged thread is free floating, it can be placed through hollow needle to engage and lift the tissue (6,7). Both types of threads can be used together; they can be used in combination with other treatment modalities. Previous published data have demonstrated that the threads act as a foreign body reaction in the dermis and subcutaneous tissue which induce fibrosis along the suture barbed track. The threads improve blood flow, stimulate collagen, increase skin tightening and they give youthful look (8). The threads may be associated with side effects as infection, hematoma, facial asymmetry, puckering and dimpling which are easily corrected or resolve by time, suture extrusion and palpable suture in cases of superficial placement. For better outcomes, assessment of the physical problem, proper patient's selection, choosing the appropriate threads and appropriate technique for each patient, focus on the specific defect and areas of patient interest

Background Facial aging is a challenging cosmetic problem for which various treatment modalities have been applied. Objective Was to evaluate the efficacy and tolerability of monofilament and cogged polydioxanone (PDO)

DAY TWO WEDNESDAY

6th March 2024

CONFERENCE HALL 3

COSMETIC & SURGICAL DERMATOLOGY

threads for face lift and rejuvenation for youthful look. Materials and methods Thirty female patients with different types of facial wrinkles were enrolled in this study. Patients were assigned randomly into two groups; each group included fifteen patients. Group 1 was received one session placement of monofilament PDO threads in each side used for skin rejuvenation. Group 2 was treated by one session placement of cogged PDO threads in each side used to correct sagging tissues of the lower face. Clinical improvement was evaluated by two experienced dermatologists using global aesthetic improvement scale (GAIS). Patient's satisfaction was recorded. Results Excellent improvement was detected in 46.7% of patients and good improvement was detected in 33.3% of patients after one week in group1. As regards to cog threads, at 6 months, 46.7% showed excellent improvement and 26.7% showed good improvement in group 2. Conclusion Monofilament and cogged PDO facial threads are easy, safe, tolerable and economic method for face lift and rejuvenation.

18:00 - 18:15

Evaluation of Outcome of 808nm Diode in Hirsutism

Sharmin Jahan MD | Consultant Dermatologist

Introduction: Facial hirsutism and hypertrichosis are common problems, and several methods are available to clinicians for unwanted hair in a large number of patients. The theory of selective photo thermolysis has revolutionized laser hair removal in that it is effective and safe when operated by sufficiently trained and experienced professionals.

Objective: To evaluate the outcome of the 808nm Diode laser in removing unwanted facial hair. Materials and **Method:** 38 patients completed their treatment course with an 808nm Diode with fluences between 16 J/cm(2) and 20 J/cm(2). The average reduction in hair density was assessed using hair count on digital photographs at removal 3, 6 and 9 months postoperatively. The hair-free interval was also evaluated. Results: The average reduction of in the hair count (the same diameter as the baseline for the criterion) after the sixth session of laser hair reduction, excellent response (> 75% reduction) from baseline was seen in 79.9% of patients, good response in 14.3% of patients and fair response in 7.8% of patients. Coarse and darker hair shows much improvement. No significant complications were observed in the range of skin types treated, though darker skin requires less energy. Adequate fluence and pulse duration could be the key to achieving long-term hair reduction with a Diode laser.

DAY TWO WEDNESDAY

6th March 2024

CONFERENCE HALL 4

ASSOCIATION PROGRAM

Session 4: Rafidianderma Forum for Dermatology and Aesthetics (RFDA) Session

Chairperson: Khalifa Sharquie MD

08:30 - 08:45

Procedural and Laser Treatment of Acne Scar

Muhsin A. Al-Dhalimi MD | Professor of Dermatology and Head of the Department of Dermatology and Venereology

BACKGROUND: Acne scars are common permanent disfiguring sequel of acne encountered in daily dermatologic practice.

OBJECTIVE: To evaluate the effectiveness and safety of diffirent methods for the treatment of mild and moderate acne scars. They included punch exicion, subsicion, 25% trichloroacetic acid (TCA) alone or followed by manual dermasanding in repeated sessions, Er:glass and Er:YAG laser.

METHODS: 73 patients with variable types of acne scar was included in this study. The regimen of treatment was varied according to the method used. The patients were assessed at 1, 3, and 6 months after the last session. The effect of treatment was assessed by objective (Sharquie scoring system for grading acne scarring and visual analog scale) and subjective (patient satisfaction) methods.

RESULTS: All methods leads to good imrovement in the appearance of acne scars but the patient satisfaction was variable. No single method fufill the expectation of the patient or the treating physician.

CONCLUSION: the diffirent types of acne scars makes no single method is efficient in all patients. Combination treatment is necessary to overcome all types of atrophic acne scars.

08:45 - 09:00

Sarcoidosis As Un Upsuring Mimicking Granulomatous Disease

Khalifa Sharquie MD | Professor of Dermatology

Background

Cutaneous manifestations of sarcoidosis are seen in around 25% of patients with sarcoidosis that usually accompany systemic involvement although pure cuataneous sarcoidosis could be recognized. Non-caseating granuloma is the classical histoapthological picture.Sarcoidosis is a rare and not well established disease in countries of middle east. Also sarcoidosis share many clinical and histopathological features with many granulomatous disease like granuloma annularae, granulomatous rosacea,leprosy and tuberculosis which is still endemic in many countries.

Objective: To do full clinical and histopathological evaluation of all cases that were diagnosed sarcoidosis trying to find clinical limitations and borders between sarcoidosis and other granulomatous diseases

Patients and methods: This is a cross sectional case descriptive study where all patients that were diagnosed sarcoidosis during the period from 2014-2023 were assessed regarding demographic features, clinical pictures and histopathoogical examination.

Results: This study included 24 patients, their ages ranged from 25-70 years with a mean 55years with 16 females and 8 males with a ratio 2:1.All patients had shiny smooth skin colored or dusky red papules,nodules or plaques but

DAY TWO WEDNESDAY

6th March 2024

CONFERENCE HALL 4

ASSOCIATION PROGRAM

ralely scaly .The color of rash could be skin-co;ored,red,dusky red or even could be pigmented.The rash was usually asymptomatic or there was slight itching.The morphological pictures of the rash could be papular,nodular,plaques or lumps and tumors.The distribution of rash could be classified into localized and generalized picture .The dermatological features of sarcoidosis could be classified into the following dermographic pictures:lupus pernio like,granuloma annularae like,granulomatous rosacea like and tuberculosis like.No obvious systemic involvements were detected by physical examination or investigative techniques like X ray or sonagraphy except in one male patient who progressed into sarcoidosis-lymphoma syndrome and that ended with death The histopathological assessment showed marked granulomatous reaction consisting of multiple non caseating non necrotizing granuloma formation with little or no inflammatory reaction so called naked granuloma and these granuloma were loaded with foamy cells.While there were different types of giant cells. in 2 ()female patients,annular lesions in 3() patients 2 females ,one of them had scar sarcoid reaction and one male patient,3() patients one male and two female with papulo-nodular lesions that either localized to face and head or generalized rash,2() pattients,one male and female patients with single nodular lesion,and one() female patient with deep nodular lumps so called profundus type,one() female with palmar erythema.Sarcoidosis-lymphoma syndrome was detected in one patient.

Conclusion: Sarcoidosis is emerging as not rare cutaneous disease that can mimic and compete with other granulomatous diseases like tuberculosis,leishmaniasis,granuloma annularae , granulomatous rosacea and leprosy.There is no specific available test for this disease but the full clinical and pathological features might lead you into the correct diagnosis.So it is a an exclusion disease

09:00 - 09:15

Micro-needling in Melasma: A New Modern Advance Therapeutic Option

Ahmed Abdul-Aziz Ahmed MD | Consultant Dermatologist & Assistant Professor

Melasma is an acquired disorder of hyperpigmentation that is often recalcitrant to current therapies. Microneedling is used to treat scars, striae, and rhytides and has a relatively low risk of post-treatment dyspigmentation. Microneedling (MN) is a novel therapeutic modality in in the field dermatology. Through physical trauma from needle penetration, MN induces a wound healing cascade with minimal damage to the epidermis

A study evaluating the efficacy and safety of microneedling in melasma treatment involved 20 patients with the condition. Microneedling sessions were performed every 2 weeks for 3 months, with six sessions per patient. The response to therapy was measured using the melasma area and severity index (MASI) before and after treatment sessions. Results showed a progressively decreasing MASI score from MASI 1 to MASI 6, indicating that microneedling is an effective and safe tool for melasma treatment.

09:15 - 09:30

Treatment of Pemphigus Vulgaris with the Rituximab

Ali Fadhil Al-Saadi | Professor and Consultant Dermatologist

Background: The previous main therapy of Pemphigus was azothioprime and prednisone but there was failure of therapy in many cases

Objective: To treat all cases of pemphigus with Rituximab.

DAY TWO WEDNESDAY
6th March 2024

CONFERENCE HALL 4
ASSOCIATION PROGRAM

Patients and results: A total of 30 patients treated with Rituximab,their ages ranged from 17-65 years with a mean 45 years,with 20females and 10 males .Full history and examination were carried out and all necessary investigations were done.Full course of therapy was given.

The results were encouraging and all patients had full recovery.

Conclusion: Rituximab is new effective saving drugs with minimal accepted side effects

---

09:30 - 09:45

Treatment of Plane Warts with Long Pulse ND – Yag Laser 532 nm
Haider Al-Sabak MD | Head of Dermatology and Laser Department

Warts are one of the contagious viral diseases that may cause disturbing cosmetic problems. Plane warts represents a common self-limiting viral infection of the skin caused by the Human Papilloma Virus, however, those that do not disappear by themselves can be very difficult to treat with no uniformly effective treatment modality. Objective, to assess the efficacy of long pulsed 532 nm ND:YAG laser in the treatment of plane warts.

In this therapeutic clinical trial study, 34 patients with plane warts were enrolled. Each patient was eligible for up to three treatment sessions administrated at 2 weeks intervals with long pulsed ND:YAG laser at a spot size 3 mm; wavelength 532 nm; pulsed duration 20 ms; and fluence 30 J/cm2. The patients were assessed before each treatment session and at 3 months after the last treatment session.

The response to treatment was graded using four points scale:

Scale 1 = poor: <25%,

Scale 2 = fair: 25%–50%,

Scale 3 = good: 51%–75%,

Scale 4 = excellent: >75%.

Results: Twenty-two patients only with a total of 478 lesions, completed the study; their ages ranged from (6–45) years with a mean ± SD 19.95 ± 13.142 years. Thirteen patients (59.09%) were female and nine (40.90%) were male. The results from this study showing that long pulsed ND:YAG laser 532 nm led to an excellent response in 19 patients (86.36%) in which 15 of 19 patients showed a complete response (78.94%); one patient showed a good response (4.545%), one showed a fair response (4.545%) and one showed a poor response (4.545%) at the end of three-months follow up. The difference was statistically significant; the P value at the three months follow-up was 0.002. The cumulative clearance rate after the first, second, and third treatment sessions was 58.4%, 77.7%, and 89.9% respectively. Recurrence was seen in only one patient (4.545%). Side effects were generally mild and didn't prevent normal activity.

Conclusion: Long pulsed ND:YAG laser 532 nm appears to be an effective method for treatment of plane warts

DAY TWO WEDNESDAY

6th March 2024

CONFERENCE HALL 4

ASSOCIATION PROGRAM

09:45 - 10:00

Efficacy of Low Energy Fractional Co2 Laser in the Treatment of Alopecia Areata

Dindar Sharif Qurtas MD | Dermatologist, Assistant Professor

Alopecia areata is one of the common hair problems in the practice of the dermatologist. There are many methods that have been successfully used in the treatment of alopecia areata, starting from topical steroid, intra-lesional steroids, topical calcineurin inhibitors and many other topical treatments. Systemic therapies also been tried as systemic steroids in the extensive alopecia areata. Recently JAK inhibitors like tofacitinib tried with satisfactory results in some cases. One of the principles of alopecia areata patches is to induce microcirculation, that might induce the growth of hair shaft from hair follicles. In a clinical trial that was conducted by us was to use low level fractional CO2 laser as much as 15 w/sec. The results were compared to the other patch as split face other modality using CO2 fractional laser and topical triamcinolone solution aright after the procedure. The results showed satisfactory results in both modalities with a comparable regrowth in patches with CO2 fractional laser as monotherapy.

Abstract Summary: Alopecia areata is a common skin problem in the practice. Many modalities been used in its treatment. Recently use of CO2 laser in fractional mode been tried. We conducted an interventional study to use fractional CO2 laser in the treatment of patchy from of alopecia areata. The results shows that this method is very tolerable and satisfactory for both patients and treating doctor.

Session 5: Face Aesthetic Dermatologist Society (FADS) Session

Chairperson: TA Rana MD

10:00 - 10:20

Composite and Enriched Facial Fat Grafting

Viral Desai MD | Plastic Cosmetic Surgeon

Fat grafting to the face, a groundbreaking cosmetic procedure, involves the transfer of a person's own fat from one area of their body to enhance facial features. This minimally invasive technique offers a natural and long-lasting solution to restore youthful volume, diminish wrinkles, and improve overall facial contour. As the body readily accepts its own fat, this procedure reduces the risk of allergic reactions or rejection. Mili/ Micro / Nanofat or SVF is used at different levels and planes to get desired results.

Adipose tissue's compatibility diminishes risks, and its regenerative properties yield natural, enduring outcomes. Despite advantages, challenges like unpredictable reabsorption exist. This abstract explores fat grafting's history, techniques, benefits, and limitations, emphasizing its role as a safe and minimally invasive option in facial rejuvenation. I have used Mechanical method for harvesting and SVF extraction and used the various forms of fat and different levels and enriched with SVF to improve survival and results. Continued research is essential for refining practices, ensuring consistent results, and expanding applications in cosmetic and reconstructive surgery.

DAY TWO WEDNESDAY

6th March 2024

CONFERENCE HALL 4

ASSOCIATION PROGRAM

10:20 - 10:40

New Age Thread Lift

Jyotirmay Bharti MD | Consultant Dermatologist & Hair Transplant Surgeon

Two types of threads are available for use in the PDO Thread Lift, including "barbs" for raising the skin and "smooths" and "twists" for decreasing wrinkles, reshaping the nasal area, and enhancing the lips. The procedure causes minimal discomfort and is ideal for use as an anti-aging treatment, to improve facial contours, and to reduce scars. A key benefit of the PDO Thread Lift is that it is performed without the need for general anesthesia and is less costly than a conventional facelift.

Used as an alternative to traditional face-lifting procedures for the face and neck, the PDO (polydioxanone) Thread Lift is minimally invasive and ideal for tightening loose and sagging skin. The Thread Lift procedure involves inserting the threads into the skin's subdermal layer, which immediately firms the skin and stimulates the growth of collagen, which further accelerates skin tightening.

10:40 - 11:00 **Q & A / Break**

Session 6: Pakistan Association of Dermatologists (PAD) Session

Chairperson: Zafer Ullah Khan MD, Saadia Tabassum MD, Shahid Javaid Akhtar MD

11:00 - 11:15

Presentation and Mimickers of Melasma

Shahid Javaid Akhtar MD | Head of Dermatology Department

Melasma is acquired hyper-pigmentation that is not uncommon in our racially pigmented skin. However, there are numerous other hyper-pigmentary conditions that clinically very closely resemble Melasma. Definite diagnosis of any disease is the first step toward successful treatment outcomes. Awareness of other causes of facial hypermelanosis is important to make a correct diagnosis of Melasma.

The differential diagnosis of Melasma is wide and is often a diagnostic challenge for clinicians. This can delay the appropriate treatment, unsuitable therapy, and sometimes leads to worsening of the original clinical condition. Our review, with citation of clinical scenarios, aims to provide clinicians with an understanding of other causes of facial melanosis, diversity of presentation, morphological variants, and a comprehensive approach to make correct diagnosis of Melasma after excluding conditions like Lichen Planus Pigmentosus, Erythromelanosis follicularis facie, PIH, Berloque Dermatitis, Rieh's Melanosis, Addison disease, Hori naevus, etc.

11:15 - 11:30

Treatment Strategies for Melasma

Asma Tariq MD | Senior Registrar

Melasma is an acquired hyperpigmentary disorder with brown to blue grey patches on face and other photo-exposed sites. Melasma has been a therapeutic challenge for dermatologists for many years.it is believed to be caused by a combination of genetic, harmonal and environmental factors. This makes it challenging to develop a

DAY TWO WEDNESDAY

6th March 2024

CONFERENCE HALL 4

ASSOCIATION PROGRAM

one-size-fits-all treatment plan for patients with melasma

Melasma is a multifactorial problem, so its treatment has been problematic too. Addressing various possible factors simultaneously has been a challenge since ages. Furthermore, the pigmentation is not just limited to the top layer of the skin but the deeper layers. No definite treatment guidelines are there and every clinician develops her/his own approach to address these challenges. I will share my own algorithm to treat melasma which has been quite successful. My regimen depends on the type of melasma whether its epidermal, dermal or mixed one.

11:30 - 11:45

Tranexamic Acid for Melasma

Abdul Hameed MD | Medical Director, Consultant

Melasma (a term derived from the Greek word melas, (meaning black) is a commonly acquired hypermelanosis that occurs exclusively on sun-exposed areas, mostly on the face and occasionally on the neck and forearms.

Melasma is a common and distressing hyperpigmentation disorder that primarily affects women of childbearing age While its exact etiology remains difficult to track down, several factors, including hormonal imbalances, UV radiation exposure, genetic predisposition, and certain drugs contribute to its development, multiple treatment options available, Tranexamic acid giving promising results in melasma.

11:45 - 12:00

Multimodality Treatment of Stubborn Melasma

Kalsoom Jawaid MD | Assistant Professor

Melasma is aquired benign hyperpigmentation found on sun exposed areas of face and forearms in females mostly. It is quite common in fitzpatrick skin type III and IV, seen in areas of subcontinent. Its etiology is multifactorial. Melasma is difficult to treat in many cases and we need to try multiple modalities to achieve cure.

Melasma needs to be investigated for its possible aggravating factors, like iron deficiency, hyperestrogenism and sun exposure. Prior to starting any treatment patient must be counselled for strict sun protection and to avoid any estrogen containing OCPs. Step ladder approach must be followed. Iron and vit D supplemetation must be done. Topical treatment at home should be tried first. For the next step, peels can be offered. Mesotherapy has been favourite for many dermatologists. Lasers should be considered as the last option. In many cases, we need to continue with multiple modalities at the same time. I will present a case series of my patients treated by this approach.

DAY TWO WEDNESDAY

6th March 2024

CONFERENCE HALL 4

ASSOCIATION PROGRAM

Session 7: Indonesian Society of Dermatology and Venereology (INSDV) Session

Chairperson: Muhammad Yulianto Listiawan MD

12:00 - 12:15

Picolaser 755 nm with Diffractive Lens Array for Wrinkles in Skin of Color

Muhammad Yulianto Listiawan MD | Professor of Dermatology and Dermatovenereologist

Wrinkles are one of signs of skin aging, appeared because of the decrease in collagen density and dermal thickness. The science and technology of modern engineering for wrinkle improvement has continued to evolve. Skin rejuvenation techniques for wrinkle repair have changed dramatically with the development of lasers. Laser with the latest technology, namely a picolaser 755 nm with a diffractive lens array (DLA) for wrinkles is more effective with minimal side effects, but we still need further exploration to know the safety and effect of this technology in the skin of color.

Picolaser 755 nm with DLA is safe and effective for wrinkles in the skin of color.

12:15 - 12:30

Correlation of Ultraviolet B Intensity and High Vitamin D Food Intake with the Level of 25(OH)D Serum in Healthy Indonesian Children

Srie Prihianti Gondokaryono MD | Dermatovenereologist, Pediatric Dermatology Consultant and Vice President of International Affairs

12:30 - 12:45

Induction of Skin Carcinogenesis with Narrowband UVB (311 nm) Using Wistar Rat Animal Model

Roro Inge Ade Krisanti | Medical Doctor, Dermatovenereologist

Chronic inflamation due to ultraviolet B (UVB) exposure is associated with skin cancer, in which UVB can act as initiator and promoter of carcinogenesis. Narrowband UVB (311 nm) commonly used as phototherapy for some skin disorders, however was found to be more carcinogenic per minimal erythema dose than broadband UVB (290-320 nm). In a two-stage model of skin carcinogenesis in mice, chronic inflammation can be observed within 10 weeks, which represent promotion stage. This preliminary study investigates the effect of narrowband UVB in carcinogenesis process on chemically-induced rat skin model.

The effect of NB-UVB irradiation and administration of DMBA single-dose on the Wistar rat skin model was observed. NFkB and TNF-α as an indicator of inflammation. IL-12 level was measured as a marker for antitumor activity. Prior to radiation, minimal erythema dose test was performed (3.192 J/cm2). Rats were assigned to three groups; control, DMBA, and DMBA+NB-UVB. In week 10, DMBA+NB-UVB group presented chronic inflammation of the skin .Control and DMBA group showed no injuries. Histopathology results were in accordance to macroscopic findings. NFkB and TNF-α level in the rat skin tissue in DMBA+NB-UVB group was higher than other groups. IL-12 level was found to be higher in the DMBA+NB-UVB group compared to DMBA group. A longer radiation period is thought to show a better macroscopic and histological features of skin cancer.

DAY TWO WEDNESDAY

6th March 2024

CONFERENCE HALL 4

ASSOCIATION PROGRAM

12:45 - 13:00

Management of Post Inflammatory Hyperpigmentation

Diah Puspitosari MD | Medical consultant, Member of the research team and Dermatologist practitioner

A correlation has been identified between inflammation and hyperpigmentation, specifically among individuals with darker skin tones. Post inflammatory hyperpigmentation (PIH), is a chronic condition that significantly impairs the quality of life of affected individuals.

There is a lack of thorough, randomized, controlled clinical trials for the therapy of. Therefore, it is impractical to develop therapy recommendations only relying on the available data. However, post-inflammatory hyperpigmentation is a common condition, and it is crucial for clinicians to have guidance on management strategies.

The principal aim of PIH management is to achieve a consistent complexion or one that corresponds with the individual's natural skin tone. The application of topical depigmenting agent has proved to be beneficial and combination therapies have demonstrated advantages in comparison to monotherapy. Treatment of the causative inflammatory disorder, if present, constitutes the initial course of action.

Procedures such as superficial chemical peeling, laser therapy, and micro needling can aid topical therapy. Furthermore, it is important for doing patient counseling to inform that improvement will progress gradually, and recurrences are frequent. The regular utilization of ultraviolet filter in sunscreens products will optimize the efficacy of the treatment.

13:00 - 14:00 Q & A / Lunch BreaK

Session 8: Jordanian Society for Dermatology and Venereology (JSDV) Session

Chairperson: Firas Al Qarqaz MD

14:00 - 14:15

Hidradenitis Suppurativa: Dilemma of Pathogenesis and Therapeutic Options

Salah Abdallat MD | Consultant and Head of Dermatology Department

Hidradenitis suppurativa (HS) is a chronic, recurrent, disabling skin disease with female predominance, and a global prevalence of about 1-4%. It is characterized by inflammation of pilosebaceous units and terminal hair epithelium in apocrine gland-rich skin, resulting in painful nodular skin lesions, draining tunnels, and scars involving axillae, inframammary, inguinal, perineal, and perianal areas.

Follicular occlusion, infection, and immune dysregulation are widely accepted to play roles in the pathogenesis of HS. Despite the availability of many medical and surgical therapeutic options, we are still in need for optimal staging system and guidelines for the management of this disease.

Hidradenitis suppurativa (HS) is a skin disease that is traditionally thought of as a follicular occlusion disorder with subsequent rupture and inflammation leading to painful nodules, tunnels, and scars at apocrine gland-rich skin. But recent data are suggesting inflammation to play an early and primary role, as evidenced by association with other immune-mediated systemic illnesses, rising many questions about our understanding of the pathogenesis of this disease.

In this article we will review the literature discussing the arguments about the different factors implicated in the pathogenesis of HS, and the development of many therapeutic options and strategies targeting theses different etiologic factors.

DAY TWO WEDNESDAY

6th March 2024

CONFERENCE HALL 4

ASSOCIATION PROGRAM

Despite having many severity-scoring and staging systems, none of them sounds to be perfect enough to guide the ongoing research and the development of systematic approach for the management of HS. In this article, we will discuss these different staging systems, as well as the need for clear and functional management guidelines and protocols for HS.

14:15 - 14:30

Acne Vulgaris: More Work still Needed

Firas Al Qarqaz MD | Consultant Dermatologist

Despite being one of the most common skin conditions many questions still not well-answered about acne. The pathophysiology of acne is still evolving. Also, the dynamic nature of acne lesions and its complications are not properly evaluated. Additionally, many questions still bending regarding treatment selection, value of early intervention and length of treatment. Newer treatment options for acne are arising and this can help in better control of acne and its complications.

Acne and acne-related complications are very common and can have significant impact on patients. Advancements in understanding of acne pathophysiology can help in treatment selection. When patients are evaluated in clinics, categorization of acne lesions and scarring risk should be included. The dynamic and changing nature of acne lesions should be also evaluated and treatment plans made accordingly. Proper assessment of acne complications should be considered when treatment is selected to optimize the treatment in individual patients.

Recently, acne and acne complications treatment options are expanding, and this will help clinicians achieve better outcomes.

14:30 - 14:45

Biologic Treatment of Psoriasis at Individual Level

Salah Abdallat MD | Consultant and Head of Dermatology Department

Psoriasis is a chronic, immune-mediated, skin disease with a global prevalence of about 1-3 %. It is associated with many systemic comorbidities, with psoriatic arthritis being the most common. Advances in understanding the pathogenesis of this disease have revealed targets (TNF, IL-17, IL-12/23, and IL-23p19) that allowed for the development of many biological drugs that deal with this disease in a more holistic approach. However, there is still an unmet need for clear guidelines and recommendations to help practitioners make their decision about the best choice of biologics for their individual patients.

Better understanding of the pathogenesis of psoriasis has led to great advances in treatment this disease. Biologics, as compared to previous treatments, have offered superior therapeutic option in terms of efficacy, safety, and convenience. However, there is significant individual variation in safety profile and response to different biological drugs, leading to significant rate of discontinuation and shifting between biologics. This fact mandates searching for reliable predictive biomarkers to recognize the optimal biologic drug, in terms of efficacy and safety, at individual level. In this article, we will review the attempts to cluster patients into subgroups - based on factors like gender, age group, and comorbidities – in relation to relative efficacy of different biologic drugs. Use of machine learning to aid in identifying the optimal biologic drug for patients of psoriasis, at subgroup and individual levels, will be discussed as well.

DAY TWO WEDNESDAY

6th March 2024

CONFERENCE HALL 4

ASSOCIATION PROGRAM

14:45 - 15:00

Apremilast, A Small Molecule with Big Potential

Firas Al Qarqaz MD | Consultant Dermatologist

Apremilast is a new oral small molecule that acts by inhibiting phosphodiesterase-4. This is a new line of mechanism of action for immune modulation which is expressed in many inflammatory cells. This explains the wide potential for using this drug in wide range conditions where inflammation is derived by this mechanism. The safety of this medication is another important plus factor for the drug which is an important consideration when selecting immune modulatory treatment especially for long-term use.

There are many dermatologic conditions that involve immune activation and dysregulation. Most of these conditions are chronic and require long-term treatment. For long time, our armamentarium of immune suppressive or modulatory treatment has been limited by type and by serious complications especially with long term use of these agents.

Over the past few years, we saw many new newer immune modulatory drugs that were more selective and effective. However, all medications have their limitations in terms of efficacy, safety and cost. Still, these newer agents have improved the treatment outcomes for many conditions and have become an important part of the treatment options we have.

Apremilast, with its unique mechanism of action and safety profile is also finding its way into our practice as viable treatment options for many conditions such as psoriasis and psoriatic arthritis, oral ulcers and many other immune mediated conditions.

An important question that we need to answer is where is the right position of such new options including apremilast in the treatment of various conditions.

Session 9: Oman Dermatology Society Session

Chairperson: Ahmed Al Waily MD

15:00 - 15:15

Difficult to Treat Psoriasis

Ahmed Al Waily MD | Senior Consultant Dermatologist

Psoriasis is a common autoimmune multisystem Disease with variable presentations and severity affecting the patient Quality of Life.

Psoriasis when affects certain body parts like the scalp, palmoplantar, and intertriginous skin. These sites although by severity scores are mild but by the Quality of life index they are severe. Treatment Options and an update on the literature in the management of the difficult to treat psoriasis will be presented.

15:15 - 15:30

Dermatodietitics: Unveiling the Impact of Nutrition on Dermatological Health and Diseases

Amera Elsayed Bayumi MD | Aesthetic Dermatology specialist

The intersection of diet and dermatology is enormous, there is profound impact of dietary choices on dermatology health and harmony. In this lecture we will gain insights of how dietary modification can be used to prevent or

DAY TWO WEDNESDAY
6th March 2024

CONFERENCE HALL 4
ASSOCIATION PROGRAM

manage skin diseases. Also, we will highlight the effect of our dietary habits on some dermatological diseases like Atopic dermatitis, Acne, chronic urticarial, psoriasis, No melanoma and melanoma skin cancers

15:30 - 15:45 **Q & A / Break**

Session 10: Emirates Dermatology Society (EDS) Session
Chairperson: Raghda Al Maashari MD, Jawaher Alnaqbi MD

15:45 - 16:05

Filler Migration, A Trending Issue After Years of InjectingHyaluronic Acid
Safa AlSaadi MD | Specialist Dermatologis

Hyaluronic Acid filler presence has been demonstrated up to 12 years post-placement, well beyond manufacturers' claims of 6-24 months. With the common and random use of fillers, newer complication have raised. Learning to diagnose and treat such complication is necessarily. Filler migration is diagnosed when filler material is confirmed at locations distant from the site injected. Lip fillers is one of the most common cosmetic procedures performed so It will be my focus . Pathogenesis : injection technique , Poor technique , High volume of filler injected , muscle activity , Lymphatic spread ,intravascular injection .

Abstract Summary: Diagnosis of migrated HA filler may be made through biopsy or magnetic resonance imaging scanning or ultrasound scanning. Clinical examination and history taking is most important. The use of hyaluronidase enzyme to dissolve is the treatment of choice. Dose usually depends of the volume of migrated filler, the viscosity, cohesiveness and hydrophilicity of the filler.

Challenges: filler resistance to hyaluronidase treatment is reported. Tips to avoid migration in

lips: Slow pressure of injection , DONT inject white line , Low volume injection , Choosing the correct agent.

Message: If the patient presents with a mass or nodule distant to the injection site months or years after placement of dermal fillers, it may not be immediately obvious to include filler migration in a differential diagnosis

16:05 – 16:25

Lupus: "The wolf"
Raghda Al Maashari MD | Dermatology Consultant

Lupus erythematosus is a common multisystem disorder with a significant morbidity and mortality. Cutaneous LE pathogenesis is complex, and it involves an interaction between genetic and environmental factors.

Cutaneous lesions can vary in presentation and can be a source of disability and, on many occasions, an indicator of internal disease.

Lupus erythematosus is a common multisystem disorder with a significant morbidity and mortality. Cutaneous LE pathogenesis is complex, and it involves an interaction between genetic and environmental factors.

Cutaneous lesions can vary in presentation and can be a source of disability and, on many occasions, an indicator of internal disease.

The aim of this talk is to highlight the various lupus subtypes, clinical presentations, diagnostic work up and updated management strategies

DAY TWO WEDNESDAY

6th March 2024

CONFERENCE HALL 4

ASSOCIATION PROGRAM

16:25 – 16:45

Clinical Features and Management of Inducible Urticaria

Udaya Kumar Padubidri MD | Consultant Dermatologist and Head of

Physical urticarias are disorders in which urticaria (ie, hives or wheals) are induced by environmental stimuli, such as heat, cold, pressure applied to the skin, exercise, water, vibration, and sunlight. The term "inducible urticaria" was preferred by a 2018 international guideline. These disorders probably result from heightened sensitivity by the mast cell to environmental conditions, although the exact pathogenesis is unknown. There are significant number of patients are suffering from Chronic Inducible Urticaria mistaken as Chronic inducible spontaneous urticaria and been advised and treated inappropriately.

Chronic inducible urticaria (CIndU) is a common inflammatory skin condition characterized by the recurrence of itchy wheals and/or angioedema that lasts more than 6 weeks and is induced by specific physical or environmental stimuli (cold, heat, exercise, pressure, sunlight, vibration, water, etc.). According to the current international classification, it includes physical urticarias (dermographism, delayed-pressure urticaria, exercise-induced urticaria, cold urticaria, heat urticaria, solar urticaria, and vibratory urticaria) and non-physical urticarias caused by exposure to specific stimuli (cholinergic urticaria, contact urticaria, and aquagenic urticaria). In terms of frequency, more common types of CIndU are dermographism, cholinergic urticaria, and delayed-pressure urticaria. In clinical practice, it is often difficult to define the exact type of CIndU; management thus begins with accurate identification of a possible trigger and its avoidance. The definite diagnosis for CIndU requires obtaining a detailed medical history of a patient with comprehensive information about predisposing factors, physical examination, and provocation testing (challenge tests). It is always necessary to recognize the prophylactic options for all the types and to have access to different therapies (primarily second-generation H1 antihistamines, but also H2 antihistamines, hydroxyzine, doxepin, oral glucocorticoids, omalizumab/anti-IgE therapy, phototherapy, physical desensitization, immunomodulatory agents, etc.) individualized for each patient.

WONDER FIT

contouring serum for localized fat reduction

ABSTRACTS

Thursday I 7 MARCH 2024

DAY THREE

CONFERENCE HALLS

1 | 2 | 3 | 4

DAY THREE THURSDAY

7th March 2024

CONFERENCE HALL 1

DERMATOLOGY SCIENCES & RESEARCH

Session 8

Chairperson: Mahdi Shamad MD, Dhaifallah Alghowairi MD

08:30 - 08:45

Dermatophytosis Severity Score- A Novel Method to Assess Severity of Superficial Fungal Infections & It's Clinical Implications

Ramesh Bhat MD | Vice Dean and Professor of Dermatology

Dermatophyosis severity score is a new method to assess the severity of superficial fungal infections developed by us and published. We have taken various criteria to arrive at an objectively reproducible format which is of immense help in arriving at a conclusion regarding how to manage Dermatophytosis and also to assess the prognosis.

We have described a tool to assess the severity of Dermatophytosis and validated for it's accuracy. We have taken various criteria to assess the severity including the nail involvement. We have used to correlate this with disease severity and type of treatment given. Steroid modified tinea also can be assessed using this tool to assess the severity.

08:45 - 09:00

Parasitic Infestations of the Skin: Clinical Presentations and Photos

Mahdi Shamad MD | Associate Professor and Dean

Parasites can infest the skin causing different skin diseases. It is worth to give an up-to-date revision of this topic.

Parasites can infest the skin causing different skin diseases. It is worth to give an up-to-date revision of this topic. We hear present clinical pictures and related literature of the most common parasitic infestations encountered in our Region. These include Scabies, Pediculosis, Onchocerciasis, Larva migrans and some others will be discussed. Related photos of the cases will also be presented.

09:00 - 09:15

Paraneoplastic Dermatosis

Monira El Waseef MD | Fellowship trainer

Skin manifestations of systemic diseases and malignancy are extremely polymorphous. Dermatologists should be familiarized with paraneoplastic dermatoses in order to perform an early diagnosis of the underlying neoplasm.

09:15 - 09:30

Clinical Manifestation of Some Oral Diseases

Nadia Abdelwadood MD | Consultant of Dermatology and Sexually Transmitted Infection

The mucosa of the oral cavity is very important from the dermatologist's point of view as it originates from the ectoderm, The structure and the lining of the oral cavity has importance in the diagnosis of both oral and systemic

DAY THREE THURSDAY

7th March 2024

CONFERENCE HALL 1

DERMATOLOGY SCIENCES & RESEARCH

diseases, as it is the site of various isolated mucosal lesions as well as mucosal lesions of systemic diseases. Diagnosis depend on history, clinical picture, histopathological and investigations.

09:30 - 09:45

Skin Manifestations Following Eating Some Types of Spoiled Fish

Omar F. Najjari MD | Paediatrician & Paed. Toxicologist

What is The ideal treatment for skin symptoms caused by eating spoiled marine fish.

On the Syrian coast, due to the deteriorating economic conditions, A portion of the population depends on sardines and tuna for their nutrition, that are not well preserved, So Cases of skin symptoms resulting from eating these spoiled fish, are increased, Due to the absence of refrigeration methods.

These skin manifestations result from the accumulation of histamine in spoiled fish, it is chemical poisoning caused by the accumulation of histamine in eaten spoiled fish , so they are not considered an allergic reaction or food poisoning, but rather histamine poisoning, so the best treatment for them is antihistamines only.

09:45 - 10:00

Muir-torre Syndrome and Sebaceous Hyperplasia

Huda H. Tahlawi MD | Dermatologist & Venereologist

Sebaceous hyperplasia has been reported in association with internal malignancy in the setting of Muir-Torre syndrome.

Muir-Torre syndrome includes malignant tumors, especially in the colon, with an increased risk of developing skin diseases (malignant or benign skin tumors). Therefore, it is considered a form of Lynch syndrome.

Although the most common malignancy is colon cancer, several other cancers have been described in association with Muir-Torre syndrome including malignancies involving the endometrium, cervix, ovaries, breast, small intestine, bone, bile duct, brain, and pancreas. , upper urinary epithelial tract, lymphoma, leukemia, and lung.

In my study, sebaceous hyperplasia in the first case was accompanied by a nodular basal cell carcinoma on the chest along with the family history: the father died of colon cancer that had metastasized to the lung, he had two brothers who died of cancer, the first died of laryngeal cancer and the second died of kidney cancer, his uncle died of prostate cancer, and his second uncle died of stomach cancer. His cousin now has a high-grade urinary tract cancer that is being treated.

In the second case, sebaceous hyperplasia was accompanied by a malignant tumor that was removed from the nasopharynx and then Metastasized.

DAY THREE THURSDAY

7th March 2024

CONFERENCE HALL 1

DERMATOLOGY SCIENCES & RESEARCH

10:00 - 10:15

Cutaneous Changes Associated with Menopause

Harb Al-Omari MD | Consultant Dermatology, Andrology & STDs

Cutaneous changes associated with menopause Menopause, which officially begins one year after your last period, can bring with it some noticeable cutaneous changes. Most noticeable is age spots and other signs of sun-damaged skin that include exaggeration of demarcation on face.

Abstract Summary

Cutaneous changes associated with menopause Menopause, which officially begins one year after your last period, can bring with it some noticeable cutaneous changes. Most noticeable is age spots and other signs of sun-damaged skin that include exaggeration of demarcation on face. As estrogen levels fall, skin becomes thinner causing Xerosis Cutis through the dysfunction of lipid barrier followed by pruritus that increases bruises and PIH more easily with development of hyperpigmented hyperkeratotic changes on bones. As Testosterone T & Estradiol E2 have same receptor with menopause gradual E2 receptor is sloughed causing face hypertrichosis and Female Pattern Alopecia that progress with aging. In menopause, skin quickly loses collagen and less of elastin associated with diffuse pigmentation and skin loses it firmness and begins to sag, Jowls appear developing ptosis of eye brows and lids, crow's feet wrinkles, lower eyelids bulge Bony changes causes palpebral-malar groove, malar mound, mid-cheek grove, naso junctional groove, nasolabial groove and marionette lines. Wrinkles that used to appear only with a smile or frown become visible all the time. As levels of female hormones drop before and during menopause, some women develop acne on cheeks or back which is mostly "Pityrosporum folliculitis" that causes fine pitting scars. The pH level of skin is changes & skin becomes more sensitive, and women are more likely to develop rashes and easily irritated skin. Management of these changes also will be presented.

Learning Objectives

Wrinkles that used to appear only with a smile or frown become visible all the time. As levels of female hormones drop before and during menopause, some women develop acne on cheeks or back which is mostly "Pityrosporum folliculitis" that causes fine pitting scars. The pH level of skin is changes & skin becomes more sensitive, and women are more likely to develop rashes and easily irritated skin. Management of these changes also will be presented.

Materials and Methods

Menopause, which officially begins one year after your last period, can bring with it some noticeable cutaneous changes. Most noticeable is age spots and other signs of sun-damaged skin that include exaggeration of demarcation on face. As estrogen levels fall, skin becomes thinner causing Xerosis Cutis through the dysfunction of lipid barrier followed by pruritus that increases bruises and PIH more easily with development of hyperpigmented hyperkeratotic changes on bones.

Results

Menopause, which officially begins one year after your last period, can bring with it some noticeable cutaneous changes. Most noticeable is age spots and other signs of sun-damaged skin that include exaggeration of demarcation on face. As estrogen levels fall, skin becomes thinner causing Xerosis Cutis through the dysfunction of lipid barrier followed by pruritus that increases bruises and PIH more easily with development of hyperpigmented hyperkeratotic changes on bones.

Conclusion

Wrinkles that used to appear only with a smile or frown become visible all the time. As levels of female hormones drop before and during menopause, some women develop acne on cheeks or back which is mostly "Pityrosporum

DAY THREE THURSDAY

7th March 2024

CONFERENCE HALL 1

DERMATOLOGY SCIENCES & RESEARCH

folliculitis" that causes fine pitting scars. The pH level of skin is changes & skin becomes more sensitive, and women are more likely to develop rashes and easily irritated skin. Management of these changes also will be presented

10:15 - 10:30

Methotrexate Gel Either Alone or Combined with Narrow Band Ultraviolet B or Excimer Light for the Treatment of Vitiligo

Khaled Gharib MD | Professor of Dermatology and LASER

Introduction & Objectives: Methotrexate has been used successfully in the treatment of vitiligo. It leads to decrease in the number of TNF-α secreting T cells in association with increase in the number of interleukin (IL)-10 producing T cells. Topical forms of methotrexate do not have significant hematologic or hepatotoxic side effects unlike the systemic forms of the drug. OBJECTIVE: We sought to evaluate the efficacy and safety of methotrexate gel for the treatment of vitiligo, either alone or combined with narrowband (NB) ultraviolet B (UVB) or with excimer light.

Materials & Methods: Forty-eight patients with vitiligo were randomized into three treatment groups. Group I was treated with methotrexate gel twice daily. Group II was treated with methotrexate gel twice daily plus NB-UVB twice weekly. Group III was treated with methotrexate gel twice daily combined with excimer light twice weekly. Treatment was continued for three months followed by a one-month follow-up period. Results: there was a statistically significant difference between groups regarding the therapeutic response. The highest response was recorded in the group treated with methotrexate gel and NB- UVB. More patients in Group II showed good or excellent response than in the other groups. Conclusion: Methotrexate gel could increase the therapeutic effect of NB- UVB and excimer laser and shorten the treatment period of vitiligo. However, it was not effective enough to induce repigmentation when used alone.

10:30 - 11:00 **Q & A / Break**

Session 9

Chairperson: Ahmed Al Waily MD, Fatima Al Shamsi MD

11:00 - 11:15

Skin Thickness and Internal Organ Involvement in Patients of Scleroderma

Fareheen Ashfaq MD | Consultant Dermatologist

Systemic sclerosis (SSc) is an autoimmune multisystem disease characterized by inflammation and excessive deposition of extracellular matrix in the skin and internal organs.[1] Systemic sclerosis (SSc) can be further classified into diffuse cutaneous SSc (dcSSc) or limited cutaneous SSc (lcSSc) based on the extent of skin and internal organ involvement.[2] Skin involvement in dcSSc may go through 3 phases starting from an edematous phase that usually lasts 6–12 months then a fibrotic phase that lasts from 1–4 years or longer and finally atrophic phase that lasts for rest of the patient's life.[3] During the first phase of skin thickening, patients develop internal organ involvement . In addition, worsening skin thickness is a predictor of morbidity and mortality. Therefore, current efforts are directed in early diagnosis of internal organ involvement and institute therapies. And it has been shown that softening of skin is associated with improved survival. [4] The modified Rodnan skin score (MRSS), a measure of skin thickness has been used as the primary outcome measure in most of these trials, as it is

DAY THREE THURSDAY

7th March 2024

CONFERENCE HALL 1

DERMATOLOGY SCIENCES & RESEARCH

feasible, reliable, valid, and responsive to change in multicenter clinical trials. [5] All recent studies of mortality in SSc have concluded that patients with diffuse skin involvement are at an increased risk of death compared with those with limited skin disease. T Nevskaya et al.[6] have shown that progression of visceral disease, including deterioration in cardiovascular, renal and pulmonary function occurred earlier in patients with a higher initial mRSS and rapid skin thickening progression. So the rationale of my study is to elucidate the current magnitude of the internal organ involvement in the patients of systemic sclerosis with respect to their MRSS which would be helpful in identifying such patients with greater risk of internal organ involvement at presentation and their early identification would help us to formulate a proper management

Objective : To elucidate the current magnitude of the internal organ involvement in the patients of systemic sclerosis with respect to their MRSS which would be helpful in early identification and proper management plan. Methods: Total 52 patients were included. Skin thickness calculated by MRSS, internal organ by history, examination, vitals and investigations like Serum Creatinine, Transthoracic echocardiography, HRCT and PFTs. Relation of skin thickness and internal organ involvement was studied. The Data was analyzed on software SPSS version 24.0. Results: Our study comprises of 52 patients with mean MRSS score 19.4 ± 10.53, predominant females 88.4% and mean duration of systemic scelerosis 6.3 ± 6.2. The internal organ involvement with respect to modified rodnan skin score (MRSS) having score >20 shows more involvement of pulmonary 46%, cardiac 15.4% and renal 21.1%, more in age group >32 and in females. In patients with score >20 showed predominant pulmonary 67.3% followed by pulmo-renal 11.5%, pulmo-cardiac 5.7% and pulmo-renal-cardiac in 9.6% patients (p value 0.00). Conclusion: Our study shows the 94% involvement of Pulmonary Organ. Stratifying such patients with greater risk of internal organ involvement at presentation and their early identification help us to formulate a proper management plan that reduces morbidity and provides better survival.

11:15 - 11:30

PRP Emerging Role in Acne Scars

Soha Khan MD | Consultant Dermatologist

Role of PRP in acne Scars treatment - it is one of the most promising upcoming treatment methods in Acnee Scar management

Platelet Rich Plasma Therapy is now emerging as one of the safest adjuncts to the treatment of acne scras, yielding faster and beautiful results. On the basis of level 1 evidence - PRP can improve the quality of atrophic acne scars treated with ablative fractional CO2 laser and decrease the duration of laser-related side effects including oedema and erythema. Regarding surgical scars - PRP may improve wound healing and early scar quality. Incorporation of PRP in fat-grafting procedures undertaken in conjunction with non-ablative, fractional laser can contribute to better wound healing as well as a significant improvement in texture, colour and contour in traumatic scar resurfacing. We have used it with energy-based devices like MNRF as well and achieved great results in half the time. Here we are presenting a series of 10 cases with 70 to 90% results achieved. CASE REPORT Presenting a series of cases, ranging betweeen 20 to 40 years of age, with varied types of acne scars. We have used PRP as an adjunct to MNRF and/or Fractional Co2 to reduce the scar depth and thickness and allowing better healing with lesser downtime, with a minimal of 4 sessions for lesser depth of scar and a maximum of eight sessions for deeper and older scars. DISCUSSION Platelet Rich Plasma therapy is one of the safest treatment modules that a dermatologist has at her disposal, owing to the fact taht preparation when done with all safety guidelines in place, primarily utilises the patient's own blood and is injected intra-dermally as soon as the preparation is ready. Various factors influence the yield of PRP such as - draw of blood, speed, time and temperature of centrifugation and use

DAY THREE THURSDAY

7th March 2024

CONFERENCE HALL 1

DERMATOLOGY SCIENCES & RESEARCH

of anticoagulants. Method of preparation of PRP is by double spin method. Injection of PRP is done intradermally, post a session of MNRF or Fractional CO2. Compared to plain MNRF sessions which take a minimum of 6 to 10 sessions in atrophic and rolling scars, Addition of PRP gave us similar results in 4 to 6 sessions. Also, post procedure downtime was reduced in many cases, PIH after Fractional Co2 Laser was lesser and resolved within 3 to 4 days, as compared to without PRP, when it was a minimum of 8 to 12 days in Indian Skin. CONCLUSION Hence shown through this case series, that PRP is one of the best and safest modalities among the armamentarium at our disposal, and along with an energy-based device or laser, it adds value and reduces the downtime post procedure, and also reduces the number of sessions to achieve results.

11:30 - 11:45

Role of Cryotherapy in Symptomatic Relief of Patients with Inflammatory Dermatoses

Nivvedhetha S. MD | Senior Resident

Inflammatory dermatoses constitute a major portion of dermatological diseases that need long term treatment regimen and follow-up. An estimated 20–25% of the population is affected by inflammatory skin dermatoses. Chronic inflammatory dermatoses usually persist for months to years and are often associated with changes in epidermal growth or dermal fibrosis. These diseases are usually a major cause of physical and psychological morbidity in the patients. Cryotherapy is a controlled and targeted destruct ion of diseased tissue by the application of cryogen to cause tissue necrosis by rapid freezing and thawing. When applied locally, it has been used in experimental treatments of inflammatory and substantially pruritic skin diseases such as psoriasis and prurigo nodularis. Cryosurgery continues to occupy a very important position in the therapeutic area of a dermatologist . The advantages of cryosurgery are that it is a very cheap and easy to perform outpatient procedure. In inflammatory dermatoses, it is capable of inducing normal re-epithelization following physical destruction of lesions via reverse Koebner phenomenon. In the present age, cryotherapy occupies a very important position because of its advantage of being a short and suture less procedure with minimal risk of infection. Even though cryotherapy has been approved as a treatment modality in certain inflammatory dermatoses, there are very few studies about their effectiveness, their role in reduction of symptoms and the extent to which they cause resolution of the lesions. This study delves deep to find out their efficacy in the treatment of inflammatory dermatoses.

The main objective of this study was to analyse the role of cryosurgery in reducing symptoms and disease morbidity in patients with inflammatory dermatoses. The study conducted was a randomized control trial. The participants were recruited after the initial assessment and diagnosis confirmation. Patients were classified into 2 groups. • Patients in Group 1 were given the standard topical therapy pertaining to their diagnosis. • Patients in Group 2 were treated with a combination of Cryotherapy along with standard therapy. Procedure : 1) After placing the patient in a comfortable position, the target site was adequately exposed. Surrounding area of the target site was shielded with a drape or Cryosurgery shield. 2) Sites such as eyes, nares and ears were protected with goggles, gauze or padding. 3)Analgesics were given 1-hour prior for patients with anxiety. 4) The cryogen was sprayed directly onto the lesion through an appropriately sized nozzle continued for the recommended freeze time. After this the lesion was allowed to thaw, to complete the freeze thaw cycle. Patients were repeatedly educated regarding the skin changes that may be observed following cryotherapy. Patients were advised to start topical therapy one day after the day of Cryotherapy session. Also, patient was advised to stop all the topic al medications one day prior to the next follow-up. Patient is asked to follow-up after an interval of 2 weeks from the previous cryotherapy session and the clinical improvement is analyzed by the following tools: a) Dermatology Life Quality Index – A questionnaire to assess the impact of skin disease on the quality of life of an affected person b) Serial Photographs of the lesion

DAY THREE THURSDAY

7th March 2024

CONFERENCE HALL 1

DERMATOLOGY SCIENCES & RESEARCH

in standardized positioning assessing the lesion during each follow-up c) Visual assessment by clinician Inclusion criteria: • Patients who have given consent for taking part in the study • Patients over 18 years of age | Localized psoriasis | Hypertrophic Lichen Planus | Lichen Simplex Chronicus | Prurigo nodularis | Chronic DLE | Nummular Eczema Exclusion criteria: • Patients who did not give consent • Patients with H/O cold sensitivity • Patients with cold urticaria / cryoglobulinemia • Patients with Raynaud ' s Phenomenon • Sensory loss at lesional site

11:45 - 12:00

New Concept of Comprehensive Antiaging Therapy

Safwan Aladwan MD | Consultant Dermatology and Venereology

Aging has been a fact of life ever since it was created. Human beings go through various phases of life from being child to youth to being adult with youth being the best part of life from health point of view. Anti-Aging medicine aims to maintain or achieve this irrespective of chronological age i.e. to stay healthy and biologically efficient. Anti-aging medicine is an evolving branch of medical science and applied medicine. It treats the underlying causes of aging and aims at alleviating any age related ailment. Its goal is to extend the healthy lifespan of humans having youthful characteristics.

The primary goal of any antiaging therapy is to achieve a smooth, tight, blemish-free translucent skin, with even plane topography and more highlight than shadows. This concept should be applied in medical practice to reach the final goal.

12:00 - 12:15

Oral Facial Digital Syndrome – A Case Report in An Indian Child

Sanjanaa Srinivasa MD | Post Graduate

Justification why this case / case series is valuable for knowledge generation: [Provide literature consisting of existing knowledge in this area with published sources / references and the gaps existing] Oro facial digital syndromes (OFDS) are a group of rare heterogenous genetic disorders. The first description of OFDS was given in 1941 by Mohr. Following this, Oro-facial-digital syndrome type I was first reported in 1954, by Papillon-League and Psaume. Gorlin & Pindborg coined the term 'Orodigitofacial dysostosis' in 1964. However in view of systemic involvement, OFDS is preferentially used. It has been phenotypically classified into 14 types and two additional unclassified variants have been proposed. OFDS type 1 is the most common type. They can be inherited in a X linked dominant, X linked recessive or autosomal dominant manner. In view of the wide clinical and molecular heterogeneity, a novel simplified classification was proposed, grouping OFDS into 3 main sub types, with several other anecdotal cases. OFDS type 1 is an inherited X linked dominant ciliopathy, lethal in males, with the implicated gene - CXORF5, found on the short arm of the X chromosome (Xp22.3-p22.2) coding for OFD I protein. The incidence of OFDS I is 1:50000 to 1:250 000 live births. The OFD I protein is localized to the basal body of the primary cilia. The pathogenesis and clinical features of OFDS are related to primary cilium dysfunction and lead to abnormal Hedgehog signal transduction, depressed planar cell polarity pathway, and errors in cell cycle control. Clinical features seen on OFDS type 1 include facial dysmorphism (64%, including epicanthus, facial asymmetry, widely spaced eyes, broad nasal bridge with flattened nasal tip, flat midfacial region), cleft palate and/or high arched palate (48%), cystic kidneys (29%, for those who had renal scans) and central nervous system (CNS)

DAY THREE THURSDAY

7th March 2024

CONFERENCE HALL 1

DERMATOLOGY SCIENCES & RESEARCH

involvement (48%, intellectual disability and/or CNS malformations). Cystic kidneys are specific for OFDS I The cutaneous manifestations seen include facial milia, and hair abnormalities like alopecia, and dry and brittle hair. These overlapping clinical findings can be seen in the other types of OFDS, with the X linked dominant inheritance and cystic kidneys being the key features to clinch the diagnosis of OFDS type I. Renal involvement can be present right from birth or develop later on in life.

We present a case report of a 3-month old female patient diagnosed with OFDS Type 1, a subtype of the syndrome, based on distinctive oral, facial and digital features. This case report underscores the importance of raising awareness among clinicians about this rare disorder to facilitate early intervention and appropriate genetic counselling for affected families. Further research is warranted to elucidate the underlying mechanisms of OFDS, expand the genotypic and phenotypic library and to explore potential therapeutic interventions to mitigate the associated challenges and improve patient outcomes.

12:15 - 12:30

Dermoscopic Characteristics of Clinical Variants of Porokeratosis

Fida Anjum MD | Resident Dermatologist

Porokeratosis is a rare, acquired or inherited disorder of keratinisation. It presents as a keratotic papule or plaque with an annular appearance due to its thread-like elevated border that expands centrifugally. We report a case series of porokeratosis confirmed by dermoscopy.

Abstract Summary

Case series: We report four different clinical variants of porokeratosis confirmed by dermoscopy. Case 1: 29 Y/F presented with itchy lesions over the face for 5 years. On examination two irregularly shaped erythematous plaques on either side of nose with areas of hyperpigmentation and hypopigmentation with elevated border was present. Case 2: 23 Y/M presented with lesions with burning sensation over the nose for 2 months. On examination discrete erthymatous papules distributed over left side of nose with raised keratotic border was present. Case 3: 42 Y/F presented with asymmptomatic skin lesion over face since 6 month.On examination multiple hyperpigmented macules with hyperkeratotic borders was present. Case 4: 20 Y/F presented with asymptomatic lesions over both palms and soles since 3months. On examination multiple hyperkeratotic papules was present over the creases both palms and soles were present. Diagnosis was confirmed by dermoscopy, which showed double marginated white track border, follicular plugging,whitish and brown coloured dots and globules confirming porokeratosis. Discussion: Porokeratosis is relatively uncommon and may show atypical presentation making the diagnosis difficult. The cases mentioned above had diagnostic dilemma and dermoscopy aided in confirming the diagnosis. Conclusion: Porokeratosis has unique morphological presentation and it is essential to be familiar with its clinical and dermoscopic presentation. Dermatoscopy plays an important role in the differentiating it from other dermatoses.

DAY THREE THURSDAY

7th March 2024

CONFERENCE HALL 1

DERMATOLOGY SCIENCES & RESEARCH

12:30 - 12:45

Infantile Pustular Psoriasis: A Red Flag to Underlying Autoinflammatory Syndromes

Abeer Elkholy MD | Professor of Dermatology

Generalized pustular psoriasis (GPP) is a unique and rare type of psoriasis, characterized by red patches, desquamation, and sterile pustules, correlated with hyperpyrexia and systemic inflammation. Infantile pustular psoriasis (IPP) is extremely rare and considered to account for 3.5%–16% of childhood psoriasis and roughly 0.6% of total pustular psoriasis The autoinflammatory diseases are a group of monogenic diseases characterized largely by inborn errors of the innate immune system that lead to exaggerated, antigen-independent, inflammatory responses.

The main triggering factors for Generalized pustular psoriasis (GPP) include infections, drugs, pregnancy, and sudden withdrawal of glucocorticoids. Recent research findings have uncovered the key role of genetic mutations (genes IL36RN, CARD14, and AP1S1) in GPP. Based on consensus opinions of global experts published between 2017 and 2019, GPP associated with known genetic mutations fulfills the criteria for an autoinflammatory disease In most conditions, inflammatory markers, such as CRP, ESR, and S100 proteins, are elevated. Although these are non-specific findings, they may prompt further investigations towards autoinflammatory disorders, such as genetic analyses in early-onset and/or familial cases. Targeted inhibition of cytokines is effective in many of these disorders and has significantly improved the health-related quality of life of patients. Based on a better pathomechanistic understanding, novel small molecules (e.g., inflammasome inhibitors) are currently being developed and may enable even more precise therapies.

12:45 - 13:00

Recalcitrant Dermatophytosis: Focused and Firm Therapy with Novel Topical Formulation

Usman Shahid MD | Resident Physician

Dermatophytosis are the most common fungal infections seen in our third world country. Currently, chronic and stubborn cases are often seen mostly because of misuse of topical steroids, noncompliance, and possibly also because of increasing development of resistance to routinely used antifungal drugs. Skin is easily accessible to the direct application of antifungal remedies and topical use of antifungal chemicals to which development of microbiological resistant is less likely seems promising option.

Objective: We evaluated the efficacy of a novel topical preparation (inspired from Whitfield's ointment and Castellani's Paint formulations) along with oral Terbinafine in steroid modified and/or recalcitrant cases of Dermatophytosis. We name this unique blend of chemicals with antifungal, antiseptic and anti-inflammatory properties as Haroon-Hassan (HH) ointment in recognition of outstanding contributions made by legendary academicians late Drs. T S Haroon and Manzoor Ul Hassan in uplifting standards and practices of dermatology in Pakistan. Patients and Methods: Forty adult patients of recalcitrant tinea with Dermatophytoses Severity Score (DSS) of more than 10 were enrolled from our private clinic. Individuals with concomitant medical ailment/treatment were excluded. Oral Terbinafine (250mg) once a day was given for one month and especially formulated/dispensed topical ointment consisting of Benzoic acid (10%), Zinc oxide (10%), Resorcinol (5%), Sulphur (3%), Lignocaine (3%), Clotrimazole (2%), Salicylic acid (1.5%), Boric acid (1%), Phenol (1%), Menthol (0.25%), and Dimethyl sulfoxide (10%) in white soft paraffin was advised 2-3 times per day for 2.5 months. Results: Thirty-one patients completed the clinical trial and 25 (80%) were completely cured clinically along with negative KOH examination at 3-month follow-up. Four patients were still having DSS of 5, 7, 4, and 3 respectively

DAY THREE THURSDAY

7th March 2024

CONFERENCE HALL 1

DERMATOLOGY SCIENCES & RESEARCH

at three months while two patients relapsed after initial clinical clearance (possibility of reinfection). Conclusion: Topical application of cocktail of economical substances with reasonably good antifungal activity and less risk of developing microbiological resistant is good choice in resource-poor communities like ours. These broad-spectrum chemicals with antiseptic and soothing properties also take care of associated skin inflammation, pruritis and secondary bacterial infections not uncommonly seen in our low socio-economic class patients.

13:00 - 14:00 **Q & A / Lunch Break**

Session 10

Chairperson: Fatma Almadani MD, Hala AlJaber MD

14:00 - 14:15

Efficacy and Safety of Sertaconazole in Patients with Cutaneous Dermatophytosis

Ayesha Abrar MD | Resident Dermatology

Dermatophytosis is a superficial fungal infection of the hair, nails, or skin caused by the dermatophytes Trichophyton spp., Microsporum spp., and Epidermophyton. This has been a common global problem for decades. The global prevalence of superficial mycotic infections shows that 20-25% of the world's population has been affected in the last few decades. Dermatophytes are mostly found in humid parts of skin, on the surfaces of ground and on household items such as towels, bed sheets and clothing. Factors like age, gender, personal hygiene, socioeconomic conditions have also contributed to the emergence of these infections.Dermatophytoses is commonly called as tinea. Most commonly encountered verities of tinea are tinea cruris (affects inguinal region) and tinea corporis (affects trunk and limbs). Mostly, it is caused by Trichophyton species that digest keratin in the cells of the stratum corneum. Tinea corporis presents as radially advancing, flat, scaly, pruritic macules with a raised border and a characteristic central clearing which earns the sobriquet 'ringworm' for these lesions. Tinea cruris begins in the inguinal folds and presents usually as bilateral, scaly, dull red, pruritic plaques whose leading edge advances in a sharply demarcated, raised, scaly border. Treatment of dermatophytosis consists of oral or topical antifungal drugs or a combination of both which depends on the severity, site and extent of infection. The diffferent classes of topical antifungal drugs for dermatophytosis include the polyenes, the azoles, and the allylamine/benzylamines. Topical antifungals are considered as the first-line therapy for superficial dermatomycoses because of their efficacy and low potential for systemic adverse effects. These drugs are available in various formulations to facilitate penetration and to improve efficacy. The traditional azoles, such as clotrimazole, miconazole, and ketoconazole, which belong to the imidazole class of antifungals, are fungistatic and most commonly used. Newer topical antifungals may be more effective in these patients. Among the antifungal agents, sertaconazole (STZ) as the third-generation imidazole has a broad-spectrum against dermatophyte species, various yeasts, filamentous fungi, and even some bacteria. Sertaconazole is an imidazole antifungal that inhibits lanosterol 14 alfa demethylase, leading to disruption in ergosterol biosynthesis. Ergosterol is a major component of the fungal cell membrane and its deficiency is responsible for fungistatic and fungicidal properties of sertaconazole. Efficacy of sertaconazole in terms of cure was noted in 67.9% patients and safety was observed in 96.3% patients of dermatophytoses. Dermatophytoses is becoming a common problem now a day. At present, there is paucity of clinical studies in Pakistan regarding the efficacy and safety of newer antifungal drugs like sertaconazole for treatment of tinea corporis as well as tinea cruris. Therefore, it seems worthy to conduct this study as it will help us in managing such a common skin problem much more effectively and safely in Pakistan.

The introduction outlines dermatophytosis, a common fungal infection affecting the skin, hair, and nails, with a global prevalence of 20-25%. It discusses the factors contributing to its emergence and highlights the common

DAY THREE THURSDAY

7th March 2024

CONFERENCE HALL 1

DERMATOLOGY SCIENCES & RESEARCH

forms known as tinea corporis and tinea cruris. Treatment typically involves topical or oral antifungal drugs, with a focus on newer agents like sertaconazole. The objective of the study is to determine the efficacy and safety of sertaconazole in treating dermatophytoses. Operational definitions are provided for dermatophytoses, efficacy (cure after 4 weeks of treatment), and safety (absence of adverse effects during treatment). The materials and methods section describes the study setting, design, duration, sample size calculation, sampling technique, and selection criteria. Data collection procedures involve enrolling eligible patients, administering sertaconazole treatment, assessing signs and symptoms, monitoring safety, and conducting mycological assessments. Data analysis will use SPSS software, including calculating means, frequencies, and applying chi-square tests to compare efficacy and safety between groups. In summary, this study aims to evaluate the effectiveness and safety of sertaconazole in treating dermatophytoses among a sample of patients in Pakistan, addressing a gap in clinical research on this topic in the region.

14:15 - 14:30

Exosomes Derived from Adipose Tissue-derived Mesenchymal Stem Cells (Asce) for the Treatment of Dupilumab-related Facial Redness in Patients with Atopic Dermatitis: A Report of Two Cases

Byongseong Cho MD | CEO and CTO

Recent studies have reported promising results of mesenchymal stem cell therapies for skin aging. However, in the use of mesenchymal stem cells, some drawbacks including rarely possible tumorigenicity and immunogenicity, and low engraftment rates have limited their widespread clinical use. Exosomes are nano-sized (30 – 200 nm in diameter) lipid bilayered vesicles secreted by most cell types. Adipose stem cell exosomes (ASCEs) are emerging as effective cell-free therapeutic agents to treat a variety of skin aging. Atopic dermatitis (AD) is a chronic, pruritic, and inflammatory dermatosis affecting approximately 20% of children and 10% of adults worldwide. Dupilumab facial redness (DFR) is gaining attention as additional cases are coming to light in the medical literature.

Methods: Investigated whether topical application of adipose stem cell exosomes could reduce dupilumab facial redness in patients. Results: Two patients with atopic dermatitis and refractory dupilumab facial redness were successfully treated with electroporation-assisted topical application of adipose stem cell exosomes. Six repeated sessions of treatment, with an interval of 1 week between each session, led to marked improvement in erythematous facial lesions. Case 1: A 28-year-old man presented with erythematous maculopatches. The patient had previously started receiving subcutaneous dupilumab for severe AD, 4 months prior to the consultation. Prior to starting dupilumab, his Eczema Area Severity Index (EASI) score was 27.2, despite cyclosporine treatment. By week 4 of treatment, his EASI score had reduced to 21.8, and by week 16, it was 8.6. With the exception of facial redness, eczema on other parts of the body had greatly improved. He had undergone topical treatment with corticosteroids (one month), calcineurin inhibitors (one month), and antifungal agents (one month), with little improvement to his condition. He was diagnosed with DFR and treated with ASCEs after obtaining informed consent. He showed excellent improvement after receiving six repeated sessions of ASCE treatment twice a week. Since then, he has received ASCE treatment every two weeks for 3 months, and the improvement is well maintained. Dupilumab treatment is still ongoing, and his AD remains well under control. Conclusions: Adipose stem cell exosomes may serve as an effective agent to treat dupilumab facial redness.

DAY THREE THURSDAY

7th March 2024

CONFERENCE HALL 1

DERMATOLOGY SCIENCES & RESEARCH

14:30 - 14:45

A Study of Skin Aging and Skin Regeneration in an Ex Vivo Human Skin Model

Da Yeong Nam | Senior Research Engineer

The skin, being the largest organ of the human body, serves as the frontline in both the aging process and regeneration. Our research is grounded in an ex vivo human skin explant model, with a focused interest in skin aging and regeneration. Aging, as a complex phenomenon, can be categorized into two primary domains: 'intrinsic aging,' which follows a natural course over time, and 'photoaging,' a consequence of extended exposure to environmental stressors, particularly ultraviolet (UV) radiation. Diverse factors, including UV radiation, physical injuries, sodium lauryl sulfate (SLS), and tape stripping, can lead to skin damage. Within the scope of our research, we place particular emphasis on the effects of 'ultraviolet (UV)' radiation, aiming to elucidate the intricate dynamics of UV-induced aging, damage, and potential preventive strategies. Objectives: In a cosmetic industry era strictly opposed to animal testing, medical devices and pharmaceuticals still commonly resort to animal models. While animal skin shares some similarities with human skin, significant differences exist. What works for animals may not apply to humans. Ethical complexities surround direct human skin research, posing challenges. Over recent years, our dedicated team tackled these hurdles, advancing human skin understanding via ex vivo testing. We ethically collect post-surgical skin tissue after procedures like facelifts, abdominoplasties, and breast reconstructions, with IRB approval. Our primary focus pioneers innovative skin research using these tissues. We excel in UV-induced photoaging and skin damage recovery science. Our objective is to deepen skin health understanding and foster collaboration among skin researchers, sharing our findings widely. Materials and Methods: Our research is anchored in meticulous laboratory techniques. For our experiments, skin tissue samples encompassing a broad age range from 20 to 80 years old were carefully processed using an 8mm biopsy punch. In the UV models, skin tissue was systematically exposed to UVB irradiation under a range of carefully controlled conditions, followed by culture periods spanning from 2 to 5 days. Subsequently, we subjected the samples to comprehensive analyses, probing mRNA gene expression levels of critical factors such as COL1A1, MMP1, FLG, LOR, and cytokines. These assessments were further supplemented with detailed image analyses through histological evaluations. In the case of our skin regeneration models, our procedures involved the deliberate infliction of damage through controlled wound induction, exposure to sodium lauryl sulfate (SLS), and systematic tape stripping. Following the induction of damage, the skin tissue was carefully cultured for a specific duration, typically lasting 5 days. Subsequent analyses included the assessment of mRNA gene expression levels for factors like FLG, LOR, CLD, Ki67, and cytokines, coupled with comprehensive image analyses through rigorous histological evaluations. Results: Our research endeavors have yielded compelling outcomes. In our UV photodamage model, we observed a consistent pattern of decreased mRNA gene expression levels for COL1A1, FLG, LOR, and cytokines after UVB exposure. Conversely, the mRNA gene expression level of MMP1 showed a noticeable increase under the same conditions. However, a fascinating revelation emerged when we examined the mRNA expression patterns in the positive control group. This group, which had been cultured in a medium supplemented with 0.1% ascorbic acid post-UVB exposure, exhibited a robust trend of returning mRNA expression to normal levels. These findings hold significant promise for the development of potential anti-aging strategies. Furthermore, our detailed pathological evaluations, which employed MT staining to analyze collagen density and Fontana-Masson staining to measure melanin content, provided intriguing insights. In MT staining, we detected a notable reduction in collagen density following UV exposure. Strikingly, the positive control group displayed a remarkable increase in collagen density, suggesting the promising potential of specific interventions to counteract collagen loss. Fontana-Masson staining, which enabled us to evaluate melanin content, unveiled a noteworthy increase after UV exposure. In contrast, the positive control group demonstrated a remarkable reduction in melanin content, indicating the feasibility of strategies to mitigate melanin accumulation. In the context of our skin regeneration model, our investigations unveiled compelling dynamics. Specifically, we confirmed a consistent decrease in

DAY THREE THURSDAY

7th March 2024

CONFERENCE HALL 1

DERMATOLOGY SCIENCES & RESEARCH

mRNA gene expression levels for factors like FLG, LOR, CLD, Ki67, and cytokines following induced damage. Interestingly, this decrement was followed by a significant rebound in mRNA expression levels in the positive control group after damage, highlighting the potential for interventions to promote the recovery and regeneration of essential skin elements. Our extensive pathological evaluations, involving H&E and Ki67 staining to assess tissue regeneration and FLG and LOR staining to evaluate barrier factors, provided compelling visual evidence of these processes. Through H&E and Ki67 staining, we observed a remarkable restoration of damaged tissue in the positive control group, underscoring the regenerative potential of specific interventions. Furthermore, FLG and LOR staining revealed the substantial recovery and regeneration of crucial barrier factors in the positive control group, offering valuable insights into strategies to enhance skin barrier integrity. Conclusions: Through our rigorous and innovative research efforts, we have successfully established a robust UV photoaging model. In doing so, we have elucidated complex mRNA gene expression and protein expression patterns related to skin aging in response to UVB exposure. These findings not only deepen our understanding of the underlying mechanisms but also open promising avenues for the development of anti-aging strategies. In parallel, our investigations within the skin regeneration model have unveiled intriguing mRNA and protein expression changes associated with the repair and regeneration of skin barrier elements. These insights hold profound implications for advancing therapeutic approaches to enhance skin barrier integrity, thereby improving overall skin health. Our ultimate goal extends beyond scientific discovery; we are committed to developing an ex vivo platform that holds the potential to supplant traditional animal experiments. Just as clinical trials acknowledge the presence of inter-individual variations, our ex vivo skin explant models inherently encapsulate such diversity. As dedicated researchers, we are steadfast in our resolve to address these variabilities and generate precise data through a diverse array of models. Our mission transcends laboratory confines; we aspire to bridge the critical gap between ex vivo testing under blood flow-restricted conditions and clinical trials, fostering advancements in our understanding of skin health that ultimately benefit humanity.

14:45 - 15:00

Drug Patch Testing in Severe Cutaneous Adverse Drug Reactions

Dulini Liyanagama MD | Consultant Dermatologist

Cutaneous drug reactions are a frequent problem in clinical practice. Skin is affected in 25-30% of all adverse drug reactions. Different mechanisms may be involved in these reactions but delayed skin reactions are mostly due to immunological mechanisms. Systemic re-exposure can be extremely dangerous and is inadvisable for the Severe Cutaneous Drug Reactions (SCAR). Patch testing with the suspected compound has been reported to be helpful not only in determining the cause of the SCAR but also in studying the pathophysiological mechanisms involved.

In the Dermatology unit at National Hospital of Sri Lanka, we have patch tested 32 patients with SCAR . The patch-tested materials are prepared manually from commercially available drugs. Overall, the patch test positivity for the tested drugs in this study was 34.37% (11/32). In conclusion, drug patch testing is a useful tool to confirm drug imputability established on clinical grounds and safe procedure to perform. Positive patch test may confirm the drug imputability but the negative test does not exclude the responsibility of the reactions for the culprit drug.

DAY THREE THURSDAY

7th March 2024

CONFERENCE HALL 1

DERMATOLOGY SCIENCES & RESEARCH

15:00 - 15:15

Systemic Retinoids in Wart Treatment

Esraa Elhawary MD | Lecturer of Dermatology and Venereology

Warts constitute the most common cutaneous manifestations of human papillomavirus that infect epithelial tissues of the skin and mucous membranes. Most of the current therapeutic modalities depend on the ablation of warts. These include, among others, chemical cautery, electrocautery, cryotherapy, and laser therapy. This approach might be suitable for patients presenting with single or few lesions. In multiple warts, destructive procedures are inappropriate, impractical and might be associated with high rates of recurrence and significant adverse effects as pain, tissue destruction, infection, and scarring. In addition, they usually require multiple sessions and long recovery periods. This is particularly true in the case of warts on the palms, soles, and periungual area, and in the case of children who are highly resistant to the destructive approaches due to the associated pain and trauma. Management of multiple recalcitrant common warts represents a therapeutic challenge. Both oral isotretinoin and acitretin have shown promising efficacy in the treatment of various types of warts. In this lecture, we would like to present our work in the treatment of warts using systemic retinoids, namely acitretin, and isotretinoin.

Background: Management of multiple recalcitrant common warts represents a therapeutic challenge. Both oral isotretinoin and acitretin have shown promising efficacy in the treatment of various types of warts. However, a comparative study of the two medicines in wart treatment was not conducted prior to our work. Objective: The aim of this study was to assess the efficacy and adverse effects of oral isotretinoin versus acitretin in the treatment of multiple recalcitrant common warts. Methods: This study was conducted on 75 adult male patients with recalcitrant multiple common warts. The patients were randomly assigned to three groups: group 1 (30 patients) received oral isotretinoin, group 2 (30 patients) received acitretin, and group 3 received oral placebo (15 patients). The treatment was given daily until complete clearance or for a maximum of 3 months. Results: Complete clearance of the treated lesions was observed in 18 patients (60%) of the isotretinoin group, in 22 patients (73.3%) of the acitretin group, and in 0 patients (0%) of the placebo group. A statistically significant difference was observed in the therapeutic response between the treatment groups, and the placebo group was observed. Adverse effects of the used drugs were mild and transient. Conclusion: Oral isotretinoin and acitretin are promising effective modalities with minimal side effects for the treatment of male patients with multiple recalcitrant common warts with a relative superiority of acitretin.

15:15 - 15:30

Hyperpigmentation: Treatment Strategy in Asian Skin

Tatyana Vinnik MD | Assistant Professor & Chief Physician

A greater amount of melanin provides Asian skin with superior natural photoprotection against ultraviolet radiation, however, as a result, Asians show a greater tendency to have pigmentary disorders. Lentigines, ephelides, melasma, post-inflammatory hyperpigmentation (PIH), and nevus of Ota are the most common abnormalities in this group of patients. Melasma and PIH attract the most attention when managing due to the high recurrence rates, which significantly impact the quality of life.

The main therapeutic strategy includes inhibition of melanin synthesis pathways, anti-inflammatory treatment, and elimination of melanin excess. External treatment using tyrosinase blockers prescribed before and after exposure to laser and light-based technologies prevents active melanin synthesis in patients with different forms of hyperpigmentation. Oral tranexamic acid in the dosage of 250 mg 3 times per day during 3–4 months

DAY THREE THURSDAY

7th March 2024

CONFERENCE HALL 1

DERMATOLOGY SCIENCES & RESEARCH

in combination with antioxidant therapy shows more promise for the treatment of melasma. Restoration of the dermal matrix with injections of hyaluronic acid, platelet-rich plasma, and peptides is essential for stimulating neocollagenesis and reducing inflammation at all stages of treatment.

Non-ablative methods, represented by Intense Pulsed Light (IPL) exposure, Q-Switched 1064 nm Nd: YAG nanosecond laser, and non-ablative fractional Er: Yag 1565 nm laser and their combination in one session affect several chromophores of the skin and increase the effectiveness of the therapy. However, a lower fluency must be used with each device to prevent the development of PIH. The regimen of treatment sessions varies from 2 to 4 weeks depending on the type of exposure.

Although light and laser technologies are the pivotal methods of destroying and removing excess pigment from the dermis, etiopathogenetic treatment is mandatory to achieve lasting results and prevent complications and relapses. Combination therapy using external agents, laser and light-based technologies using non-ablative methods, as well as injection methods, and prescription of oral tranexamic acid and antioxidants can achieve more effective results far and above any monotherapy treatment approach in ethnic skin.

15:30 - 16:00 Q & A / Break

Session 11

Chairperson: Wedad Abdelrahman MD, Hani Sakla MD

16:00 - 16:15

Interleukin 9 in Oral Lichen Planus: An Immunohistochemical study before and after Treatment by Intralesional Steroid Injection

Mohamed ElGhareeb ElGanainy MD | Assistant Professor of Dermatology

OLP is a chronic inflammatory mucocutaneous disorder of oral mucosa. There are many types of OLP; reticular, papular, plaque-like, atrophic/erosive, ulcerative, and bullous types.CD8 positive T lymphocyte cause damage to the basal keratinocytes in OLP leading to apoptosis.It was found that IL23 and IL17 are expressed more in OLP suggesting a role of Th17 in pathogenesis of OLP.Keratinocyte apoptosis and basement membrane disruption are two main pathogenetic events occurring in OLP. MMP1,and MMP9 may play a role in these two pathogenetic event. Th9 secretes IL 9 which induces elevated levels of MMP9 to aggravate OLP disease severity .IL9 also increasesTh17 levels in OLP lesions.

Background: OLP is a chronic inflammatory mucocutaneous disorder of oral mucosa. There are many types of OLP; reticular, papular, plaque-like, atrophic/erosive, ulcerative, and bullous types.CD8 positive T lymphocyte cause damage to the basal keratinocytes in OLP leading to apoptosis.It was found that IL23 and IL17 are expressed more in OLP suggesting a role of Th17 in pathogenesis of OLP.Keratinocyte apoptosis and basement membrane disruption are two main pathogenetic events occurring in OLP. MMP1,and MMP9 may play a role in these two pathogenetic event. Th9 secretes IL 9 which induces elevated levels of MMP9 to aggravate OLP disease severity .IL9 also increasesTh17 levels in OLP lesions. Aim of the study: was to detect IL9 tissue expression in cases of OLP in comparison with normal subjects and correlate its expression with disease severity and response to therapy with intralesional steroid injection. Patients and Methods: This case-control study was conducted on 18 patients with OLP and 18 healthy volunteers with age and sex matched with patients group. REU scoring system was used for monitoring OLP lesions before and after treatment with treatment of patients with intralesional triamcinolone acetonide 20mg/ml every 2 weeks for 4 sessions. Biopsies for H&E and IL-9 expression were taken from patients and control.Biopsies were repeated from patients after the 4th session. Results:There was a highly statistically

DAY THREE THURSDAY

7th March 2024

CONFERENCE HALL 1

DERMATOLOGY SCIENCES & RESEARCH

significant increase in IL9 expression in patient group than in control group. A highly statistically significant decrease were noticed in REU score and IL-9 expression post treatment among patient group. Conclusion: IL-9 immunostaining is correlated to REU clinical score and also to H&E histopathological grading of OLP. we can conclude that IL9 is involved in pathogenesis of OLP.

16:15 - 16:30

The value of Real time PCR and High-Resolution Ultrasound in Diagnosis of Suspected Pure Neural Leprosy

Mohammad A. Rashed MD | Dermatologist

Background: Pure neural leprosy Cases (PNL) are difficult in their diagnosis and usually loss the early management opportunity.

Objective: to evaluate Real time PCR and High resolution ultrasonography of peripheral nerves as diagnostic tools in PNL.

Methodology The study included 25 suspected PNL and 25 healthy controls. All patients were subjected to ultrasonography cross-sectional area (CSA) measurement. Fine needle aspiration (FNA) was obtained, and followed by Ziehl-Neelsen (ZN) staining, and real time PCR.

Results: ZN staining demonstrated M leprae bacilli in only 8 cases while their DNA was detected in 92 % cases (Sensitivity of both were 100%, and 44.4%, respectively). CSA measurements showed good performance in distinguishing patients of PNL. Median nerve cut off=15.5 mm2, with a sensitivity of 72%), and right and left posterior tibial nerves CSA Cut Off were 12, 11.5 mm2 with sensitivity of 76-84%.

Conclusions: ultrasonography of suspected nerves and real time PCR of nerve aspirates are simple accurate tests for diagnosis of PNL.

16:30 - 16:45

Advancements in Nail Disease Management: A Multidisciplinary Approach

Faiez Ghanam MD | Dermatologist

Melanoma is a potentially dangerous skin tumor responsible for 90% of all skin cancer-related deaths. If diagnosed and treated early survival rate is very high (almost 99%). Dermatoscopy is a diagnostic method enabling the detection of morphological chaos even in early-stage melanomas, long before it becomes clinically evident. “Chaos and Clues” is a fast, 2-step, decision-making algorithm indicating biopsy in order to confirm or discard possible malignancy.

However, some challenging melanomas exist and might be easily overlooked, In order to avoid missing a melanoma, we present a series of challenging cases and peculiar clinical scenarios but also provide a set of 5 steps introduced to identify melanoma simulators, featureless, hidden, uncommon, and histologically ambiguous melanomas. When all the lesions look like a melanoma, do the comparative approach. When the lesion does not look like a melanoma, so-called featureless melanomas, start digital monitoring. When it is an uncommon variant of melanoma, apply the rules! When we don’t see the lesion, we must see it first to recognize it, do a thorough skin examination, and opportune screening, at least for high-risk patients. When the pathologist doesn’t recognize

DAY THREE THURSDAY

7th March 2024

CONFERENCE HALL 1

DERMATOLOGY SCIENCES & RESEARCH

it, always check the dermoscopy and pathology correlation! Implementing these 5 steps would help clinicians recognize even the most difficult-to-diagnose melanomas, avoid missing the deadliest skin cancer, and improve overall patient outcomes.

16:45 - 17:00

Henoch-Schönlein Purpura and Systemic Association in Children

Viola Elvia Sequeira MD | Post Graduate Resident

Henoch-Schönlein purpura (HSP), an IgA-mediated small vessel vasculitis, is the most common form of vasculitis in children which is commonly associated with systemic involvement of the gastrointestinal tract, joints and kidneys. Renal involvement is the main cause of morbidity and mortality in HSP.

Objectives: To characterize epidemiological, clinical characteristics and to correlate findings with systemic involvement in 40 children with HSP. Methods: Descriptive study of paediatric patients with HSP seen at our institution between 2021-2023. Results: Of the 40 paediatric patients identified, mean age of presentation was 6 years. 100% had rash in the form of non-thrombocytopenic palpable purpura either at presentation or during the disease course with rash distributed over the lower limbs and buttocks in 84%. Presence of lesions above the waist was significantly associated with gastrointestinal involvement such as abdominal pain, vomiting, frank GI bleed, and intussusception. Two patients had intestinal perforation. Renal involvement was found in 17 (42.5%) as microhaematuria and proteinuria (RBC and albumin-30%, RBC alone-12%), gastrointestinal tract involvement in 22 (65%) with abdominal pain and vomiting as dominant symptoms and joint involvement as arthritis in 10 (25%) with ankles being commonly affected. 3 patients had testicular swelling. Two patients had ophthalmic manifestations as retinal vasculitis and hypertensive retinopathy.

17:00 - 17:15

Blistering Rash in a Child

Wedad Abdelrahman MD | Consultant Dermatologist

A 5-year-old child was brought to the dermatology department with a 5-month history of a persistent pruritic blistering eruption affecting his legs and, to a lesser extent, the upper limbs and trunk. There was no mucosal involvement. Examination revealed a serpiginous annular rash on the legs bilaterally, with scattered bullae surrounded by areas of post inflammatory hyperpigmentation.

Histopathological examination of a blister revealed an intraepidermal split within the upper layers of the stratum spinosum, with acantholysis along the superficial epidermal roof as well as the epidermis along the base. Direct immunofluorescence confirmed intercellular deposition of IgG and C3 in the epithelium. Indirect immunofluorescence showed IgG antibodies on monkey oesophagus to a titre of 1/100, and on normal human skin, to a titre of 1/400. Pemphigus antigen enzyme-linked immunosorbent assay showed antidesmoglein 1 antibody titres of 91 U mL–1 and antidesmoglein 3 antibodies of 2 U mL–1, supporting a diagnosis of Pemphigus foliaceus (PF).

Two subtypes of PF exist: sporadic and endemic. The sporadic form typically affecting adults. The endemic form, which is found in areas of rural Brazil more commonly affects children. Clinical presentation varies, and can present as classical PF, with crusted plaques, erosions, vesicles, and bullae. Less commonly occurring and

DAY THREE THURSDAY

7th March 2024

CONFERENCE HALL 1

DERMATOLOGY SCIENCES & RESEARCH

considered unique to children, is presentation with serpiginous, annular or polycyclic eruptions; similar to that seen in this patient.

Children typically respond well to treatment, with corticosteroids, either topically or orally, as the mainline treatment, followed by other disease modifying agents. This patient was treated with 20 mg oral prednisolone alongside potent topical corticosteroids initially resulting in full clearance. During dose reduction of prednisolone, the child started to flare, and thus mycophenolate mofetil was initiated with good effect.

17:15 - 17:30

Skin, The Longevity Concept and Supplementation; Where Are We and Integrating into Holistic Practice

Jigna Patel MD | Aesthetic Clinician and Owner

As a community, we have largely focused on externally treating the signs and consequences of ageing and skin disorders rather than tacking the root cause. Over the years the role of supplementation has gathered momentum in supporting general health and wellbeing. A myriad of products are available that claim to improve skin health and age-related changes. Diet and lifestyle of course takes centre stage in providing the foundations for supporting internal and skin health and the explosion of interest into the impact of how we live our lives has resulted in raising the awareness of the harmful impact of internal and external environmental factors. The role of epigenetic programming through recent scientific advancements shows us that ageing is a modifiable process – accelerated ageing is well established but it can also be slowed and even reversed. This allows for a better understanding of our individual journey's and paves the way to a newer mindset, that of the longevity concept, to bolster our quest for living a healthier and longer life, inside and out. Optimising longevity requires the understanding of a number of concepts; the gut-skin-brain axis interweaved with influence from the endocrine and immune systems. After all… despite the skin being its own organ, we cannot think of it in isolation. Having a deeper understanding into "the fire within", that is the process of inflammation dysregulation helps to understand the impact on health and skin ageing. But it is the notion of balancing pro and anti-inflammation that helps us to address disease. Amongst the aesthetic community, the terms oxidative stress and maintaining redox balance are beginning to come to the forefront of our understanding of the underlying pathophysiology of skin conditions with much knowledge still to uncover. In addition, grasping the nine key cellular hallmarks of ageing illustrates that skin ageing is indeed a biologically complex phenomenon. Taking into the account the needs of those with genetic variations in components of the methylation pathway allows for practitioners to expand their horizons of catering supplementation services to a wider patient base and provides an opportunity to work collaboratively with experts in the Functional Medicine field. Supplementation takes on a new meaning when we look towards the implementation of ingredients and active, often extremely fragile molecules, centred around supporting cellular function and in turn, healthspan but for body and skin. What is required however is further exploration and awareness into product quality, the route of delivery, molecule size, molecule fragility and the bioavailability of supplements to provide optimisation of healthspan. We begin to look beyond relying on the healing and regenerative capabilities of current aesthetic procedures to help our patients feel and look biologically younger in addition to maximising treatment results.

The longevity concept looks at addressing critical changes that occur at a cellular level. Avid interest is building in the term 'biological ageing' – the decline in function of cellular processes that results in the ageing process, is a reflection of our true age and is associated with increased risk of developing almost every chronic disease. The aesthetic dermatological field focuses on diagnosing and treating a number of chronic skin conditions and in the last decade, the gut-skin-brain axis has emerged and reveals that despite the initial hypothesise that "all diseases begin in the gut", our digestive microbiome influences the development of skin inflammation and plays a vital

DAY THREE THURSDAY

7th March 2024

CONFERENCE HALL 1

DERMATOLOGY SCIENCES & RESEARCH

role in overall skin health more than we originally thought. We know that those who experience mental health disorders may relate these to the burden of persistent inflammatory skin conditions and it is known that psychiatric disorders can upset the gastrointestinal system via the release of neurotransmitters and cytokines by intestinal microbes. We can no longer simply attribute systemic inflammation and skin dysbiosis to the western diet. Furthermore, our understanding of inflammation dysregulation can in part be better understood by appreciating the need to maintain or restore redox balance. Under normal physiological conditions, reactive oxygen species (ROS) production is tightly controlled and participates in both pathogen defense and normal cellular metabolism like mitochondrial respiration. ROS overproduction, prolonged release or insufficient detoxification leads to oxidative stress resulting in cellular damage and has been linked to various inflammatory diseases. In healthy individuals the antioxidant defense system comprising of both enzymatic and nonenzymatic components act to maintain the oxidant/antioxidant balance and thus tissue homestasis. Chronic inflammation also sees these cytoprotective antioxidant defenses become depleted or overwhelmed thus skewing the redox balance towards prolonged oxidative stress. Restoration of the redox balance thus forms novel and exciting strategies for treating inflammatory skin conditions. Our attention turns to appreciating the nine hallmarks of accelerated ageing rather than the traditional acceptance of histological failures such as collagen and elastin loss and extracellular matrix breakdown. Mitochondrial dysfunction is directly linked to prolonged oxidative stress. UV-induced DNA damage leads to genomic instability which in turn triggers cellular senescence whereby cells enter a state of irreversible cell cycle arrest. Within ageing skin we see an accumulation of senescent keratinocytes and fibroblasts and whilst they remain metabolically active, they no longer produce elastin or collagen thus incapable of damage repair. Instead we see production of inflammatory factors such as matrix metalloproteinase-1 responsible for extracellular matrix degradation resulting in epidermal thinning. A cells option to proceed to senescence is also influenced by telomere attrition (the gradual loss of the protective caps at the end of our chromosomes). Features such as dermal stiffness and reduced flexibility occur as a result of the formation of advanced glycated end products. These along with defective proteins are usually removed by autophagy however ageing cells appear to lose efficient protein homeostasis thus adding to damage accumulation. Epigenetic alteration by way of changes to DNA methylation patterns leads to altered gene expression whereby favourable repair pathways are turned off whilst proinflammatory pathways are turned on propagating cells into an older state. Stem cell exhaustion, altered intercellular communication and dysregulated nutrient sensing interplay with the above and collectively elude to the cellular root causes applicable to many common skin conditions. Que the emergence of cellular health support. Many supplementation studies report misleading benefits as they often use molecules that have been compounded within a 24 hour period, remaining in perfect conditions before testing on subjects yielding 100% of the required dose. Premium quality supplements take into account potency of ingredient with it being listed high up in a minimal ingredient list, using active forms of ingredients, stabilising and protecting actives from light, heat and oxygen, efficient delivery technology that ensures absorption into the bloodstream and studies to support bioavailability and stability. Traditional oral supplementation provides limited therapeutic effects with around 30% absorption due to first pass metabolism. We know 100% absorption occurs via the IV route but delivers supraphysiological doses with a short-lived period of effect, requires the use of cannulation, is often expensive and not accessible to all. Novel sublingual Hinnao® Technology uses a proprietary process to reduce particle size of shear-sensitive molecules whilst uniformly encapsulating them within a phospholipid MCT base. The latter ensures high stability liposomes with no product fall out with stability and bioavailability reaching almost 90% (proven by Franz Cell Diffusion Study). We want to protect and preserve endogenous super antioxidant molecules like Glutathione with its myriad of benefits; a role in addressing hyperpigmentation, recycling and regeneration of other antioxidants, participation in P450 reactions, DNA synthesis and repair, amino acid transport, improving metabolic efficiency and more. Furthermore, the ratio of reduced to oxidised glutathione within cells is a measure of cellular oxidative stress. The average 45 year old has already experienced a 50% decline in Glutathione stores.

DAY THREE THURSDAY

7th March 2024

CONFERENCE HALL 1

DERMATOLOGY SCIENCES & RESEARCH

Studies show oral consumption provides poor bioavailability given that Glutathione is the substrate of proteases within the gastrointestinal system and due to the absence of a specific carrier at the level of the cell membrane. An essential coenzyme key to all hallmarks of ageing, nicotinamide adenine dinucleotide (NAD+) is vital for reactions regulating ATP production in the mitochondria, improving mitochondrial function, cellular adaptation to stress and DNA damage repair. In addition NAD+ is central for the sirtuin (SIRTs) enzymes involved in cellular repair and longevity. From the age of 20, cellular NAD+ levels reduce by 50% every 20 years. NAD+ is highly water-soluble, strongly absorbs UV light, in its white amorphous powder form is stable if stored in the dark yet decomposes rapidly in acidic or alkaline solutions. In the aesthetic realm, a variety of non-surgical procedures rely on cellular stress pathway activation to instigate collagen production and trigger the innate immune system to clear damaged cells. Adequate NAD+ levels are required for optimal pathway function therefore we now have the opportunity to further prime and assist our cells in recovery from procedures to optimise results.

DAY THREE THURSDAY

7th March 2024

CONFERENCE HALL 2

THERAPEUTICS/NEW DRUGS/CASE PRESENTATIONS

Session 10: Resident Dermatologists Competition - Part 4

Chairpersons: **Zbigniew Ruszczak MD** | Chairman, International Clinical Case & Poster Presentation & Competition
Shaden Abdelhadi MD | Co-Chairman, International Clinical Case & Poster Presentation and Competition
Mohammed El Banhawy MD | Senior Consultant Dermatologist

09:00 - 09:10

Butterfly Sign: Another Butterfly in Dermatology
Thaer Douri MD | Dermatologist and a Lecturer at the Faculty of Medicine

Dermatologists are familiar with the butterfly rush in systemic lupus erythematosus and rosacea, but other butterfly signs are not well-known in dermatology. The butterfly sign is a butterfly-shaped area observed on the upper central back, corresponding to the area that is difficult to reach by hand, in diseases with severe generalized pruritus such as primary biliary cirrhosis and atopic dermatitis. We have described 3 cases of butterfly signs in patients with chronic renal failure

The "butterfly sign" was first described in 1973 by Telfer Reynolds, MD, a hepatologist, in the Annals of Internal Medicine after he noticed a butterfly-shaped skin appearance on the back of a patient with primary biliary cirrhosis with generalized pruritus and hyperpigmentation. We have described 3 cases of butterfly signs in patients with chronic renal failure. In 3 cases there was a severe itching sparing over the upper central back. The first case had Kyrle disease. And chronic renal failure in the second and third. In the second the itching lead to diagnosis chronic renal failure .

09:10 - 09:20

Birt-hogg-dube Syndrome: A Rare Genodermatosis Treated with Exosomes
Elina Theodorakopoulou MD | Specialist in Dermatology

Birt-Hogg-Dubé Syndrome (BHD) is a rare genodermatosis, mainly characterized by mutations of the folliculin (FLCN) gene, which is located on chromosome 17. It is usually transmitted as an autosomal dominant variant and phenotypically presents as small benign hamartomas of the hair follicle (fibrofolliculomas), trichodiscomas, perifollicular fibromas, and acrochordons that most frequently appear on the face, neck, and upper trunk. The pathology may also present as spontaneous pneumothorax and is linked to increased risk for benign and malignant kidney tumors. Our aim was to treat uneven skin texture resulting from aging as well as past treatments of folliculofibromas, while potentially help skin with the genetic dysfunction of FLCN and hence overcome disease phenotype. FLCN mutations in BHD modulate the mTORC1 and AMPK pathways, which at the level of the skin, are important for the cellular homeostasis of fibroblasts. Interestingly, the secretion of the endogenous exosomes is negatively impacted from alterations in the mTORC1 pathway. On another note, mesenchymal and adipose tissue derived exosomes are able to improve wound healing rates via activation of the intracellular PI3K/Akt/mTOR pathway and hence improve the architecture of the dermis, by stimulating the production of healthy collagen and elastin from fibroblasts.] Taken together, we believe that by supplementing the skin of BHD patients with exosomes this may lead to a better wound healing rates and healthier collagen synthesis.

AIM: Birt-Hogg-Dubé Syndrome (BHD) is a rare genodermatosis, mainly characterized by mutations of the folliculin

DAY THREE THURSDAY

7th March 2024

CONFERENCE HALL 2

THERAPEUTICS/NEW DRUGS/CASE PRESENTATIONS

(FLCN) gene, which is located on chromosome 17. It is usually transmitted as an autosomal dominant variant and phenotypically presents as small benign hamartomas of the hair follicle (fibrofolliculomas), trichodiscomas, perifollicular fibromas, and acrochordons that most frequently appear on the face, neck, and upper trunk. The pathology may also present as spontaneous pneumothorax and is linked to increased risk for benign and malignant kidney tumors. Our aim was to treat uneven skin texture resulting from aging as well as past treatments of folliculofibromas, while potentially help skin with the genetic dysfunction of FLCN and hence overcome disease phenotype. FLCN mutations in BHD modulate the mTORC1 and AMPK pathways, which at the level of the skin, are important for the cellular homeostasis of fibroblasts. Interestingly, the secretion of the endogenous exosomes is negatively impacted from alterations in the mTORC1 pathway. On another note, mesenchymal and adipose tissue derived exosomes are able to improve wound healing rates via activation of the intracellular PI3K/Akt/mTOR pathway and hence improve the architecture of the dermis, by stimulating the production of healthy collagen and elastin from fibroblasts.] Taken together, we believe that by supplementing the skin of BHD patients with exosomes this may lead to a better wound healing rates and healthier collagen synthesis. METHODS: We present a 53-year-old female patient with BHD who was treated in the face and neck, with topical exosomes using a micro needling technique. The treatment protocol included a series of 3 treatments, 1 month apart. Using a micro needling device, the skin was treated with a total of 10 passes in each area (face and neck) in vertical, horizontal, and oblique directions, at a 0.5-1.0mm. Exosomes were applied topically during treatment as well as post treatment. RESULTS: Patient tolerated well the treatment and she was satisfied with the results. Results in the face were seen much quicker than the neck and decollate, perhaps due to the lack of pilosebaceous units which promote skin repair. CONCLUSIONS: We are the first to report the potential of aesthetic treatments to improve the BHD skin phenotype by using topical exosomes. This is a safe and well tolerate treatment which improved skin health as well as the psychosocial ability of this patient.

09:20 - 09:30

Scar Prevention with Exosomes after a Facial Dog Bite Lip Injury: Case Study

Shanthala Shivananjappa MD | Founder & CEO

Disfiguring scars on the face are known complications after animal bites/dog bite injuries. Early application of adjuvant topical exosome therapy on the primary wound area will expedite wound healing time, reduce the risk of early & hypertrophic scars minimize health care costs, and optimize the patient's quality of life.

Introduction: Exosomes are extracellular microvesicles enclosed by a lipid membrane 30-150nM which carry an abundant amount of growth factors and signaling mediators that enhance all 4 phases of wound healing and scar formation. Facial injury from dog bites may result in major tissue loss and is a frequent reason for ER visits. Every dog bite is unique and always contaminated, is challenging for surgical repair, and pose a high risk for aberrant scarring and disfigurement. Topical exosomes after primary wound closure is an adjuvant to achieving aesthetically pleasing scar. Materials/ Methods We report the case of a 49-year-old female who suffered from a serious dog bite on her lower lip. She went to the ER for debridement and primary wound closure and antibiotics. The patient was seen in the clinic 14 hrs later and the wound clot and debris were removed with hypochlorous spray. The MSC-derived exosomes of were topically delivered on the sutured wound using an insulin syringe for over 15 minutes. Daily evaluation of the wound site, signs of infection, pain, itching, and redness were noted by both the patient and the physician, and Photographs were taken. Results Exosome-assisted wound remodeling, rapid reepithelialization, and attenuation of inflammation result in less aberrant scarring, fibrosis, and almost perfect scarless wound. Our patient showed a significant improvement on Day 10 almost no scaring in 12 months.

DAY THREE THURSDAY

7th March 2024

CONFERENCE HALL 2

THERAPEUTICS/NEW DRUGS/CASE PRESENTATIONS

She has not had any side effects and did not need any scar revisions after 23 months. Conclusion Early application of topical exosomes on the primarily closed wounds after any animal bite-induced facial injury was noted to be safe with no side effects and potentially result in scarless wounds. The exosomes may add the benefit of a reduced rate for scar revisions, reduction of health care costs, and improved quality of life of patients with aesthetically pleasing scars.

09:30 - 09:40

My Clinical Practices and Experiences of Using AMT (Autologous Micrografting Technology) in Hair Restoration for both Male Pattern Hair Loss (MPHL) AGA and Female Pattern Hair Loss (FPHL)

Kelvin Chee Ling Tan MD | Medical Director

Androgenetic alopecia (AGA) or pattern hair loss (PHL) - Male and female hereditary hair loss - is the most common cause of hair loss, both in men and women. It affects approximately 80% of men and 50% women by the age of 50, and its prevalence increases with advancing age. As the name implies, AGA has a clear genetic predisposition mediating an excessive response to androgens - DHT. AGA is a disorder of multifactorial in origin, in which genetics plays an important role. In males, it is an androgen-dependent feature since the terminal follicles becomes susceptible to DHT, shortening the anagen phase ; whereas in women , the associated hormonal are less evident. In men, male pattern hair loss (MPHL) usually begins in the early twenties; a typical symptom is the receding hairline, which, slowly but surely moves higher and progress to central crown thinning. In women, androgenetic alopecia or female pattern hair loss (FPHL) usually begins with central hair line widening, progress to frontotemporal hair thinning or occipital hair thinning with the onset of menopause. It is important to find effective new treatments, which ensure better patient compliance and have limited side effects. Since AGA is characterized by defects in and loss of hair progenitor cells, while hair follicle stem cells (HFSCs) remain viable, transplantation of such progenitor cells has become a well-accepted treatment option. Autologous Micrografting Technology®, or AMT® is a method that obtains autologous mature hair progenitor cells from scalp punch biopsies of a patient using a preparation system for mechanical disintegration and filtering of solid tissues, the Rigenera® Technology (Regenera Activa Worldwide, S.L., Spain). The advocated mechanisms of action of AMT® in AGA include the enhancement of hair follicle regeneration by transplantation of progenitor cells, besides the reactivation of existing stem cells and progenitor cells of follicles in miniaturization; all by restoring hair growth signaling via the injection of cellular suspension solution .

Hair follicle autologous micrografting for Androgenetic Alopecia in both men (male pattern hair loss) and women (female pattern hair loss) is the next great promise in the regenerative approach to this condition. Autologous Micrografting is a one-surgical-time procedure that stands out for being fast, easy to perform, safe and effective. It consists of the extraction of autologous hair follicle micrografts that will be injected as a solution into the scalp of the patient in the same surgical time, with no harvesting or cell manipulation involved. To obtain viable tissue micrografts we used the innovative Rigenera® system (Regenera Activa Worldwide, S.L., Spain), which allows the disaggregation of small biopsies into micrografts of 70-80 microns suspended in a solution. This technology has been used for regenerative treatments in different fields, such as skin rejuvenation, wound healing, cartilage degeneration, and androgenetic alopecia. In the latter, these micrografts come from skin biopsies with healthy hair follicles, and contain progenitor cells (CD90+/CD105+/CD73+/Melanocyte progenitor cells, HFDMSC CD 44+, HFESC CD200+), extracellular matrix (ECM), and growth factors. When transferring micrografts to the wounded tissues, they will communicate with cells affected by disease. Through this signaling in which growth factors (TGF-beta 1, PDGF-AA, IGF-1, IGFBP- 6/3/2, EGF and bFGF), ECM components andprogenitor cells are

DAY THREE THURSDAY

7th March 2024

CONFERENCE HALL 2

THERAPEUTICS/NEW DRUGS/CASE PRESENTATIONS

involved, the cells in the wounded areas start to activate the regeneration process. These growth factors are known to activate Erk pathways, MARK pathways, EGF-receptor signaling pathways and some other cascades in inflammatory regulatory response. In Autologous Micrografting, micrografts are viable clusters of cells that secrete trophic and immunomodulatory factors through an extended period. All these components come from a tissue that is homologous to the recipient, and the signaling can be more specific than in PRP. Thus, the effects of the AMT® treatment encompass multiple targets of the hair follicle miniaturisation process. It helps increase ECM production, growth factors production, neo-angiogenesis, modulation of inflammation and tissue remodeling. This helps achieve a stop in hair loss, increase in hair thickness, and faster and better wound healing.

09:40 - 09:50

A Case of Bacillary Angiomatosis Successfully Treated With Doxycycline And Erythromycin - Ethiopia

Fuad Temam Awel MD | MD, dermatovenereology and dermatopathology

Cases of bacillary angiomatosis are rarely reported in africa, as to our knowledge there are only 7 cases reported in africa. [24-28]. This is a small number considering the high prevalence of HIV in most african countries including Ethiopia where the infection has a 4.4% prevalence [29]. In three of the cases reported from Africa, specifically east Africa there was a significant diagnostic challenge especially in differentiating the cases from Kaposi sarcoma. [25] This poses a question whether these cases are not commonly reported because they are not as common or they are actually underdiagnosed

We present a 27-year-old male patient who has been known to have human immunodeficiency virus infection for the past 2 years. He presented with neck mass of 8 months duration and erythematous ulcerating superficial as well as subcutaneous nodules on the skin. With these clinical and laboratory investigations, most importantly dermatopathologic evaluation the patient was diagnosed to have bacillary angiomatosis and started on doxycycline and erythromycin after he was followed for 4 years with significant improvement and relapse.

09:50 - 10:00

Ulcerative Colitis Flare Post Isotretinoin: A Case Report

Maha AlHussein | Senior Medical Student

Ulcerative colitis (UC) is a chronic idiopathic intestinal inflammatory disease that presents as abdominal pain, diarrhea, and hematochezia (1). It is considered a part of the inflammatory bowel disease together with Crohn's disease (1). The exact cause of ulcerative colitis is yet to be determined, but various mechanisms have been proposed; these include genetic susceptibility and immune dysregulation (2). Here, we report a case of ulcerative colitis flare induced by isotretinoin. CASE REPORT A 36-year-old male with a history of left-sided ulcerative colitis since eight years ago on mesalazine oral and suppository, which had been in remission for over two years, presented to our dermatology clinic complaining of around 20-year history of moderate-severe cystic acne. The patient previously was on topical treatments with no much improvement. Our patient was started on 20mg of isotretinoin capsule (Roaccutane) once daily after gastroenterology consultation as well as laboratory workup encompassing liver function test, lipid profile, and complete blood count to which they were within the normal range. After four months of oral isotretinoin course, he developed loose bowel motions (>7/day), with blood, yellow in color and nonwatery, no abdominal pain, no nausea or vomiting. Investigations were done to rule out the differentials,

DAY THREE THURSDAY

7th March 2024

CONFERENCE HALL 2

THERAPEUTICS/NEW DRUGS/CASE PRESENTATIONS

including a septic workup, stool calprotectin, stool clostridioides difficile toxin (CDT), stool chart, in and output chart, abdominal x-ray, and US KUB to which they were unremarkable. Colonoscopy revealed ulcerative pancolitis with a MyoScore of 2-3; histology showed ulcerative colitis in (figure1), extensive inflammation, crypt architectural distortion, crypt atrophy, and crypt loss. (figure2) Shows cryptitis and eosinophilic infiltrate in the lamina propria. Since he developed UC flare "pancolitis", isotretinoin was discontinued, he was started on Adalimumab "Humira" induction dose then 40mg SC once weekly and Azathioprine (50mg PO once daily) with good control. DISCUSSION Ulcerative colitis typically affects young adults, with a global prevalence projected to affect up to 30 million individuals by 2025 (3). The clinical course of ulcerative colitis varies from a stable course with prolonged remission to recurrent flare-ups, which is the return of symptoms after a period of remission (1). Reports have shown numerous factors of UC relapse, such as genetic susceptibility and fecal incontinence (2). On histology, A pathognomonic finding of UC is the presence of continuous colonic inflammation characterized by erythema, loss of normal vascular pattern, bleeding, and ulcerations. Here we report an UC flare following isotretinoin treatment, which is to our best knowledge, the first case report of UC exacerbation related to isotretinoin in Saudi Arabia. Isotretinoin is a retinoid derivative of vitamin A that works by inhibiting sebaceous gland activity with other anti-inflammatory and immunoregulatory properties (4). Dermatologists consider isotretinoin to have an adequate safety profile; it is primarily used to treat resistant nodular acne (4). Before using isotretinoin, patients should be aware of its most common adverse effects, including cheilitis and xerosis, and its teratogenicity effect (4). Laboratory monitoring is indicated for patients on isotretinoin therapy due to potential abnormalities such as decreased high-density lipoproteins (HDLs) or increased liver function tests (4). There have been several case reports of isotretinoin-inducing or exacerbating ulcerative colitis. Bharmal et al. reported that a 27-year-old female with no prior medical history developed severe active colitis with multiple superficial ulcers after a 16-week course of isotretinoin (5). Another 17-year-old boy was diagnosed with ulcerative colitis after an isotretinoin course; the patient required a subtotal colectomy and ileostomy five months after the first presenting symptom (6). A 2010 case-control study showed that Accutane is associated with a small risk of developing ulcerative colitis. Crockett et al. indicated that the risk of ulcerative colitis might be associated with higher dosages of Accutane (7). Another review article reported that isotretinoin might trigger the development of UC in individuals with high susceptibility to UC (8). How retinoids cause or induce an intestinal inflammation flare is not fully understood. However, it is postulated that it has some effect on T-cell function and adaptive immunity; although studies have been published on the association between isotretinoin and ulcerative colitis, it is still unclear if there is a causative relationship. Further studies are needed to confirm the effect of isotretinoin on the course of the disease (8).

10:00 - 10:10

Eight Cases with Distinctive Clinical Presentations

Ameer Mushtak MD | private clinic

Skin diseases might present with strange or unusual presentations that make diagnosis difficult. The objective is to report eight cases.

We conclude from this presentation that dermatology is a dynamic speciality and most of the times is evolving. Dermatologists should always expect to face strange and unusual cases which may be difficult to diagnose.

DAY THREE THURSDAY

7th March 2024

CONFERENCE HALL 2

THERAPEUTICS/NEW DRUGS/CASE PRESENTATIONS

10:10 - 10:20

Cowden Syndrome Patient with Unusual Gene Mutation and Lymphatic Malformation

Fatma Al Hosni MD | Specialist Dermatologist

Cowden syndrome CS is a rare genetic condition with an increased risk of tumor formation. Affected individuals are at a high risk of developing thyroid, breast, renal, colon, endometrial cancers, meningiomas, medulloblastomas, gliomas, melanoma, and benign growth. It is diagnosed based on clinical criteria and genetic testing. It is primarily caused by a germline mutation in the PTEN tumor suppression gene. We presented a 35-year-old female patient who met the clinical diagnostic criteria of Cowden syndrome CS but she had an APC gene mutation instead of the usual PTEN gene mutation, which had not been reported in the literature before. Also, she presented for evaluation of multiple non-pruritic, mildly tender nodules and papules on the left axilla and left nipple site. She noticed them after 6 months of completing radiotherapy post-lumpectomy for left breast cancer (ductal carcinoma in situ). A skin punch biopsy was obtained from the skin lesions in the chest. The histopathological report showed features of ectatic, thin, anastomosing vascular channels. There was no cytological or architectural atypia. The diagnosis was consistent with Lymphangioma circumscriptum. Lymphangioma circumscriptum is a disease that is seldom reported in the literature as related to the APC mutation, CS, and a side effect of radiotherapy.

Case Presentation: A 35-year-old female patient presented for evaluation for multiple non-pruritic, mildly tender nodules and papules on the left axilla, and left nipple site. She noticed them after 6 months of completing radiotherapy post-lumpectomy for left breast cancer (ductal carcinoma in situ). The patient had crowded teeth and cobblestone-appearing gums/tongue. She also had skin-colored flat-topped papules on the face, which clinically resembled facial tricholemomas. In addition, she had hyperkeratotic papules on the dorsal hands and feet, that mostly looked like punctate palmoplantar keratosis. From the age of 13, she started to develop tumors, including nodular colloid goiter, fibroadenoma of the right breast, angiolipoma in the left foot. Moreover, she had mature cystic teratoma of the left ovary, cyst adenoma of the right ovary, endometrial polyps, gastrointestinal polyps and liver hemangioma. A skin punch biopsy was obtained from the skin lesions in the chest. The histopathological report showed features of ectatic, thin, anastomosing vascular channels. There was no cytological or architectural atypia. The diagnosis was consistent with Lymphangioma circumscriptum. All lesions healed and left hyperpigmentation after a few sessions of cryotherapy. Cowden syndrome CS was suspected as a primary diagnosis. Therefore, a cancer panel genetic testing was done. It revealed an APC (Adenomatosis Polyposis Coli) gene mutation. Discussion: Cowden syndrome CS is a rare cancer and hamartomatous growths predisposition syndrome. It is commonly inherited in an autosomal dominant pattern. It is primarily caused by a germline mutation in the PTEN tumor suppression. The most recent revised clinical criteria for diagnosis of Cowden syndrome is the International Cowden Syndrome Consortium diagnostic criteria. Our patient was clinically diagnosed with CS. Unexpectedly, the APC gene mutation was verified by genetic testing. Due to the lack of prior reports linking CS to APC mutations, this raises the possibility that other genetic mutations, such as APC mutations, might be associated with CS. In general, affected individuals are at a high risk of developing thyroid, breast, renal, colon, endometrial cancers, and benign growth. On the other hand, Lipomas, fibromas, and epidermal cysts are also reported in patients with APC mutation. Some of these lesions are present in our patient. As a result, such findings cannot be attributed solely to CS but also to APC mutation. Our patient has typical lesions of lymphangioma circumscriptum (LC) which was proven by histopathological examination. Trauma, inflammation, infection, radiation therapy or surgery are associated with acquired lymphangioma. Radiation therapy causes fibrosis and lymphatic vessel obstruction which results in lymphatic fluid accumulation. Acquired lymphangioma after radiation therapy is distinguished by the late appearance of translucent vesicles in the irradiated location, as disease progression is insidious. Only a few cases of radiation therapy-induced lymphangiomas have been reported in the literature. There have been no previous reports of LC as a clinical manifestation of CS. Taking into consideration the rarity of both lymphangioma

DAY THREE THURSDAY

7th March 2024

CONFERENCE HALL 2

THERAPEUTICS/NEW DRUGS/CASE PRESENTATIONS

induced after radiation therapy as well as CS and the APC mutation, we postulate that LC could be one of the clinical manifestations of CS.

10:20 - 10:30

Epidermolysis Bullosa Dystrophica

Shafia Mudassir MD | Consultant Dermatologist

EBD is a rare group of inherited disorders that affect the skin fragility and cause blistering in response to even minor trauma. There has not yet novel treatments due to its rarity and extensive symptoms and more research is needed to set a global management approach. Clinical manifestations vary widely from localized to generalized blistering along with muscular dystrophy and skeletal abnormalities

The aim of this study was to evaluate the progression of a case study of 2 brothers ages 5 years and 10 years with epidermolysis bullosa dystrophica (EBD) presented with recurrent skin blisters all over the body since birth and disfigured atrophic scars and disabling musculoskeletal deformities with complete fusion of fingers and toes and abnormal gate. A rare case of EBD in 2 brothers with severe muscular skeletal complications, which are evaluated, treated during a relapse, and followed up.

10:30 - 11:00 **Q & A / Break**

Session 12: Case Presentation Open Category 2

Chairpersons:
Zbigniew Ruszczak MD | Chairman, International Clinical Case & Poster Presentation & Competition
Shaden Abdelhadi MD | Co-Chairman, International Clinical Case & Poster Presentation and Competition
Mohammed El Banhawy MD | Senior Consultant Dermatologist

11:00 - 11:10

Protocols of Injection of New Collagen for Skin Biostimulation

Chiara Stocco MD | Plastic Surgeon

Collagen-based skin biorivitalization has gained significant attention in recent years for its role in enhancing skin texture and rejuvenation. Various sources of collagen have been utilized, including bovine and fish collagen. However, allergic reactions have been reported in up to 3% of cases, limiting their widespread use. In contrast, an equine-based collagen derived from horse tendons, has been available in the market for the past 8 years with no reported allergic reactions. This study aims to evaluate the safety and efficacy of this equine-cased collagen injection for skin biorivitalization

Collagen-based skin biorivitalization has gained significant attention in recent years for its role in enhancing skin texture and rejuvenation. Various sources of collagen have been utilized, including bovine and fish collagen. However, allergic reactions have been reported in up to 3% of cases, limiting their widespread use. In contrast, an equine-based collagen derived from horse tendons, has been available in the market for the past 8 years with no reported allergic reactions. This study aims to evaluate the safety and efficacy of this equine-cased collagen

DAY THREE THURSDAY

7th March 2024

CONFERENCE HALL 2

THERAPEUTICS/NEW DRUGS/CASE PRESENTATIONS

injection for skin biorivitalization Patients and Methods: A total of 40 patients with post-acneic scars and face and neck skin laxity were enrolled in this study. The protocol was designed for 3 sessions of treatment done 2 weeks apart. The day of the treatment the skin was prepped in the usual sterile fashion. For each patient, depending on the area to treat, the injections points were identified: 20 injection points were identified for the cheek area, 10 for the forehead, 10 for the chin, and 20 for the neck. Each injection point received 0.02 ml of reconstituted Nithya collagen, with a spacing of 1 inch between injection points. The standardized injection protocol has been developed and refined over an 8-year span. Results: Initial findings indicate that equine-based collagen injections for skin biostimulation are well-tolerated by patients. None of the enrolled patients experienced allergic reactions, which have been a concern with other collagen sources. Common side effects, such as redness, prolonged papules, and swelling, were observed post-injection but resolved within the expected timeframe. Moreover, improvements in skin texture and rejuvenation were observed in a significant number of patients, suggesting the effectiveness of this type of collagen in achieving desired aesthetic outcomes. Conclusion: The use of an equine-based collagen, for skin biostimulation appears to be a promising and safe option. Unlike bovine and fish collagen, it has not shown any allergic reactions in our patient cohort. Proper adherence to the recommended injection protocol is crucial for minimizing side effects and maximizing the benefits of collagen injections. Further research and long-term follow-up studies are warranted to validate these preliminary findings and establish the equine-based collage as a reliable choice for skin rejuvenation and biostimulation.

11:10 - 11:20

The Use of Skin Microneedling for Melasma in Skin of Color

Gelila Teshome MD | Medical Doctor

Melasma is a common, acquired form of hyperpigmentation that affects people of all skin types, but is more prevalent in people with darker skin tones. It is characterized by the development of brown or grayish-brown patches on the face, typically on the forehead, cheeks, and nose. The patches are caused by an overproduction of melanin, the pigment that gives skin its color. The exact cause of melasma is unknown, but it is thought to be caused by a combination of factors, including sun exposure, hormonal changes, and genetics. There is no cure for melasma, but there are a number of treatments that can help to improve the appearance of the patches. One treatment option for melasma is microneedling. Microneedling is a minimally invasive procedure that involves using a small roller or pen with tiny needles to create micro-channels in the skin. This causes the body to produce collagen and elastin, which can help to lighten the appearance of melasma patches.

Case Description We present two cases of melasma (Fitzpatrick skin types IV-VI) that were successfully treated with microneedling and adjuvant therapy. Both patients were followed up for 2 months post-procedure, and showed successful outcomes with no recurrence. Results Both patients showed significant improvement in the appearance of their melasma patches after microneedling. The patches were lighter in color and less noticeable. There were no adverse side effects reported by either patient. Conclusion Microneedling is a safe and effective treatment option for melasma in skin of color. It is important to note that microneedling is not a cure for melasma, but it can help to improve the appearance of the patches. Patients should be aware that microneedling can cause some side effects, such as redness, swelling, and bruising. This case presentation may serve as a basis for future studies on the efficacy of microneedling for melasma in skin of color.

DAY THREE THURSDAY

7th March 2024

CONFERENCE HALL 2

THERAPEUTICS/NEW DRUGS/CASE PRESENTATIONS

11:20 - 11:30

Jellyfish Dermatitis Case Reported

Mohammed AlMalmi MD | Dermatologist physician specialist

30 years old Yemeni male patient went to swimming 5/7/2023 in red sea Alhudiadah port. He presented after that with severe itchy annular target iris skin lesions in his lower limbs and Neck and face with acute duration oncet. What are the differntial diagnosis? What is the possible specific diagnosis?

11:30 - 11:40

Case Report, Juvenile Hyaline Fibromatosis

Ronak Ahmed MD | Dermatology Specialist

Juvenile hyaline fibromatosis (JHF) is a rare genetic condition characterized by impaired collagen production or metabolism. This study aims to present a rare case of JHF. Case report: An 11-year-old boy presented with bilateral keloid-like lesions on his ears and admitted intermittent reappearance of such lesions since he was seven. He was born to second-degree relative consanguineous parents. Physical examination revealed bilateral soft pink masses on the ears, multiple scars on the scalp, severe gingival hypertrophy, multiple small soft white papules on the anterior neck, broadly shaped enlargements on the ends of the fingers and toes, and multiple reticulated hard livedoid and hyperpigmented macules on the back and anterior lower extremities. A 5 mm biopsy was taken from the lesion on the ear and histopathological examination of the specimen revealed a normal epidermis but dermal and subcutaneous deposits of nodules composed of abundant amorphous eosinophilic hyaline material with sparse embedded fibroblast associated with areas of congestion and focal hemorrhage. The ear lesions were managed by surgical excision with intraregional steroid injections to prevent relapse. To improve eating ability and oral hygiene, a gingivectomy was planned. Discussion: JHF presents with bone lesions, gingival hypertrophy, joint contractures, and skin lesions. The clinical features usually appear late in infancy and up to 5 years. The condition occurs mostly sporadically. A portion of the cases can be in siblings born to consanguineous parents. Conclusion: JHF is a rare genetic disorder that can present even beyond five years. There is no standard treatment for these cases.

11:40 - 11:50

Cicatricial Alopecia in Paediatric Population

Sanjana Mathew MD | Resident

Cicatricial alopecia represents a group of diseases characterized by a lack of follicular ostia and irreversible alopecia. It presents as areas of hair loss in which the underlying scalp is often scarred, sclerosed, or atrophic. Paediatric cases of cicatricial alopecia are rare, and thus more likely to be underreported. The frequent absence of symptoms may lead to a delay in diagnosis, resulting in the progressive scarring of the scalp and worsening alopecia. Early diagnosis is pivotal in controlling further disease progression and improving the quality of life of these children.

Seven children presented with scarring alopecia to the Department of Dermatology. Demographic characteristics was noted. A detailed history was taken and a thorough physical examination was done. Clinical photographs of the scalp were also taken at the time of presentation. Scalp biopsies were obtained for all seven patients. Patient

DAY THREE THURSDAY

7th March 2024

CONFERENCE HALL 2

THERAPEUTICS/NEW DRUGS/CASE PRESENTATIONS

ages ranged from 5 years to 12 years. They reported scalp symptoms such as itching, scaling and appreciable loss of hair on the scalp. None of them had a family history of cicatricial alopecia. Biopsy report of one child revealed a possible etiology of lichen planus pigmentosus or lupus erythematosus. The results were inconclusive in four cases and conclusive in two Since Cicatricial alopecia is not typically seen or suspected in paediatric population, it is likely to be underdiagnosed. The findings in these cases help document their possible underlying etiologies and encourage physicians to recognize early signs of cicatricial alopecia in children.

11:50 - 12:00

Palmoplantar Keratoderma: a Diagnostic Challenge

Ahmed Fayad MD | specialist of dermatology and venereology

A 44-year-old male patient, with history of diabetes presented with long-lasting multiple warty keratotic papules confined to palms and soles, some of which showed a double border and depressed center after removal. Differential diagnosis included: warts, punctate porokeratosis, arsenic keraoses and punctate palmoplantar keratoderma. Histopathologic examination showed columns of orthohyperkeratosis, epidermal depression, elongated curved rete ridges and hypergranulosis. Final diagnosis after histopathological examination was punctate palmoplantar keratoderma (Buschke- Fisher- Brauer).

12:00 - 12:10

Immunoglobulin Therapy in Staphylococcal Scalded Skin Syndrome

Apeksha Shyamalie Dissanayake Perera MD | Acting Consultant Dermatologist

Staphylococcal scalded skin syndrome is an exfoliative dermatosis where classically entire body surface becomes tender and erythematous and the superficial epidermis strips off. It is a disease described in children. Adults are predisposed to the disease when they have Renal failure (ETs are usually eliminated through the kidneys), malignancy, immunosuppression and alcohol abuse.Although otherwise healthy individuals may also be affected. Staphylococcus aureus strains (from all phage groups) produce an exfoliative toxin (ETA, ETB) The initial infection could be trivial. Extensive and dramatic epidermal changes triggered by the ETs which target the cell adhesion protein desmoglein 1 (DG1). Bullous impetigo, the ETs remain local in the infected skin but in SSSS the ETs are spread hematogenous, resulting in widespread skin involvement. Unlike in children SSSS in adults could lead to death. It is important to differentiate SSSS from Toxic Epidermal Necrolysis (TEN) or milder Drug reactions. Management of these two entities are completely different though the clinical appearance could be similar.Unlike in TEN in SSSS mucosal involvement is not severe, and in SSSS blisters are flaccid and there is more skin exfoliation. Colour of the Nikolsky sign could be used to differentiate TEN from SSSS as former has a darker erythema compared to SSSS.

History: A 34-year-old male patient referred to Dermatology unit with a generalized skin rash and fever for 2 days. He was a known patient with Diabetes and Chronic kidney Disease - stage 2. He was apparently well when he developed a cough 7days back and was started on Co- amoxiclav for past 3 days for community acquired pneumonia by his Physician. Since past two days his urine output has decreased and he has noticed a generalized skin rash. His general well-being deteriorated further for past two days.With these symptoms, he has consulted his Physician again and was started on prednisolone, suspecting a drug reaction to Co- amoxiclav. Despite steroids, his skin rash progressed and clinically deteriorated further. At this point, he was referred to Dermatology. Examination:

DAY THREE THURSDAY

7th March 2024

CONFERENCE HALL 2

THERAPEUTICS/NEW DRUGS/CASE PRESENTATIONS

he was conscious and rational. in sever distress.Refrained from movements completely due to skin tenderness. dehydrated. Skin involvement was evident more over the face compared to rest of the body. Working diagnosis at this point: Kawasaki like multisystem inflammatory syndrome associated with COVID 19. Staphylococcal scalded skin syndrome. A Drug reaction. Investigations: Inflammatory markers were elevated, ESR- of 80 mm/hr, ferritin -21 ng/mL, CRP- 95 mg/L, D-dimer- 58.7 µg/ml and procalcitonin -31ng/mL. FBS- 155mg/dl, HbA1C – 6.7% Troponin and BNP levels were in normal range. No abnormal findings detected in the ECG and 2D Echo cardiography. Treatment: His renal functions improved with rehydration. After consulting the Nephrology team, IV Vancomycin 1g bd. IV Immunoglobulin G 1g/kg dose divided over 3 days. Renal functions were monitored closely with adequate hydration. Discussion: Staphylococcal scalded skin syndrome is an exfoliative dermatosis where classically entire body surface becomes tender and erythematous and the superficial epidermis strips off. It is a disease described in children. Adults are predisposed to the disease when they have Renal failure (ETs are usually eliminated through the kidneys), malignancy, immunosuppression and alcohol abuse. Although otherwise healthy individuals may also be affected.

12:10 - 12:20

Unexpected Diagnosis of Facial Erythematous Papules

Ahmed Zidan MD | Dermatology and andrology specialist

45 years old female with asymptomatic erythematous skin lesion on face of 1 year duration Examination showed multiple erythematous painless papules and nodules on face and abdomen with psoriasiform lesion on lower abdomen Dermatopathology showed dense dermal nodular inflammatory infiltrate composed of lymph-plasmocytic aggregate with zones of pale histocytes emperiopolesis CD 3, CD20, CD68 & S100 positive. CD1a negative Final diagnosis Rosai Dorfman syndrome.

12:20 - 12:30

Unveiling the Misdiagnosis: A 22-Year Journey from Chronic Plaque Psoriasis to Pityriasis Rubra Pilaris - A Compelling Case Report

Chiranjaya Ekanayake MD | Registrar in dermatology

Chronic plaque psoriasis and adult-onset pityriasis rubra pilaris (PRP) are both dermatological conditions with overlapping clinical features, making their differentiation challenging. This case report describes a 61-year-old male patient who presented with generalized exfoliation of the skin, which had been previously diagnosed and treated as chronic plaque psoriasis for the past 22 years. The patient had received various topical and systemic therapies, including topical steroids, coal tar, keratolytic agents, methotrexate, and acitretin, with periods of disease exacerbation and remission. Upon examination, the patient exhibited erythroderma affecting more than 90% of the body surface area, with hyperpigmented hyperkeratotic plaques on the trunk and limbs. Palmoplantar keratoderma was mildly present, while arthritis and nail involvement were absent. Histopathological analysis of a skin biopsy revealed classical features of PRP, prompting a change in management including to address underlying malignancy and HIV. This case emphasizes the importance of routine histological examination in chronic skin disorders to ensure accurate diagnosis and appropriate management.

DAY THREE THURSDAY

7th March 2024

CONFERENCE HALL 2

THERAPEUTICS/NEW DRUGS/CASE PRESENTATIONS

12:30 - 12:40

CHILLS and WHEALS

Jaswandi Shirodkar MD | Resident Doctor

Cold Urticaria is a subtype of Physical urticarias under the umbrella of Chronic Inducible Urticarias. It is more common in nations with a cold climate with an incidence of 0.05%. It's often idiopathic, but may also be secondary to underlying conditions like infections, and autoimmune conditions. It is also classified as Typical and Atypical. Typical ones characteristically develop cold-induced wheals on rewarding which last for less than an hour. Common triggers include washing hands in cold water, swimming, low environmental temperatures and contact with cold objects and food. It is likely due to immunoglobulin E (IgE)-mediated mast cell activation on exposure to cold. Complications include angioedema, systemic involvement especially respiratory & cardiovascular system, anaphylaxis and mortality.

CASE HISTORY: A 17-year-old girl came to our OPD with complaints of swelling erythema and itching of her hands after washing utensils at her home since a few months which impaired her ability to do any other work till the lesions subsided. She had no history of respiratory distress, dizziness or swelling of eyes and lips. There was no history suggestive of previous infections. No significant past history. No family history of the same. No history of Urticaria occurring after any other triggers. No history of Atopy O/E: The patient did not have any wheals or hives at the time of presentation. Hence, we proceeded with an ice cube test which was positive. An ice cube was placed over her left forearm for exactly 2 minutes and 49 seconds when she developed itching over the site and at 4 min and 2 sec she developed a localised wheal over the exposed site. (pictures were taken with her permission). Diagnosis: Cold-induced Urticaria Treatment: She was counselled regarding the risk of angioedema and anaphylaxis. She was advised to avoid exposure to cold and wear rubber gloves for any housework involving cold water. Antihistamines and topical emollients were prescribed. Patient was asked to review back with reports of routine investigations. Conclusion: 1. Cold can cause wheals and even cardiorespiratory involvement with angioedema. 2. It may be associated with other types of urticaria eg. Cholinergic urticaria. 3. If the critical stimulation time threshold (CSTT) was less than 3 min there was a higher risk of severe systemic reactions after natural cold exposure. 4. More research is required to understand this condition and its treatment better.

12:40 - 12:50

Successful Use Of Colchicine In The Treatment Of Dissecting Cellulitis Of The Scalp - A Case Report

Amel Elsewh MD | onsultant Dermatologist

Dissecting Cellulitis of the scalp also called Perifolliculitis Capitis Abscendiens et Suffodiens; is a rare chronic progressive suppurative disease of the scalp. It manifests itself as perifollicular pustules, nodules, abscesses and sinuses that evolve into scarring alopecia. It predominantly occurs in young dark skin men between 20 and 40, although it may rarely occurs in women and children. It can occur in approximately one-third of patients with acne conglobate, hidradenitis suppurativa, a syndrome referred to as the follicular occlusion triad or tetrad if pilonidal cyst coexist. SAPHO syndrome (synovitis, acne, palmoplantar pustulosis, hyperostosis, osteitis), marginal keratitis and pyoderma vegetans have been reported to occur in association with dissecting cellulitis of the scalp. Dissecting cellulitis of the scalp is of unknown pathogenesis. It is believed to involve follicular blockage and as the material accumulates in the follicle, the follicle dilates and then ruptures. Keratin and bacteria can initiate a neutrophilic and granulomatous response. Early lesions characterized by acneiform distention of the follicular infundibula followed by the lower portion of terminal follicles which is the most affected part. On the basis of the

DAY THREE THURSDAY

7th March 2024

CONFERENCE HALL 2

THERAPEUTICS/NEW DRUGS/CASE PRESENTATIONS

fact that colchicine inhibits neutrophil motility and activity, leading to an anti-inflammatory effect. Colchicine was started and found particularly effective. Some follicles enter catagen/telogen phases of the hair cycle, which results in shedding of hair shafts without follicular destruction and that's probably explain the significant hair re-growth that occurs when prompt and effective treatment is initiated early. The treatment is often difficult. Medical therapies such as antibiotics and corticosteroid have been tried with no success. Isotretinion showed remission of the disease in a small number of cases. Destructive therapies such as surgical excision and skin grafting have also been tried with some success. Laser epilation such as 800 nm pulsed diode, long pulse Nd:YAG are considered an important treatment option in resistant cases. Recently, tumor necrosis factor-alpha blockers have been shown to be successful in the treatment of the condition.

A 31 year old man presented with multiple tender nodules associated with patches of alopecia on his scalp mainly on the vertex and occipital areas of the scalp. He had suffered from his scalp condition for one year. Topical and oral antibiotics had been given during that period with no improvement. Incision and drainage also had been done with no success as the nodules had returned. Culture of the lesions did not grow out organisms. The patient had no Acne Conglobata nor Hidradenitis Suppurativa. His blood chemistries were all normal. Biopsy was conclusive. It showed large perifollicular and superficial dermal abscesses composed of numerous neutrophils, lymphocytes and plasma cells. On the basis of the histopathological finding , Colchicine was started on 0.5mg three times per day. After one month of starting colchicine, flattening of the nodules were noted. By the completion of three months complete flattening of the nodules with regrowth of the majority of the hair was seen. The dose of colchicine was reduced and then a maintenance dose applied for few months with excellent result. As a general rule, early intervention with treatment is the best. If treatment is started early enough it is possible to reverse the disease before hair follicles become permanently damaged or destroyed. in conclusion: The treatment of Dissecting Cellulitis is often difficult. Despite this difficulty, and the very limited data on the use of Colchicine in the treatment of this condition. It seems that Colchicine is particularly promising.

12:50 - 13:00 **Q & A**

13:00 - 14:00 **Lunch Break**

Session 13: Case Presentation Open Category 3

Chairpersons:
Zbigniew Ruszczak MD | Chairman, International Clinical Case & Poster Presentation & Competition
Shaden Abdelhadi MD | Co-Chairman, International Clinical Case & Poster Presentation and Competition
Mohammed El Banhawy MD | Senior Consultant Dermatologist

14:00 - 14:10

Intralesional Triamcinolone Acetonide in Hidradenitis Suppurativa
Vani Veggalam MD | Senior Consultant Dermatologist

Hidradenitis suppurativa (HS), otherwise known as acne inversa, is a multifactorial, chronic inflamma-tory disorder of the hair follicles in intertriginous and anogenital regions of the body. HS is characterized by recurrent, deep-seated, painful, subcutaneous nodules, sinus tracts, and hypertrophic scarring. The hurley staging include

DAY THREE THURSDAY

7th March 2024

CONFERENCE HALL 2

THERAPEUTICS/NEW DRUGS/CASE PRESENTATIONS

STAGE I : (recurrent abscesses without scarring or sinus tract formation) , STAGE II: (recurrent abscesseswith scarring and sinus tract formation seperated by normal skin) STAGE III: (recurrent abscesses and interconnecting sinus tracts with minimal to no normal skin in between lesions) The long-term sequelae, including chronic pain, skin contractures, and disfigurement, can detrimentally impact activities of daily living, social functioning, and psychosocial well-being. Intralesional triamcinolone is a standard of care for acute inflammation and drainage associated with HS. We investigated the utility of high dose intralesional triamcinolone 40mg/ml for inflammatory lesions of HS.

METHODS: A case series of 3 patients (pregnant and lactating mothers) were included in the study. Patients with hurley stage II were included. Lesions including non-inflammatory nodules, inflammatory nodules, abscesses and fistulous tracts were infiltrated with inj. triamcinolone acetonide 40mg/ml .

RESULTS: Complete clearance of lesions was noted in 3 weeks duration. Atrophic scarring was noted with one patient over the injection site.

CONCLUSION: Intralesional corticosteroid showed effectivenss for the treatment of acute inflammatory lesions, fistulas, in terms of reduction of lesion counts, symptoms, and signs of inflammation. Clinical experience supported the use of intralesional coreticosteroid for individual lesions. Our results showed that intralesional corticosteroids are useful treatment to control in acute HS lesions.

14:10 - 14:20

Male Breast Cancer: Three Cases with Different Clinical Features

Mihoub Bourakba MD | Specialist Dermatology

The male breast cancer is a rare disease representing 0.4% to 1.2% of all male cancers. It is often discovered at a late stage despite its superficial seat. We report 3 cases of metastatic breast carcinoma revealed by cutaneous manifestations

3 men aged respectively 60,74 and 76 with no significant medical history, consulted for skin (plaques, nodules and ulcer) lesions on the trunk The duration of the disease ranged from 3-8 years.Thissymptomatology was associated with weight loss.. The clinical examination revealed: Case 1: Erythematous indurated plaque en cuirass with scales and crusts at the surface Case 2 Giant ulceration tumor of which the size attains 7X5 cm Case 3: two Erythematous indurated plaques with skin changes in the nipple-type retraction The results The Histology was in favor of infiltrating ductal carcinoma with skin metastasis. Hormone progesterone receptors and estrogen were positive. A staging revealed lung (3 cases) and bone (2 cases). Metastases. The patients were managed with courses of polychemotherapyand radiation therapy. Our cases showed that cutaneous manifestations are the main reason for consultation and reflected a late diagnosis and poor prognosis of breast carcinoma in humans. These cutaneous manifestations seem to be earlier in men than in women. This is usually a fixed and painless skin nodule essentially retroareolarseat. Other clinical signs suggestive are kind of nipple discharge or skin changes in the nipple-type retraction, ulceration or eczematisation. They can make a differential diagnosis with Paget's disease, Bowen's disease, basal cell carcinoma or melanoma. All histological types found in women are described in humans: invasive ductal carcinoma is the most common. Hormone progesterone receptors and estrogen are frequently positive than women with often higher rates. Surgery remains the basic salary. The aromatase inhibitors, anti-estrogen hormone therapy and / or chemotherapy are used as adjuvant treatments. The prognosis remains reserved given its unpredictable course and high metastatic potential Conclusion The high incidence of skin lesions in breast cancer in humans highlights the role of dermatologist in the diagnosis of this condition. At this

DAY THREE THURSDAY

7th March 2024

CONFERENCE HALL 2

THERAPEUTICS/NEW DRUGS/CASE PRESENTATIONS

point, the diagnosis is late and the prognosis is poor. Better information with awareness of the male population on the possibility of existence of such a condition in humans could improve the prognosis for early diagnosis.

14:20 - 14:30

A Complicated Case of Nasal Filler Injection

Natalia Imaeva MD | Dermatologist-Cosmetologist and Associate Professor

Use of dermal fillers for soft tissue augmentation has become an integral part of aesthetic practices. Dermal fillers temporarily remove the appearance of rhytids and reduce the depth of skin folds. Even with the most experienced of injectors, adverse effects can and do occur ranging from mild bruising to severe injection necrosis.

AIMS: Physicians should be able to treat the severe complication of vascular necrosis and detect impending necrosis after injection of a dermal filler, especially with hyaluronic acid fillers. MATERIALS AND METHODS: Case report of a patient 34 years old, in the history of which septoplasty 10 years ago, who were injected with hyaluronic acid in the region of the nasal dorsum, nasolabial folds and columella RESULTS: EARLY RECOGNITION OF COMPLICATIONS AND ADEQUATE TREATMENT LED TO COMPLETE TISSUE REPAIR. DISCUSSION: We review a case report of injection necrosis and methods used to prevent and treat this complication. CONCLUSION: It is necessary to develop a preparation protocol for patients with a history of operating rhinoplasty.

14:30 - 14:40

Is Erbium-YAG Laser Efficient to Treat Morbus Darier?

Qasim Abu Elrub MD | CEO, Medical Director and Dermatologist

Murbus Darier (keratosis follicularis) is a rare autosomal dominant genodermatosis, which is not easy to treat. One of the efffective ways to treat this disease is to use Ablative lasers (Erbium-Yaq or CO2). I need to present a case which I treated with Erbium-Yaq Laser.

14:40 - 15:30

International Clinical Poster Presentation and Competition - Poster Viewing Session Meet the Authors & Discuss with the Jurors

15:30 - 15:40 **Q & A / Break**

Session 14: JURY MEETINGS & AWARD CEREMONY

15:40 - 16:10

Jury Meeting - Digital Poster Award Discussion

DAY THREE THURSDAY

7th March 2024

CONFERENCE HALL 2

THERAPEUTICS/NEW DRUGS/CASE PRESENTATIONS

16:10 - 16:40

Jury Meeting - Clinical Case Presentation Award Discussion

16:40 - 16:55

Administrative Brake

16:55 - 17:35

Award Ceremony and Closing Remarks

DAY THREE THURSDAY

7th March 2024

CONFERENCE HALL 3

COSMETIC & SURGICAL DERMATOLOGY

Session 9

Chairperson: Khaled Gharib MD, Sameer Al Ali MD

08:30 - 08:45

The Use of Fractional Plasma for Periorbital Rejuvenation and Associated Combined Therapy

Stefan Lipp MD | Executive Director and CMO

Overview: The panorama of techniques for facial remodeling keeps growing between injections, cosmetics and EDB devices. Today, the needs of patients are focused on upper and lower eyelids where the techniques until now were quite limited. The use of fractional plasma is a safe and efficient way to treat those delicate areas.

Materials and Methods: We use a medical device generating fractionated plasma.

Procedure: We perform gentle dots with the device onto the skin to sublimate it by focusing only the epidermis. The treating area has to be numbed. Post treatment requires antibiotic and cortisone-based ointments and a sun protection.

For patient suffering from a strong ptosis and a severe skin laxity, the fractional plasma can be associated to injections of botulinum toxin and HA fillers to vectorize the results and consolidate the structure of the face.

Results: Patients are very satisfied with the protocol as you have effects on the excess of skin and on the quality of the skin as well through a neocollagenesis.

Conclusion: Fractional plasma is a safe way to rejuvenate periorbital area ad can be used for many benign lesions like skin tags, xanthelasma…

For the eyelid lift also named blefaroplasma, the selection of the patient is very important to have optimized results.

It is an attractive protocol for patients who are scared and not suitable for the surgery.

08:45 - 09:00

A New Combination of Wavelengths for the Treatment of Scars

Paolo Bonan MD | Professor of Dermatology

Scar treatment with 1540 nm and CO2 wavelengths takes advantage of the complementary characteristics of these two lasers. The 1540 nm wavelength is known for its ability to penetrate deep into the dermis, promoting collagen renewal and improving skin elasticity. On the other hand, the CO2 laser operates at a superficial level, allowing a controlled vaporization of the outermost layer of the epidermis, thus eliminating the superficial imperfections of the scar. The joint mechanisms of action of these two wavelengths include stimulation of collagen production, contraction of existing collagen, and removal of damaged epidermal cells. These processes work synergistically to improve the texture, color and flexibility of the scar, significantly reducing its visibility. Clinical research has demonstrated the effectiveness of this laser combination in treating a wide range of scars, including acne scars, hypertrophic and keloid scars, and surgical scars. Patients treated with this therapy have reported dramatic improvements in the texture and appearance of their scars, often with few or no complications. In terms of safety, it is essential to highlight the importance of the medical professional's competence in using these laser technologies. Safety considerations include ocular protection, an appropriate choice of laser settings based on the patient's scar type and complexion, and management of potential complications, such as erythema,

DAY THREE THURSDAY

7th March 2024

CONFERENCE HALL 3

COSMETIC & SURGICAL DERMATOLOGY

hyperpigmentation, or hypopigmentation. The future of the combined use of 1540 nm wavelengths and CO2 in the treatment of scars seems promising. Ongoing research aims to optimize laser settings, identify biomarkers for predicting outcomes, and explore new applications, such as treating scars in delicate areas of the body. Additionally, laser technology continues to evolve, with the potential for more compact and accessible devices for more and more patients. In conclusion, the synergistic use of 1540 nm and CO2 wavelengths represents an advanced and promising approach in the treatment of scars. This combination offers clinically significant results in improving scars, helping to improve the quality of life of affected patients. However, it is essential that doctors are adequately trained and competent in using this technology to ensure effective and safe results. Continuous research and technological innovation promise further progress in this constantly evolving field.

09:00 - 09:15

Uses of Dermoscopy in Laser Medicine

Karim Magdi Gabr MD | German Board-certified Dermatologist

The objective of this presentation is to test dermoscopy as a diagnostic and follow-up tool for patients receiving medicine in order to scientifically validate this method.

Dermoscopy has opened our minds to a new world. Studying of skin lesions in their microscopic features, either in normal conditions or in their pathologic variations in shape and color helps clinicians in initial evaluation of skin tumors, differentiating benign lesions from malignant ones. This leads to an earlier and more accurate diagnosis avoiding invasive examinations, such as biopsy. The assessment of submacroscopic structures could significantly optimize their use, in terms of evaluating the efficacy as well as the adverse events of the applied treatment. In our daily routine, dermoscopy can be tested as a tool for predicting laser and IPL treatment results. Taking advantage of its ability to visualize epidermal structure and superficial dermal structures a dermoscopic exam, performed immediately before and immediately after a laser session, shows whether the target has been reached and predict the type of clinical and aesthetic result obtained. From this point of view, dermoscopy a diagnostic tool to examine new lesions or to follow up on known lesions and becomes a tool to monitor the effectiveness of the aesthetic and curative treatments performed.

09:15 - 09:30

Photobooster for Vascular Disease

Sang Ju Lee MD | Director

Rosacea is a chronic dermatosis that is usually confined to the face. A pulsed dye laser (PDL) system has been proven to be effective in treating rosacea-associated erythema and telangiectasias. Niacin is a cutaneous vasodilator that can increase the chromophore through increased blood flow.

Materials / method: We hypothesized that increased blood flow by pretreatment with topical niacin could enhance the effect of PDL in the treatment of rosacea. Methods Eighteen Korean patients with rosacea were recruited. Three sessions of 585-nm PDL using a subpurpuragenic dose with and without pretreatment with niacin cream were performed on randomly assigned half-faces at 3-week intervals. Erythema was assessed objectively by a polarization colour imaging system, and evaluations were also made by three blinded dermatologists. Patient satisfaction was evaluated using a 10-point visual analogue scale.

DAY THREE THURSDAY

7th March 2024

CONFERENCE HALL 3

COSMETIC & SURGICAL DERMATOLOGY

Results: Fifteen patients completed this study. All patients showed an improvement in erythema after three sessions of PDL treatment both with and without niacin pretreatment. There was no significant difference in the improvement of objective erythema between the two sides. However, based on physician assessment the overall clinical improvement on the niacin side was significantly higher, and patient satisfaction was also higher on the niacin-pretreated side. There were no remarkable side-effects, with the exception of transient erythema and edema.

Conclusion: Pretreatment with topical niacin safely enhanced the effect of 585-nm PDL treatment of rosacea-associated erythema in Koreans. Application of niacin can be helpful in overcoming the relatively lower effect of subpurpuragenic PDL in dark-skinned Asians.

09:30 - 09:45

EBDs For Face Contouring

David Pudukadan MD | Professor

Cosmetic surgery has struggled to treat skin laxity minimally and noninvasively. Nonsurgical skin tightening, which retains the epidermis and requires minimal recovery time, has increased 600% in 15 years. Cryolipolysis, deoxycholic acid, lasers, chemical peels, and dermabrasion are nonsurgical methods for fat removal and skin resurfacing. These technologies cannot provide safe and effective skin tightening. Ablative and nonablative lasers have traditionally treated skin laxity without surgery by destroying the epidermis and dermis. Secondary skin tightening and dermal collagen remodelling occur. Lasers can resurface and remodel skin in selected individuals. However, the heat and energy needed to tighten dermal skin can damage the epidermis, causing burns and irreversible pigmentation changes. Lasers are only for lighter Fitzpatrick skin types.

High-frequency ultrasound can tighten skin without surgery using thermal energy. Ultherapy, which the FDA approved in 2009 for noninvasive eyebrow lifts, neck and submental lifts, and décolletage creases and wrinkles, is the most famous. Though results are modest, patients often complain about the procedure. Radiofrequency devices originally appeared in cosmetic medicine in the 2000s and have evolved. Nonablative radiofrequency (RF) treatments are best for avoiding recovery time. Aesthetic RF treatments are safe and require little recovery. According to questionnaires, submental cryolipolysis was well-tolerated, improved neck contour, and satisfied patients. Cryolipolysis for submental fat was FDA-approved after these findings. According to questionnaires, submental cryolipolysis was well-tolerated, improved neck contour, and satisfied patients. Cryolipolysis for submental fat was FDA-approved after these findings.

09:45 - 10:00

Picosecond Laser: Beyond Tattoo Removal

Achraf Ellouadghiri MD | Founder, Consultant and an Educator

Picosecond Laser (PL) was originally focused for optimizing the removal of challenging tattoos. However subsequent advances in this technology have broadned its clinical use to other conditions mainly tissue remodeling with scar revision and antiaging procedures and pigment reduction with various pigmentary disorders including melasma.

PL is claimed to have multiple advantages in a wide range of indications in both dermatological and aesthetic practice with minimal damage to surrouding tissues thanks to its ultra-short pulse width and the the principle

DAY THREE THURSDAY

7th March 2024

CONFERENCE HALL 3

COSMETIC & SURGICAL DERMATOLOGY

of laser-induced optical breakdown. The current data indicates that this technology is particularly promising in pigment reduction and tissue remodeling with few side effects and shorter downtime. Although case reports, case series and reviews have been published in the litterature, an updated focused examination on its effective use is lacking. In this study, we describe the use of PL in the management of various indications. In a serie of 38 cases of lip melanosis, we demonstrate the excellent safety and efficay profile of this technique. In a case serie of lichen planus pigmentosus, we demonstate, as in the litterature, the efficacy of this technology in the treatment of the pigmentary component of the disease. PL enables an effective and safe management of Ota nevus and similar pigmentation disorders with fewer side effects and less sessions in our clinical practice. In the management of residual pigmentation in extensive vitiligo, PL can be considered as a gold standard being safe and effective with few sessions needed. In the management of melasma, our results using the toning technique are mitigated compared to the litterature, showing mild to moderate results particularly in dark skin phototypes. The use of the fractional handpiece can improve the results but the number of sessions required is high (up to 12 sessions). In scar revision, PL can be an excellent alternative to fractional CO2 lasers especially in dark skin or when the pigmentation component is predominant. The combination of PL to other technologies as ablative lasers or vascular lasers is also interesting in order to manage different components of scars. We propose through various cases to illustrate the right target of PL in this indication. In aesthetic practice, our data supports that PL is a safe therapeutic approach and can achieve satisfactory results when ageing process includes photodamage and pigmentation. Standardized before and after photos are used to illustrate our purpose. Case Videos illustrating the practical techniques especially the toning and the sweeping technique used in rejuvenation and melasma are exposed. In our experience, PL is a “must do” technique especially in some indications like ota nevus, hori’s nevus, lichen planus, or lip whitening, a safe and effective alternative in the management of acne scars or rejuvenation, especially in dark skin phototypes or when minimal downtime is available. For other indications as melasma, its use obeys to a good selection of the patient and needs further investigations to elucidate the place of PL in their management.

10:00 - 10:15

At The Edge of Meso-toxin And Biorevitalisation: Combination of Botulinic Neuroprotein with Ha and Amino Acids in One Syringe:

Evgeniya Shelemba MD | Dermatologist

Background: Intradermal injections of highly diluted botulinic neuroprotein is a popular aesthetic medicine procedure to improve the texture of the skin, enlarged pores, and fine lines. Aims: to present a case report of nine subjects in whom the Jalu-toxin technique was performed. Patients/methods: Nine women in the 30- to 59-year-old range in a stable medical condition with moderate to severe lateral cantal wrinkles and smile lines at maximum expression and were recruited. The typical exclusion criteria for botulinum neurotoxin and hyaluronic acid injections were fulfilled. Results: No complications were observed. In all treated patients, there was clinical improvement in skin surface and texture, as well as attenuation of fine lines, with preserved natural facial mimetic activity. In two patients who were prone to rosacea, we noticed an improvement in erythema and flushing. Three patients with oily skin showed decreased oiliness and pore size. Conclusions: The Jalu-toxin technique is a safe and efficient method for skin quality enhancement. Keywords: botulinum toxins; micro-botox; meso-botox; intradermal botulinum toxin injection; amino acid replacement therapy; hyaluronic acid; extracellular matrix.

DAY THREE THURSDAY

7th March 2024

CONFERENCE HALL 3

COSMETIC & SURGICAL DERMATOLOGY

10:15 - 10:30

Skin Priming, A New Regenerative Concept, to Enhance Calcium Hydroxyapatite Skin Response Via Adding a Poly-revitalizing Complex: A Clinical, Ultrasound and Imaging Study

Elina Theodorakopoulou MD | Specialist in Dermatology

There is a gap in the literature regarding injectable, anti-aging treatments, with a mechanism of action that targets both nutrient deficiency of skin cells and ECM degradation, which are the primary drivers of skin aging. Skin priming is a new, regenerative concept, which consists of diluting CaHA with NCTF, at the optimal dilution for collagen production of 1:1, for subcutaneous injections, in the face. It is hypothesized by the authors of the study that skin priming with CaHA and a biorevitalizing mesotherapy cocktail will meet unobserved micronutrient deficiencies (often detected in aged or hypo/hypermetabolic patients) in tissues that may otherwise inhibit the most optimal response to ECM regeneration and dermal filler response. Contrawise, in otherwise healthy tissue, the authors hypothesized that skin priming may enhance the anti-aging effect of CaHA treatment by providing supraphysiological amounts of micronutrients vital for ECM regeneration and fibroblast activity. As explained earlier, amino acids are the elementary units for protein synthesis, while vitamins, coenzymes and antioxidants and minerals, included in NCTF, are essential as they support fundamental, cellular functions (Tardy et al, 2020). Skin priming directly supplements the skin with localized delivery of amino acids, vitamins, minerals and coenzymes, providing to otherwise micronutrient-deficient skin with the essential building blocks necessary for ECM protein synthesis and the requisite nutrients for vital metabolic pathways. Hence, skin priming may bring deficient patients to a normal amino acid and energy levels and healthy patients to a supraphysiological amino acid and energy levels, which would be ideal for protein synthesis and later tissue regeneration.

Introduction It is hypothesized that a combination of CaHA and NCTF® 135 HA may optimize or enhance the regenerative effect of aesthetic treatments. We propose a novel, skin regenerative concept, referred to as 'skin priming' and expressed with a novel injection technique, consisting of diluting CaHA with NCTF® 135 HA, at a 1:1 ratio, for subcutaneous injections in the face. Materials & Methods We compared clinical and photographic characteristics of 7 otherwise healthy, female patients, at baseline (V0), 3 weeks-(V1) and 6 weeks- post treatment (V2), (mean age=44.86 ± 5.46 years, mean BMI = 20.46 ± 1.83 k/m2). Patients were injected in the mid and lower face, using a 1:1 dilute mixture of CaHA: NCTF® 135 HA (3 ml of total mixture); 1.5ml of mixture was injected, with a 25G cannula, in each side of the face, subcutaneously. Skin and subcutaneous facial thickness at baseline, V1 and V2, were measured with facial ultrasound. A LED-UV booth was employed to detect differences in skin pigmentation. Skin luminosity of clinical photos was measured. Results All subjects were satisfied with the treatment and the most frequently reported AE (70%) was swelling and erythema at the injection site. There was a significant improvement of infraorbital hollowness ($x2(2) = 11$, $p = 0.004$, $W = 0.917$) and mid face volume ($x2(2) = 12$, $p = 0.002$, $W = 1.0$), compared to baseline. Similarly, we observed a significant improvement in the marionette lines ($x2(2) =11.57$, $p=0.003$, $W=0.964$), skin sagging and jawline contour ($x2(2) = 11$, $p = 0.004$, $W = 0.917$.) A mean wrinkle severity score of 3.33 was reduced to a mean score of 0.83 at V2; $x2 = -12$, $p < 0.0001$. Interestingly, skin luminosity significantly improved at V2 ($p < 0.05$). From ultrasound analysis, skin and subcutis thickness increased by 45.89% ± 29.60 and 42.56% ± 20.52, between baseline and V1, while 65.31% ± 42.29 and 71.53% ± 33.71%, between baseline and V2, respectively. There was a significant improvement in the red and yellow pigmentation of the LED-UV skinscope, which indicates an important improvement on skin quality, rosacea and oiliness. Conclusion To our knowledge, this is the first study to report the combination of CaHA and NCTF® 135 HA to accelerate and improve the skin regenerative response via an injectable nutritional priming mechanism. An overall phenotypic improvement of all patients was achieved. This is a safe and well-tolerated technique that was highly recommended by each patient. 397 words References [1] J. Varani, L. Schuger, M. K. Dame, C. Leonard, S. E. G. Fligiel, S. Kang, G. J. Fisher, J. J. Voorhees, J. Invest. Dermatol. 2004, 122, 1471. [2] S. E. G. Fligiel, J. Varani, S.

DAY THREE THURSDAY

7th March 2024

CONFERENCE HALL 3

COSMETIC & SURGICAL DERMATOLOGY

C. Datta, S. Kang, G. J. Fisher, J. J. Voorhees, J. Invest. Dermatol. 2003, 120, 842. [3] J. D. Tijerina, S. D. Morrison, I. T. Nolan, M. J. Parham, R. Nazerali, Aesthet. Surg. J. 2020, 40, 1253. [4] H. Mehta, A. Bishnoi, S. Dogra, CosmoDerma 2022, 2.. [5] M. Zarbafian, S. G. Fabi, S. Dayan, K. Goldie, Dermatol. Surg. 2022, 48, 101. [6] Y. A. Yutskovskaya, E. Alexandrovna, n.d., 8. [7] Y. Yutskovskaya, A. Sergeeva, E. Kogan, J. Drugs Dermatol. 2020, 19, 405. [8] N. Zerbinati, A. Calligaro, Clin. Cosmet. Investig. Dermatol. 2018, 11, 29. [9] N. González, D. J. Goldberg, Dermatol. Surg. 2019, 45, 547. [10] A. L. Berlin, M. Hussain, D. J. Goldberg, Dermatol. Surg. 2008, 34, S64. [11] Z. P. Lorenc, J. M. Black, J. S. Cheung, A. Chiu, R. Del Campo, A. J. Durkin, M. Graivier, J. B. Green, G. P. Kwok, K. Marcus, C. "Babis" Rammos, W. P. Werschler, Aesthet. Surg. J. 2021, 42, NP29. [12] A. T. de Almeida, V. Figueredo, A. L. G. da Cunha, G. Casabona, J. R. Costa de Faria, E. V. Alves, M. Sato, A. Branco, C. Guarnieri, E. Palermo, Plast. Reconstr. Surg. - Glob. Open 2019, 7, e2160. [13] S. Robin, F. Fanian, C. Courderot-Masuyer, M. Tordjman, F. Braccini, S. Boisnic, V. Philippon, A. G. Vincent, C. Salomon, M. Manfait, P. Humbert, P. Piccerelle, J. Cosmet. Dermatol. Sci. Appl. 2021, 11, 18. [14] M. Baspeyras, C. Rouvrais, L. Liégard, A. Delalleau, S. Letellier, I. Bacle, L. Courrech, P. Murat, V. Mengeaud, A.-M. Schmitt, Arch. Dermatol. Res. 2013, 305, 673. [15] A. Grand-Vincent, S. Boisnic, C. Salomon, P. Prinderre, P. Piccerelle, J. Cosmet. Dermatol. Sci. Appl. 2017, 7, 291. [16] G. Casabona, G. Pereira, Plast. Reconstr. Surg. Glob. Open 2017, 5, e1388.

10:30 - 10:45

Mesotherapy Cocktails: Ready Made Versus Mixing in Clinic

Philippe Hamida-Pisal MD | President of the Society of Mesotherapy of the United Kingdom

Are ready made biorevitalisation cocktails safer and more effective than cocktails mixed in clinics

Mesotherapy is a growing market due to increase request. More and more solutions are available. Are they more effective than the solutions we can mix in clinics?

10:45 - 11:00 **Q & A / Break**

Session 10

Chairperson: Yusra Al Ali MD, Mohammed Reda Mostafa MD

11:00 - 11:15

Dermal Boosters: How To Choose?

Ahmed Alqahtani MD | Assistant Professor

The global skin booster market is expected to secure $2.5 Billions this year based on reports from Acumen research and consulting, Factmr.com, Market Watch and KBV Research. With an average increase of 9.5% compound annual growth. This type of treatment has been gaining popularity year after year.

There are many options available in the market today but how to choose which is best for your patients? I have analyzed 2994 publications from 2014 to 2023 regarding Hyaluronic acid (HA) and skin rejuvenation. Many of these publications have indicated that injecting HA in the skin has improved texture, radiance, hydration and tightening of the skin. With that said, not all HA injections are the same and many based their products on Pseudo science and poor scientific justifications. I ran a study to test different brands of skin boosters and analyzed the outcome based on patients' feedback and visual analysis. I also invited other practitioners to participate and included their feedback in the study. The patient pool was 89 patients with 67 females and 22 males. The outcome of the study has showed that choosing the right product makes a big difference in the outcome. The saying "all

DAY THREE THURSDAY

7th March 2024

CONFERENCE HALL 3

COSMETIC & SURGICAL DERMATOLOGY

HAs been the same is not true". We also noticed, Patients satisfactions varies between treatments based on pain and comfort. We concluded that, choosing the right HA skin booster and approach is critical in patients' retention and satisfaction.

11:15 - 11:30

Hyaluronic Acid in Aesthetic Neurology: Opportunities and Prospects

Liudmila Soboleva MD | Dermatologist, Aesthetic Medicine Doctor

Based on ICD-10, cosmetology is more often considered as a specialty that corrects age-related changes and aesthetic deficiencies. Somatic diseases are often contraindications to aesthetic procedures. Often this is due not so much to the potential risk as to the lack of knowledge of doctors of other specialties about the possibilities of aesthetic medicine.

Facial nerve neuropathy in European countries occurs with a frequency of 20 cases per 100 thousand population and, in the absence of sufficient effect from treatment in the first six months, can cause severe external changes and often socialization problems. There are publications in the literature about increased lip muscle strength in patients with Bell's palsy as a result of the use of hyaluronic acid (HA) fillers. Based on these observations, in a clinical case of a patient with postoperative paralysis of the facial nerve, complex therapy was carried out, including botulinum therapy followed by the injection of injectable therapeutic drugs based on hyaluronic acid. The first stage of correction made it possible to reduce painful tension in the muscles of the lower third of the face on the healthy side.

11:30 - 11:45

Slim Face-what Is Better for Correction

Elena Belisheva MD | Dermatologist & CEO

The report reveals approaches to correcting a face with a deficiency of subcutaneous fat. which methods are preferable and which should be used with caution.

The following concepts will be covered -anatomical features of a thin and narrow face - comparison of the effects of botulinum therapy, filler injections, thread lifting and hardware correction methods - needle RF, HIFU.

11:45 - 12:00

PRP for Treatment of Androgenetic Alopecia: Which Clinical Effects Can We Expect and How Satisfied Are Male/Female Patients and Clinicians?

Hanno Pototschnig MD | Medical Doctor

Hair loss is a widespread condition in both genders. Over the past decade PRP has become a common treatment for hair loss. Our goal was to analyze patient and clinician satisfaction and to investigate all potential clinical effects of PRP on male and female pattern hair loss in a simple and practical way instead of counting the number of hairs per cm², which requires advanced technologies such as trichoscopic imaging and is usually not available daily practice.

DAY THREE THURSDAY

7th March 2024

CONFERENCE HALL 3

COSMETIC & SURGICAL DERMATOLOGY

Materials / method: Over a period of 12 months, we treated a total of 56 patients for androgenetic alopecia with PRP. 49 patients were treated with a series of three injections at monthly intervals, 3 patients with a series of four injections, 2 patients with a series of 5 injections, 1 patient was treated with a series of 7 injections, and 1 patient with a series of 8 injections. Follow-ups were conducted 1 month after the last treatment. Global photographs were taken and a self-drawn questionnaire was used to assess the satisfaction and clinical results from the patient's and the clinician's perspectives. Results: 32 patients were male and 24 females. The average patient satisfaction score was 7.29 (scale: 0-10). The clinician's rating was similar (6.46). The recommendation rate was high (8.0). Female patients' ratings were slightly but not significantly better. The probablity of occurence of clinical effects was reported as follows: improvement in hair density: patient 's rating: 64%; clinician's rating: 46%, thickness: 38%; 45%, quality: 46%; 54%, sheen/lustre: 27%; 21%, new hair growth: 57%; 68%, less hair loss: 48%; 20%, other positive effects: 5%, 2%, no effects: 4%; 4%, negative effects: 0%; 0%. Conclusion: Using a short questionnaire in daily practice is easy and may be also helpful to increase compliance and satisfaction. Our study revealed encouraging results for the treatment of male and female pattern hair loss with PRP. In 96% of all patients' positive clinical effects were found. The autologous treatment was rated with high satisfaction scores and can be considered a safe and effective treatment modality for both genders. As patient satisfaction scores are subjective to some extent, we added clinician satisfaction scores and found out that they were consistent with the patients' scores.

12:00 - 12:15

Side Effects and Complications of Fat Dissolving Injections: A Comprehensive Review and How to Prevent Them

Arturo Almeida MD | Medical Director & Global Trainer

Fat dissolving injections (FDI) have been used to dissolve unwanted, stubborn fat areas in the body since 1992 when Dr. Patricia Rittes, a Brazilian plastic surgeon, started to use them to dissolve the fat deposits of under eye bags. Most of these products are based on a naturally occurring substance called deoxycholic acid (DCA), a secondary bile acid found in the intestine which helps to emulsify fatty meals and facilitates the digestion of the fat. Multiple brands are available in the market today, but very few have sustained the test of the time, in terms of safety and efficacy. Some of them are combinations of DCA with phosphatidylcholine (PPC), resembling the original formula of Natterman which combines both components. Although overall safe, they are not exempt of potentially serious side effects, as it's the case for dermal fillers. There have been recent concerns about the safety of these FDI, in most cases due to a wrong election of the product, lack of knowledge of their mechanism of action, lack of proper training and/or wrong patient assessment and election. This lecture will give a comprehensive review of all the potentially serious side effects of fat dissolving injectables, the published literature on the side effects and how to treat them when occur. Also, A full guide on how to prevent them and how to select the best agent and patient will be provided, and a 7-point framework on how to successfully implement these treatments into an aesthetic practice. CONCLUSION: Fat Dissolving Injectables, although an overall safe treatment, may pose some potentially serious side effects, and they need to be acknowledged. The best way to prevent them is to use these FDI on the right patient, in the right body area and with the right technique.

DAY THREE THURSDAY

7th March 2024

CONFERENCE HALL 3

COSMETIC & SURGICAL DERMATOLOGY

12:15 - 12:30

Management of Delayed Skin Necrosis Following Hyaluronic Acid Filler Injection Using Pulsed Hyaluronidase

Ashish Chauhan MD | Founder, Director & Consultant

Facial fillers are minimally invasive aesthetic procedures performed for facial rejuvenation and contouring all over the world. Fillers even in the most experienced hands can lead to fatal complications such as vascular complications that need to be managed immediately with the help of hyaluronidase protocols mentioned in literature.Here we are presenting you a Case which is first ever documented in South East Asian countries Showing its uniqueness in symptoms. As with occlusion Symptoms (pain redness or hypo pigmented area where Ischimia occurs) Generally comes immediately or within few hours of occlusion but here patient was Asymptomatic for 48 hours.

In this case report, a patient was asymptomatic with no signs of vascular occlusion such as blanching or poor capillary refill for 48 h. He came after more than 48 h of the filler injection with complaints of pulsating pain in the right infraorbital and nasolabial area. We noticed necrosed microvesicles in the infraorbital artery territory with signs of impending skin necrosis extending from right infraorbital region up to the nasolabial fold (slightly medial to it). He was treated immediately with three pulsed doses of 500 units higher dilation of 10 ml every hour (reconstitution carried out using 3mL normal saline). The skin color improved with decreased pain, and the next day (after 14 hours) we injected 500 units of hyaluronidase in higher dilution of 10 mL as slight redness was still present. Skin redness, swelling, and pain disappeared the following day. Skin was completely healed and by 15 days we noticed slight post-inflammatory hyperpigmentation, which was easily managed with Q-switched laser and creams. We hereby report a case of delayed skin necrosis (>48 h) following filler injections in the cheek area, in the infraorbital artery vascular territory, which was successfully managed with pulsed dose of hyaluronidase.

12:30 - 12:45

A New Term in Aesthetic Medicine "The Dancing Chin"

Ibrahim El Achkar MD | ENT, Aesthetics and Plastic Surgeon

I'd like to present a new term that patients, physicians, dermatologists, aesthetic doctors and plastic surgeons should get to know: the "Dancing chin."

The term dancing chin" refers to an over-the-top movement of the three muscles in the chin (namely the mentalis, depressor labii inferior, and depressor annuli oris) and the primary neck muscle known as the platysma, which can occur both intentionally and involuntarily, such as in the case of a tic. The pathology is known on the skin as orange skin or golf ball. Dancing Chin is the phenomenon leading to the pathology.

12:45 - 14:00 Q & A / Lunch Break

DAY THREE THURSDAY

7th March 2024

CONFERENCE HALL 3

COSMETIC & SURGICAL DERMATOLOGY

Session 11

Chairperson: Omar Al Shaikh, Kamal Shakra MD

14:00 - 14:15

Nano Fat Injection for Periorbital Dark Pigmentation

Aasem Albytu MD | Head of Plastic and Reconstructive surgery

Dark pigmentation and skin laxity of lower eyelids attributed to many factors including thin ,translucent skin, prominent vasculatures and excessive melanin deposition which is difficult to treated; Tonnard's et al used nanofat graft by intradermal injection in lower eyelids which shows major benefits of nanofat injection is to related to stem cell activity ;in this clinical study we used nanofat injection in the lower eyelids as a treatment for dark pigmentation and skin rejuvenation, the aspirated fat was mechanically emulsified so fat fragments altered into liquid emulsion, and the color turned from yellow to whitish, then injected intradermally in the lower eyelids, all procedures performed in an outpatient clinic. Objectives: To evaluate clinically the benefit of using Nanofat injection for the treatment of skin rejuvenation and dark pigmentation of the lower eyelids with short term follow up. Patients and Methods: This prospective study conducted in the period of February 2022to November 2022included as an outpatient clinic procedure in Kirkuk province in Iraq. 22 female patients were recruited aged from 20 to 40 years, all were treated with intradermal Nano fat injection in the lower eyelids, and only 4 underwent lower eyelid blepharoplasty as they had excess skin in the lower eyelids. Results: All patients had nanofat injection for skin rejuvenation and deep dark pigmentation of the lower eyelids, Assessment of the results by the surgeon were good in 50%, fair 36.4 and poor 13.6; patient satisfaction was taken into consideration and almost more than half of the them expressed satisfaction (good result in 59.1% ,fair result in 31.8%). Only 2 patients (9.1%) had minimal postoperative complications. Conclusion: Nano fat injection may consider an affordable option as an outpatient procedure that can be performed with ease in clinics to relive deep dark pigmentation and skin rejuvenation of the lower eyelids.

14:15 - 14:30

Modern Concept of Rejuvenation Through Biomodulation

Roberto Amore MD | Professor of Dermatology

The modern concept of rejuvenation is based on the fact that the aging process involves different structures, levels and cell lines. Therefore, this procedure nowadays is addressed to different targets involving different molecules able to interfere and modify selectively their activity. The choice of these and an adequate planning tailored to the subject are essential for therapeutic success. Biomodulation is a wider concept compared to biostimulation: let's clarify.

DAY THREE THURSDAY

7th March 2024

CONFERENCE HALL 3

COSMETIC & SURGICAL DERMATOLOGY

14:30 - 14:45

MidMedial-Deep Volumisation Technique - Anatomical and Practical Apporoach to the MidFacial Harmonisation

Sabuhi ABILOV MD | Owner/Founder and Head Doctor

A Most Problematic Facial Deformities We Are Seeing on Mid Medial Face. Some Times We Are Calling This Phenomenon a Tired Face, Tear Through, Prolapsing of Orbitozygomatic Region. This Includes a Review of The Relevant Anatomy, As Well Intricacies Analysis, and Operative Approaches to The Region, As Well As Orthognathic, Periorbital, And Adjunctive Manipulations. Therefore, An Algorithmic Approach Is Required to Take Specific Volume-Loss, Soft Tissue And Facial Skeletal Characteristics Into Consideration.

MidMedial DEEP Volumisation Technique" - is good option for balancing of midface for all types deformities. This is technique also convenient for patiens with ortognatic problems on orbitozygomatico-maxillar region. The use of a "MidMedial DEEP Volumisation Technique" treatment algorithm may improve outcomes for patients seeking injectable treatments for midfacial volume loss and contour deficiencies.

14:45 - 15:00

How to Remove Your Permanent Filler

Ayoud TOUMI MD | Plastic Surgeon

Permanent fillers (PF) were used widely and became popular many years ago due to their long durability and low prices. However, due to, the development of many complications after injection, including fibrosis, abscesses, and tissue necrosis, forbid their use globally. After PF injection, a limited number of capsules with thin and soft walls containing the substance are formed. Nevertheless, wrong treatments using a needle to suck the filler, dissolving the filler by injection of cortisone inside the capsule, and removing the PF via face-lifting, end with a negative result for the filler and even spreads in tissues that did not contain filler previously which further complicates the situation.

How to Remove Your Permanent Filler Permanent fillers (PF) were used widely and became popular many years ago due to their long durability and low prices. However, due to, the development of many complications after injection, including fibrosis, abscesses, and tissue necrosis, forbid their use globally. After PF injection, a limited number of capsules with thin and soft walls containing the substance are formed. Nevertheless, wrong treatments using a needle to suck the filler, dissolving the filler by injection of cortisone inside the capsule, and removing the PF via face-lifting, end with a negative result for the filler and even spreads in tissues that did not contain filler previously which further complicates the situation. Based on my experience and in my opinion, the above-mentioned treatments were and still are used incorrectly, for removing the PF. Hence, my work aims to get rid of the permanent filler. The treatment and solution are to reach the capsule in the nearest possible way, and it is exclusively from inside the mouth, wherewith high experience the surgeon can open directly the capsule after distancing the vascular and nerve structures, then open the capsule and suck the PF via suction. After that, the PF is withdrawn directly to the outside to prevent any part of it from escaping to healthy tissue. Obviously, it is possible to reach the entire face from this incision to the temporal region, except for the forehead. After the material is fully removed, the patient will return to normal and any cosmetic applications can be performed later. A more practical workshop is still needed for training doctors to avoid any future mistakes, and more strict rules are needed to forbid the manufacturing and the use of PF.

DAY THREE THURSDAY

7th March 2024

CONFERENCE HALL 3

COSMETIC & SURGICAL DERMATOLOGY

15:00 - 15:15

Post-surgery Scars Success is Based on Strong Collaboration Between the Plastic Surgeon and The Dermatologist. Tips and Tricks to Achieve a Seamless Scar

Dora Evangelidou MD | Consultant Plastic and Reconstructive Surgeon

Post-surgery scars success is based on strong collaboration between the Plastic Surgeon and the Dermatologist. Tips and tricks to achieve a seamless scar. Background: Post-surgery scars can be a source of significant distress for patients. The success of scar management is based on a strong collaboration between the plastic surgeon and the dermatologist. Methods: A review of my personal experience was conducted to identify the factors that contribute to successful scar management. Results: The review found that a combination of approaches is often necessary to achieve optimal results. Topical medications, such as silicone gels and creams, can help to reduce inflammation and improve the appearance of scars. Laser therapy can be used to break up scar tissue and improve the texture of the skin. Surgical scar revision can be used to improve the appearance of scars that are particularly noticeable. Conclusions: The success of post-surgery scar management is based on a strong collaboration between the plastic surgeon and the dermatologist. By working together, these two specialists can develop a treatment plan that is tailored to the individual patient's needs. My personal algorithm for success is shared.

15:15 - 15:30

The New Face of Masculinity: Cosmetic Medicine for Men

Duaa Abdulmohsen Mohamed MD | Specialist Dermatologist

The traditional definition of masculinity is changing. Men are increasingly seeking cosmetic medicine treatments to improve their appearance and boost their self-confidence. This trend is being driven by a number of factors, including: • The increasing acceptance of cosmetic medicine among men • The availability of more advanced and effective cosmetic medicine procedures • The growing popularity of social media, which has placed a greater emphasis on physical appearance Cosmetic medicine can offer a number of benefits for men, including: • Improved self-confidence and self-esteem • A more youthful appearance • Increased attractiveness • Improved professional success • Enhanced quality of life Men who undergo cosmetic medicine procedures often report feeling more confident and positive about themselves. They may also find that they are more successful in their careers and personal lives. Additionally, cosmetic medicine procedures can help men to feel healthier and more comfortable in their own skin. Some of the most popular cosmetic medicine procedures for men include: • Botox and dermal fillers. These injectable treatments can be used to reduce the appearance of wrinkles and fine lines, add volume to the face, and improve facial contouring. • Laser skin resurfacing. This treatment can be used to improve the appearance of skin texture, reduce discoloration, and remove acne scars. • Body shaping devices • Microneedling • Hair loss treatments It is important for physicians to be aware of the unique safety considerations for men undergoing cosmetic medicine procedures. These include: • The potential for bleeding and bruising, which may be more pronounced in men due to their thicker skin. • The risk of infection, which is also higher in men due to their increased beard growth. • The possibility of scarring, which may be more noticeable in men due to their darker skin. • The difference while augmenting the face with dermal fillers It is also important to be aware of the psychological considerations for men undergoing cosmetic medicine procedures. Men may be more reluctant than women to seek treatment, and they may be more concerned about the potential risks and side effects. Men may also be more likely to experience anxiety and depression after undergoing cosmetic medicine procedures. Physicians should take the following steps when treating men seeking cosmetic medicine procedures: • Have a thorough understanding of the unique safety and psychological considerations for men. • Discuss the patient's

DAY THREE THURSDAY

7th March 2024

CONFERENCE HALL 3

COSMETIC & SURGICAL DERMATOLOGY

expectations and goals in detail. • Select the most appropriate procedure for the patient's individual needs. • Provide clear and concise instructions on how to care for the skin after the procedure. • Follow up with the patient regularly to monitor their progress and address any concerns.

15:30 - 15:45

Enhancing Facial Aesthetics: Combining VASER Liposuction and Renuvion for Double Chin Contouring

Maria Rubatti MD | Head of Plastic Surgery Department

The chin defib=nition is a very important area for females and males. Doing a combination with new technology we can achive amaizing results.

Double chin, a common aesthetic concern, is characterized by the accumulation of submental fat and loose skin beneath the chin. Traditional surgical procedures have been effective but are associated with downtime and potential risks. This abstract explores a minimally invasive approach to address double chin using VASER Liposuction and Renuvion, an innovative combination that offers remarkable results with reduced recovery time and fewer complications. VASER Liposuction employs ultrasound energy to gently and precisely liquefy submental fat, allowing for easier extraction and sculpting. This technique offers excellent fat removal and minimizes trauma to surrounding tissues. In contrast, Renuvion, also known as J-Plasma, utilizes helium plasma to tighten loose skin and stimulate collagen production. By combining these two technologies, patients can achieve a harmonious and youthful neck and jawline contour. This abstract discusses the procedural technique, patient selection criteria, and potential benefits of the VASER Liposuction and Renuvion combination for double chin treatment. Notably, the procedure can be performed under local anesthesia, reducing patient discomfort and downtime. Early clinical outcomes suggest significant fat reduction, improved skin elasticity, and a high degree of patient satisfaction. The synergistic effects of VASER Liposuction and Renuvion represent a promising advancement in facial aesthetics, offering a minimally invasive solution for patients seeking to address their double chin concerns. Further research and long-term follow-up studies are necessary to comprehensively assess the safety and efficacy of this approach.

15:45 - 16:00 **Q & A / Break**

Session 12

Chairperson: Harb Al Omari MD, Nemat Alsaghir MD

16:00 - 16:15

The Role of Platelet Rich Plasma in Face Contouring & Jaw-line Definition

Noura Lebbar MD | Cosmetic Surgeon

The platelet rich plasma is one of the most efficient therapies in regenerative medicine in the last 10 years. the new trend in aesthetic medicine is the conservative treatments avoiding the pillow face effect. let's discuss how we can use the effects of regenerative Platelets rich plasma in face volume restoration

In order to avoid overfilling the face with hyaluronic acid, I use platelet rich plasma to improve the face conturing, to define the jawline to restore the face volume. I use a platelet rich plasma gel with a concentration of 10% mixing it with platelet rich plasma containing sodium citrate, I inject it deeply on the periosteum on the mandibular angle, and then with a 22 g cannula along the mandibular branch. I repeat the session after 1 month, the result is very natural because we have a natural and progressive improvement of the jawline definition avoiding any unnatural effect that gives the injection of the huge quantity of fillers.

DAY THREE THURSDAY

7th March 2024

CONFERENCE HALL 3

COSMETIC & SURGICAL DERMATOLOGY

16:15 - 16:30

Laser Assisted Drug Delivery

Ahmed Sami Abouroab MD | Specialist Dermatologist

Topical therapy is an expanding field not only in dermatology but also in other fields of medicine However, transdermal drug has LIMITATIONS e.g. 1. Skin's barrier minimizing absorption of topically applied medications to only 1–5%. 2. Poor penetration of topical agents in areas like nails. 3. Bioavailability of most topically applied drugs is relatively low. 4. Not suitable for large molecular size & hydrophilic drugs.

With topical therapy, the stratum corneum barrier of skin impairs the ability of drugs to enter body. The purpose of LADD is to alter the stratum corneum, epidermis, and dermis facilitate penetration of drug to its respected target. LADD employs three steps: 1-Breakdown of skin barrier with a laser 2-Delivery of drug through laser channels to enhance the therapeutic effect. 3-Optional use a laser for a therapeutic effect.

16:30 - 16:45

Eye Thread Lifter

Dalia Ata MD | Dermatologist & cosmetologist

Aging skin around the eye has different signs like fine line wrinkle thin skin pigmentation tear trough eye bag and causes of aging skin genetic sun exposure disease under eye and lifestyle treatment option according including mesotherapy, prp ,microneedle, co2 laser and recently pdo threads.

PDO Thread is absorbable material. inserted around eye under local anaesthesia. its absorbed and increase collagen production. improve skin wrinkle pigmentation and texture.

16:45 - 17:00

Correction Of the Marionette Lines in The Face with The Combined Usage of Thread Methods and Fat Grafting

Irada Huseynova MD | Plastic Surgeon

Marionette lines, are one of the consequences of facial aging. The curvilinear wrinkles formed because of facial movements and the aging process extend downward from the oral commissures.

For the correction of wrinkles in marionettes, a complex correction method was proposed using Aptos spring threads in combination with lipofilling.

The first phase of correction included the use lipofilling. Fat grafts exhibit not only dermal filler properties but also regenerative potential owing to the presence of stem cells in fat tissue. The Nano spring 7 threads were used at the second stage of the correction.

The agreement between the experts was defiantly high. Bubble plots (bivariate scatter plots) demonstrated linearity in judgment by the experts.

The usage of fat grafting, at the first stage of correction, followed by the use of nano-spring absorbable threads from a copolymer of L-lactide with e-caprolactone. We can observe the following advantages of this method:

DAY THREE THURSDAY

7th March 2024

CONFERENCE HALL 3

COSMETIC & SURGICAL DERMATOLOGY

1. performance under local anesthesia
2. visible clinical effect
3. short time of rehabilitation
4. minimal risk of complications

Leading to a pronounced external effect of correcting drooping corners of the mouth

This method also leads to improved quality and therapeutic skin lifting.

17:00 - 17:15

Perfecting the Patient Journey

Nisha Menon MD | Aesthetic Doctor

With more and more patients seeking aesthetic treatments, it's extremely important to ensure that we have a 360 degree approach to our consultation process to understand the patients needs and to be able to offer them the best solution for their concern. Medical Aesthetics have grown over the past decade and there are a lot more we can offer to our patients to ensure they have long lasting results. This can only be approached by a through consultation process and educating the patient on the various modalities that can be combined to deliver exceptional results. The consultation is a opportunity to find out why the patient has thought about having a particular treatment and the motivating factor to seek aesthetic treatments. Understanding the patients background, goals and expectation will help us as practitioners create a better outcome for the patient. The consultation process keeps evolving as we gain more experience as practitioners, a typical consultation in my practice lasts approximately 45mins to an hour. After going through a thorough medical and social history, I also perform a digital skin analysis to further understand the skin and it's current condition.

The consultation can open up various emotional and psychological aspects of the patient, the initial thought of seeking an aesthetic treatment eg: divorce, marriage, menopause or the ageing process. Following the consultation, it is vital to demonstrate to the patient how each treatment or procedure will improve any of the concerns that was mentioned during the initial consultation and the expected outcome including any downtime that they should be aware of. Patient education is extremely important and this will allow the patient to make an informed decision and also project your expertise and knowledge.

17:15 - 17:30

Adipose Stem Cell Exosome (ASCE): Next Generation Regenerative Therapeutics for Atopic Dermatitis

Byongseong Cho MD | CEO and CTO

Exosomes, nano-sized extracellular vesicles, are the most important mediator for intercellular communication. For last years, the dual function of skin regeneration and anti-inflammation of ASCE (Adipose Stem Cell Exosome) has been well known from a number of research. These days, ASCEs are being developed as next generation regenerative therapeutics and aesthetics as well. From our various studies, it has been shown that ASCE can be an innovative biomaterial as regenerative therapeutics as well as regenerative aesthetics for treatment of atopic dermatitis & skin rejuvenation.

DAY THREE THURSDAY

7th March 2024

CONFERENCE HALL 3

COSMETIC & SURGICAL DERMATOLOGY

Materials / method: Human adipose mesenchymal stem cell-derived exosomes (ASCE) were applied via SC or ID injection to in vitro cell models & in vivo animal models. In addition, one patient of atopic dermatitis was applied topically with ASCE in combination with iontophoresis. Results: 1. ASCE could reduce or modulate over-reactive inflammation in the skin in the atopic dermatitis model. The AD score was significantly improved by up to 30% in a dose-dependent manner. Further, major proinflammatory cytokines including IL-4, IL-13, TLSP, & others were down-regulated by up to 30-50% in a dose-dependent manner. 2. ASCE could promote, by 40-70% in a dose-dependent manner, the de novo synthesis of ceramides and dihydroceramides, key lipid molecules in skin barrier formation, which led to the significant improvement of the skin barrier disruption model.

17:30 - 17:45

A Systematic Investigation of The Importance of PH Regulation in Skin Through Varied Interventional Procedures

Ahmad Nazari MD | Aesthetic Trainer

Skin pH regulation is critical for various functions and dermatological symptoms. This study evaluates six procedures: Microneedling, PRP, Collagen Boosters, RF Fractional, Carboxytherapy, and HIFU Therapy on skin pH normalization

A study with sixty participants assessed six skin treatments (Microneedling, PRP, Collagen Boosters, RF Fractional, Carboxytherapy, and HIFU Therapy) on pH normalization. Skin pH was measured before and after the nine-month intervention using a Skin pH Meter. Microneedling, PRP, and RF Fractional significantly improved skin pH ($p<0.05$), enhancing cellular activity and the skin microbiome. Other treatments also improved pH but with less statistical significance. This study advances our understanding of skin pH regulation and treatment efficacy, highlighting their importance. Further research is needed for conclusive results.

17:45 – 18:00

Five-point Liquid Rhinoplasty: Results from A Retrospective Analysis of a Novel Standardized Technique and Considerations on Safety

Leonard Nenad Josipovic MD | Aesthetic and Cosmetic Surgeon

The use of minimally invasive aesthetic procedures continues to in- crease across the world—including in Germany.1,2 This trend is driven primarily by the growing popularity of injectable hyaluronic acid (HA) fillers and botulinum neurotoxin type A formulations. However, the nose remains an area of the face that is often considered to be more amenable to surgery rather than nonsurgical approaches. Indeed, an estimate from the International Society of Aesthetic Plastic Surgery suggested that the number of surgical rhinoplasties performed across the world increased by 13% in 2019 relative to 2018.1 The advent of novel HA fillers with greater cohesivity and in- creased elastic modulus (G') may shift the balance toward nonsur- gical approaches. These enhanced rheological properties are crucial for reducing product spread following injection into the nose— where high skin tension over prominent bone and cartilage can lead to significant compressive forces (and thus loss of projection when using less cohesive products).3 With these novel fillers, effective nonsurgical rhinoplasty could be more feasible for more patients. Effective, minimally invasive treatment of the nose with inject- ables may offer a number of important advantages over surgical ap- proaches, including reduced patient downtime, removal of the need for

DAY THREE THURSDAY

7th March 2024

CONFERENCE HALL 3

COSMETIC & SURGICAL DERMATOLOGY

anesthesia, lower complication rates, high levels of reversibility (using hyaluronidase), and decreased upfront costs for the patient.4–6 Nonetheless, not all defects of the nose can be addressed using HA fillers. Appropriate patient selection remains crucial. In addition, there are important safety concerns when injecting this area, includ- ing rare but potentially life-changing complications, such as tissue necrosis or blindness caused by accidental intra-arterial injection of filler.7,8 Greater systematization of the approach to treatment may be important not only for minimizing the risk of such complications, but also for improving the reproducibility of results—thereby helping to optimize patient satisfaction. We have developed a standardized "five-point liquid rhinoplasty" aimed at safe treatment of the most relevant aesthetic areas using HA fillers that have high G′ (and ideally also high cohesivity). Most importantly, this method focuses injections along the midline and into deep anatomical layers where the risk of vascular compromise may be lowest.9–12 The objective of the present work was to assess

Abstract Background: Nonsurgical aesthetic improvement of the nose with hyaluronic acid (HA) fillers is becoming increasingly popular but comes with important safety considerations. Aims: To assess the safety and effectiveness of the standardized "five-point liquid rhinoplasty" approach. Methods: This was a retrospective, single-center analysis of consecutive adult pa- tients undergoing nonsurgical aesthetic treatment of the nose. All had one of the three main indications (insufficient nasal projection, nasal hump, or deep glabella) and were injected using HA fillers with high elastic modulus. Treatments were given using some or all of the injection points of the "five-point liquid rhinoplasty" technique: P1 (nasal tip, 0.2–0.3 ml supracartilaginous); P2 (nasal root, 0.1–0.2 ml supraperiostal); P3 (cartilaginous dorsum, 0.1–0.2 ml supracartilaginous/supraperiostal); P4 (subnasal, 0.1–0.2 ml supraperiostal); and P5 (nasal alar, 0.1–0.2 ml per side supraperiostal). The risk of complications was minimized by injecting deep and staying in the midline as far as possible. Results: Twenty patients were enrolled (n = 15 female [75%]; mean age: 37.8 ± 11.7 years). The mean volume of filler used was 0.66 ± 0.35 ml per patient. Nineteen subjects (95%) said they were "very satisfied" with results, and the physician was also "very satisfied" with outcomes in 19 patients (95%). Two individuals experi- enced hematoma, which was managed conservatively; there were no other significant complications. Conclusions: The "five-point liquid rhinoplasty" is a simple and effective method de- signed to maximize safety. It offers a good alternative to surgery in selected patients. KEYWORDS filler, hyaluronic acid, liquid rhinoplasty, nonsurgical rhinoplasty, Vycross.

DAY THREE THURSDAY

7th March 2024

CONFERENCE HALL 4

ASSOCIATION PROGRAM

Session 11: Bahrain Dermatology Association Session

Chairperson: Zainab Almossali MD

08:30 - 08:45

Patch testing in Cutaneous Adverse Drug Reactions: Methodology, Interpretation, and Clinical Relevance in a Nutshell

Zainab Almossalli MD | Dermatology Consultant

A. Drug patch testing has been proposed as a helpful investigating tool upon suspecting drug allergy. In this lecture we will review the value and available evidence of patch testing in sever cutaneous drug eruptions.

B. Allergy is an abnormal reaction of the body to a previously encountered allergen introduced by inhalation, ingestion, injection, or skin contact. As a dermatologist we treat a lot of patients that complain of having an "allergy" so understanding how to approach such patients is important.

08:45 - 09:00

Lessons learnt from Case Reports

Fatema Khamdan MD | Assistant Professor, Consultant Dermatologist and Dermatopathologist

Case reports are valuable resources of unusual information that may lead to new research and advances in clinical practice. Many journals and medical databases recognize the time-honored importance of case reports as a valuable source of new ideas and information in clinical medicine.

Therefore, a case-based discussion will be held by extracting the most important key points from the best articles and challenging cases published in the most reliable journals such as JAAD, JAMA, etc.…

a case-based discussion of the most important, interesting and informative case reports published in the most reliable journals highlighting important diagnostic tips and pitfalls in such cases. In addition, new and updated guidelines will be discussed and new options of treatment will be discussed.

09:00 - 09:15

Food and Aeroallergens Testing: What Dermatologist Need/Don't Need to Know!

Zainab Almossalli MD | Dermatology Consultant

A. There is overwhelming evidence that many delayed cutaneous adverse drug reactions (beginning >6 hours after drug intake) are mediated by delayed-type (type IV) hypersensitivity.

Therefore, after resolution of the reaction, patch tests should be performed as first diagnostic method to identify the culprit drug(s). This presentation provides tools to perform drug patch tests properly and safely, discussing clinical history, indications, and procedure.

B. As a dermatologist, understanding how to diagnose and approach patient with food and aeroallergens allergy complains is important. In this presentation we will review the immediate type hypersensitivity, how to approach a patient with suspected allergy and finally a summery on when and how to interrupt Food and aeroallergen testing.

DAY THREE THURSDAY

7th March 2024

CONFERENCE HALL 4

ASSOCIATION PROGRAM

09:15 - 09:30

Treatment Options for Pregnant Women Living with Severe Skin Conditions Case Based Discussion

Fatema Khamdan MD | Assistant Professor, Consultant Dermatologist and Dermatopathologist

Information about the safety of most medications in pregnant women or their infants is often limited. In addition, clinical guidelines in treating severe skin conditions during pregnancy is lacking. Therefore, dermatologist is facing a real challenge in dealing with pregnant women suffering from severe skin conditions requiring systemic treatment.

We discuss the current approaches to treat common skin conditions including inflammatory/ infectious cases that require intervention and treatment by dermatologist optimizing pregnancy outcomes and minimizing risks to both mother and fetus.

This is a case-based discussion that will give updated guidance regarding the management of pregnant lady with severe skin conditions such as psoriasis and atopic dermatitis. We will ensure adequate discussion of treatment approaches by highlighting the safest drug options and precautions while dealing inflammatory/ infectious skin dermatosis during pregnancy.

Session 12: Syrian Arab Society of Dermatology Session

Chairperson: Samir Almahfoud MD, Fouz Hassan MD

09:30 – 09:50

Using Botox as an Adjunct in the Treatment for Migraine

Samir Almahfoud MD | Consultant Dermatologist and president of the Syrian Arab Society of Dermatology
Diana Sarkis MD | Resident Dermatologist

The presentation focused on:

What is botox?

Botox research.

The migraine story and how does the botox stops migraine

Migraine botox techniques

The side effects

09:50 – 10:10

Complication of Permanent Fillers, Classification and Management

Wael Albarazi MD | Head of the Plastic, Reconstructive and Burns Department

Applying fillers in aesthetic medicine is very widely used for many indications. While applying permanent filler is absolutely refused , but unfortunately many doctors around the world still apply it . Permanent filler is composed of polyacrilimide which is the basic material in plastic industries . I will introduce many dangerous cases how is the approach and how is the management. Permanent fillers are not allowed to be used anymore all around the world.

DAY THREE THURSDAY

7th March 2024

CONFERENCE HALL 4

ASSOCIATION PROGRAM

10:10 – 10:25

Cotton with Alcohol as a Diagnostic and Therapeutic Tool: 12 Cases of Neglecta Dermatitis and Terra Firma form TFFD with this Easy Cheap Tool

Thaer Douri MD | Dermatologist and a Lecturer at the Faculty of Medicine Neglecta dermatosis(N D) is Acquired, long-standing, nonsymptomatic, dark, verrucous plaques of dirt simulating verrucous nevi . It first described in 1995 by Poskitt et al who proposed that it develops as a result of a patient's willful or subconscious self-neglect Terra firma forme dermatosis (TFFD) has also been used to describe a condition with similar clinical features but which is not amenable to soap and water cleansing and can only be rubbed off with vigorous alcohol swabbing .

In these series cases we diagnosed and treated these cases only with Cotton with alcohol , it is effective in most cases. For more resistant and verrucous lesions, application of a keratolytic may be required. Ketoconazole another treatment against Malassezia . The result of treatment usually surprises patients..

10:25 – 10:45

LASER: Summaries and Updates

Wahiba Suliman MD | Member of the Administrative Board

A presentation on the basics of LASER in dermatology and its efficacy measures. The presentation highlights several updates and key points such as LASER use in pregnancy and lactation, tattoo removal and resurfacing follow isotretinoin therapy. It also points out the benefits of LASER in some inflammatory conditions.

10:45 – 11:00 Q & A / Break

11:00 - 11:15

Critical Cases of Leishmaniasis

Muhammad Rabie Katta MD | Vice President
Julnar Hanna MD | Dermatologist

There are many cases of leishmaniasis that we review that do not apply to any of the rules of leishmaniasis found in the world health organization's guide. The most important difficulties facing us are the issue of age, position, and accompanying internal diseases in the patient, here we resort to the approach, experience and long patience to follow up the patient's condition until recovery and balance in choosing the treatment method between, side effect of the drug and the desired benefits from it .

11:15 - 11:30

Up-to-date in Prurigo Nodularis

Lina Al Soufi MD | Head of Department of Dermatology

Prurigo nodularis is a chronic inflammatory skin disease characterized by intesly pruritic hyperkeratotic nodules on the extensor surfaces of the ectremities and the trunk. The pathogenesis is multifactorial. I will focus in my presentation on some important points in clinical practice about PN,serious comorbidities,available &new treatment.

DAY THREE THURSDAY

7th March 2024

CONFERENCE HALL 4

ASSOCIATION PROGRAM

11:30 - 11:45

Clinical Cases

Fouz Hassan MD | Head of the Department of Dermatology and Venereology

in this presentation we will present our experience in the treatment of Psoriasis with ustekinumab. And we will present a special case of Kaposi's sarcoma in an HIV-negative Acute lymphocytic leukemia patient.

11:45 - 12:00

Clinical Cases

Sdrah Diab MD | Dermatology Resident

Rupioid psoriasis is a distinguished subtype of psoriasis, uncommon in the pediatric population, and indicates poor treatment compliance. Rupioid lesions are oyster shell-resembling lesions. Ustekinumab is an IgG monoclonal antibody that targets IL-12, and IL-23 and subsequently decreases the release of proinflammatory cytokines TNFα, IL-2, and IL-17α that play a vital role in psoriasis pathophysiology. Ustekinumab was approved to treat pediatric patients aged ≥ 6 years.

Abstract Summary: (Maximum of 100 words)

A 10-year-old girl with rupioid psoriasis since age two, exaggerated after a urinary tract infection. We addressed the infection with oral cefixime 200 mg. and decided to treat her with a Ustekinumab 45 mg. subcutaneous injection. Lesions improved after treating the Urinary tract infection. Ustekinumab was administrated after performing the required tests for the drug and showed significant improvement.

12:00 - 12:15

Case Studies in Practice: Insights from Tishreen University Hospital

Dyala Lutfi Sayed Ahmad MD | Dermatology Resident

Kaposi sarcoma is a low-grade mesenchymal angioproliferative disorder that requires infection with human herpes virus 8 for it to develop. It is commonly seen in HIV-positive patients and rarely in immunosuppressed HIV-negative patients. It is classified into four clinicopathological subtypes based on the clinical condition in which it develops: (1) the classic or sporadic form mostly occurs in lower extremities in elderly patients of Mediterranean or Jewish origin, (2) the endemic form is prevalent in middle-aged adults and children from sub-Saharan Africa, (3) the human immunodeficiency virus (4) the iatrogenic form of KS, which is associated with immunosuppressive therapies for transplants or malignancies and other chronic inflammatory diseases.

The iatrogenic variant of KS occurs in patients who are immune-suppressed following organ transplant (particularly kidney transplants), chemotherapy, or rheumatologic disease , usually appearing a year after the first administration of the drugs.

Herein we report a case of KS in a 33-year-old man, who presented with KS lesions on his feet following acute lymphoblastic leukemia ALL.

DAY THREE THURSDAY

7th March 2024

CONFERENCE HALL 4

ASSOCIATION PROGRAM

Session 13: Sudanese Association of Dermatologist (SAD) Session

Chairperson: Bakri Al Agraa MD

12:15 - 12:40

Clinical Picture of Vitiligo in Children

Mahdi Shamad MD | Associate Professor and Dean

Vitiligo is a progressive disfiguring condition that causes loss of skin pigment. Quite a lot of researches have been done concerning vitiligo and its clinical features, but not many have been done in children.

The objective of this study was to identify the clinical pattern of Vitiligo in children.

The available literature will be revised, and results will be presented in .

Smedtrum
Be the Sparkling Miracle!

FDA 510 (k) Cleared

ISO 13485:2016

Taiwan Made

Manufacturer of Aesthetic Medical Device from Taiwan!

High Intensity Focused Ultrasound System (HIFU)

- **Matrix Output:** Maximum 10 lines within the treatment area

Smedtrum™ HIFU		Other HIFU
1 shot = **10 lines**	VS.	1 shot = **1 line**

- ***Key Treatments***
  - *Lifting the eyebrow*
  - *Lifting lax submental and neck tissue*
  - *Improving lines and wrinkles of the decollete axillary*
  - *Hyperhidrosis surgery*

Picosecond Laser System

- **Honeycomb Focused Technology** for Skin Rejuvenation

- ***Key Treatments***
  - *Tattoos Removal*
  - *Nevus of Ota*
  - *Speckled Nevus*
  - *Seborrheic Keratosis*
  - *Lentigo*
  - *Café'-au-lait Macule*

www.smedtrum.com smt@smedtrum.com +886 2 2298 9578

Contact Us!

Poster **Presenters**

Dermatology Core Curriculum in Medical School and Its Association in The Selection of Dermatology as A Future Career: A Nationwide Cross-sectional Study

Norah Albdaya MD

Clinical Diagnosis of Kindler Syndrome: A report of two cases from a district hospital in Gujranwala, Pakistan

Nabeela Shehzadi MD

A study on the blood mRNA expression of inflammatory cytokines in Atopic dermatitis

Fida Anjum MD

OTC medication menace causing cutaneous necrosis - A Dermatologists nightmare

Kakollu Sravani MD

Hypohidrotic Ectodermal Dysplasia with Localized Dystrophic Epidermolysis Bullosa; A case report

Sania Butt MD

Co-localisation of porokeratosis and lichen planus along Type A blaschko line along with interesting histological findings

NANDHINI B MD

---

familial oral lichen planus with HLA association

Fatma Al Hosni MD

ONYCHOSCOPY AS A TOOL IN DIAGNOSIS OF TWENTY NAIL DYSTROPHY - A CASE REPORT

T U POOJA MD

Knowledge, beliefs and perceptions among alopecia areata patients: A cross-sectional study in Faisalabad

Ayesha Abrar MD

ARTERIO VENOUS MALFORMATION OF THE EAR IN AN ADOLESCENT GIRL MIMICKING AURICULAR SEROMA

Tippireddy Susritha MD

Poster **Presenters**

Collagen stimulation- what could really be achieved

Fariyal Elahi MD

Duelling With Two Wolves : Clinico - pathological and dermoscopic differences between Discoid LE and Tumid LE

Sanjanaa Srinivasa MD

An Unusual Presentation of Bullous Pemphigoid: A Toxic Epidermal Necrolysis Variant

Viola Elvia Sequeira MD

Comparison of Efficacy and Safety of Biogenetically engineered Exosomes versus Platelet Rich Plasma in Patients of Androgenetic Alopecia: A Randomized Control Trial

Alina Abbass MD

Cross Sectional Study Analysing Cutaneous Manifestations of Obesity in Patients Attending the Dermatology Clinic at T.h Karapitiya

Apeksha Shyamalie Dissanayake Perera MD

Revolutionizing the Management of Physiological Striae in Teenage Girls: Efficacy of Platelet-Rich Plasma Therapy

Chiranjaya Ekanayake MD

A Cross-sectional Study of The Knowledge, Practice, and Attitude Towards Herpes Zoster Vaccination Among the General Population in Riyadh, Saudi Arabia

Maha AlHussein

Dyschromatosis Universalis Hereditaria with skeletal genu valgum: A rare association

Sara Affara MD

Zinc-Responsive Acral Hyperkeratotic Dermatosis

Reem Hasan MD

Generalized basaloid follicular hamartoma syndrome mimicking nevi: an unexpected diagnosis

Hadir Shakshouk MD

Poster **Presenters**

A Case of Bullous Pemphigoid in a Five-month-old Female: A Rare Presentation
Fatma Alqaydi MD

Solitary Mastocytoma: The Battle of Differentials
Khalifa Bintarish MD

Uremic Pruritus in haemodialysis: Unravelling a disturbing symptom
Mohan V Bhojaraja MD

Efficacy of systemic retinoids in treating Hidradenitis Suppurativa: A systematic review and Meta-analysis
Layan Alsanad MD

Combined technique of Intralesional radio-frequency with intralesional corticosteroids in the management of keloidal scars
Nabeel Ahamed MD

Intense Pulse Light (IPL) Treatment for Grade 3 Acne: Efficacy and Tolerability Analysis
Anne Cinthia Ashwin MD

A Case Series on Klippel-Trenaunay Syndrome
Neena Reddy MD

Basal Cell Epithelioma in Older Patients - A Case Series
Abinaya Kuberan MD

Acne Papulo Rosacea of The Nose - A Case Series
Anandha Jhothi Murugaraj A

Dermatosis Caused Due To Ethnic Practices In India - Case Series
Nagapurapu Udaya MD

Poster **Presenters**

Mucocutaneous Pigmentation in ADDISON's Disease
Akhila Vaddadi MD

Childhood Sarcoidosis Presenting as Erythema Nodosum - A Rare Case Report
Brindha Jeyaraman MD

BIOSKIN

DERMOLIFECOSMETIC

PRE&POST PRODUCTS

BSK70
MELAN PRO
Whitening cream

50 mL

BSK71
C+E VITAMIN CREAM
Antiage cream with vitamin C+E

50 mL

BSK75
ANTI-WRINKLE CONCENTRATE SERUM
With organic silicon, Hyaluronic Acid and DMAE

30 mL

BSK76
TRANEX PRO SERUM
Depigmentant intensive serum

30 mL

BSK89
GLYCOLIC 20%
Glycolic peeling

50 mL / 300 mL

BSK90
CLEANSER FOAM
Soft cleanser foam

150 mL

BSK93
POST-MESO CREAM
After-treatment cream

50 mL / 300 mL

AESTHETIC PRODUCTS

BSK1
MULTIPEPTIDES
Bio-revitalization solution

5 Vial x 10 mL

BSK2
FIRMPRO
Firming Solution

5 Vial x 10 mL

BSK31
LIPS SHINE PRO
Lips treatment for wrinkles and volume

5 Vial x 5 mL

BSK32
EYE PRO CONTOUR
Reduces eye bags, dark circles & expression wrinkles

2 Vial x 3 mL

BSK33
HYALURONIDASE PRO
Lyophilized powder with 1500 UI

1 Lyophilized Vial

BSK15
NATURAL EXTRACTS
Reducing natural solution

10 Amp. x 5 mL

BSK17
DMAE 3%
Firming solution

10 Amp. x 5 mL

BSK20
MELILOTO + RUTINA
Drainage skin solution

10 Amp. x 5 mL

PEELINGS

BSK80
PEELPRO COCKTAIL HARD
Chemical abrasion mask

50 mL

BSK81
PEELPRO COCKTAIL MEDIUM
Chemical abrasion mask

50 mL

BSK82
PEELPRO COCKTAIL SOFT
Chemical abrasion mask

50 mL

BSK83
PEELPRO WHITE
Chemical abrasion mask

50 mL

BSK87
PEELPRO BRIGHTENING
Chemical abrasion mask

50 mL

BSK88
PEELPRO NEUTRALIZING LOTION
Neutralizing lotion

50 mL

KITS

BSK200
MELAN PRO DEPIGMENTING
Professional Kit

BSK104 | Melanpro Cream | 30 mL
BSK105 | Melanpro Mask | 50 mL
BSK84 | Peelpro Inwhitening | 30 mL
BSK88 | Peelpro Neutralizing Wipes x3

BSK204
INTIM WHITENING PRO KIT
Professional Kit

BSK84 | Peelpro Inwhitening | 30 mL
BSK34 | Intim Whitening pro | 3 x 10 mL
BSK94 | Intim Whitening Cream | 50 mL

BSK701
HYDRA KIT
Home Care Kit

BSK89 | Glycolic Gel 20% | 50 mL
BSK74 | Multivitamin Serum | 30 mL
BSK71 | C+E Vitamin Gel Cream | 50 mL

BSK705
EYE-CONTOUR KIT
Home Care Kit

BSK75 | Anti-Wrinkle Concentrate Serum | 30 mL
BSK95 | Eye-Contour | 15 mL
BSK73 | DMAE + HA Cream | 50 mL

BSK800
PEELING KIT
Professional Kit

BSK80 | Peelpro Cocktail Hard | 50 mL
BSK81 | Peelpro Coktail Medium | 50 mL
BSK82 | Peelpro Cocktail Soft | 50 mL
BSK87 | Peelpro Brightening | 50 mL
BSK88 | Peelpro Neutralizing Lotion | 50 mL

www.bioskincosmetic.com

Download the Mobile App NOW

To Get Everything You Need to know About Dubai Derma At Your Fingertips

Download on the App Store

GET IT ON Google Play

EXPLORE IT ON AppGallery

#DubaiDerma

dubaiderma.com

Organized by

Supported by

Hydrafacial®

Get the Best Skin of Your Life

One Device, Endless Possibilities

Booth 7D08
Hall Passy 7


Hello Tomorrow
Emirates
Find your
work-life groove
From laid back to more upbeat, you'll find a range of inspirations in our Business Class. Savour gourmet cuisine, laugh through the latest comedies or socialise in the Onboard Lounge. Get in tune with the business of living.
emirates.com

SAVE THE DATE

Dubai Derma®

Skin Health is our Concern

24th Dubai World Dermatology and Laser Conference & Exhibition

Shaping the Future of Dermatology & Aesthetics

14 – 16 APRIL 2025

Dubai World Trade Centre

Organized by

Supported by

#DubaiDerma

dubaiderma.com

ACKNOWLEGEMENT

The Scientific Organising Committee of the Dubai World Dermatology and Laser Conference & Exhibition would like to express their gratitude to all Speakers, Participants, Sponsors, Partners and to all those who contributed to the success of the meeting.